



A method for treating patients with elbow joint contractures using hydraulic mobilization

Yu.P. Soldatov✉, A.A. Al Sameai, N.E. Ovchinnikov

Ilizarov National Medical Research Centre for Traumatology and Orthopedics, Kurgan, Russian Federation

Corresponding author: Yuri P. Soldatov, soldatov-up@mail.ru

Abstract

Introduction Restricted elbow function following injury and disease results in pathophysiological changes in the muscles, tendons, joint capsule, and cartilage. Intra-articular fibrous adhesions and arthrofibrosis with collagen deposition and synovial hypertrophy develop. It aggravates the contracture and complicates treatment.

The **purpose** of the work was to present a new method of treating patients with elbow joint contractures using hydraulic mobilization that eliminates bone conflict during flexion-extension movements.

Materials and Methods To improve the effectiveness of treatment for patients with flexion and flexion-extension contractures of the elbow joint without bony conflicts during articular surface movements, a method of hydraulic mobilization was developed (Invention Application No. 2025131920 dated November 14, 2025). The method includes sequential hydraulic lavage, hydraulic mobilization of the dorsal and ventral sections of the elbow joint, medication administration, and staged plaster casting. This method was used to treat a 63-year-old patient with post-traumatic contracture and osteoarthritis of the right elbow joint. Elbow flexion was 40°, extension 90°. At short- and long-term (one year) follow-ups after surgery, the patient's quality of life significantly improved: self-service was full, pain was absent, and elbow movements were restored.

Discussion Methods for administering fluids under pressure for joint dilation in shoulder and knee pathologies, arthroscopic debridement with continuous passive motion and intra-articular analgesic infusion, and hydraulic lavage of the elbow joint for osteoarthritis are known. However, continuous passive motion can lead to soft tissue trauma and microtears of muscle fibers, resulting in pain and secondary contracture. The developed method has advantages: it allows for the separation of fibrous adhesions thereby the effectiveness of treatment depends on the consistent performance of surgical and postoperative procedures to prevent contracture recurrence

Conclusion The proposed method of hydraulic mobilization for treatment of patients with elbow joint contractures caused by fibrotic changes in the tissues is a low traumatic, minimally invasive surgical intervention that improves the effectiveness of restoring joint function when the indications for its use are met.

Keywords: elbow joint, contracture, hydraulic lavage, hydraulic mobilization, arthrofibrosis, hydrodilation

For citation: Soldatov YuP, Al Sameai AA, Ovchinnikov NE. A method for treating patients with elbow joint contractures using hydraulic mobilization. *Genij Ortopedii*. 2026;32(3):412-418. doi: 10.18019/1028-4427-2026-32-3-412-418.

INTRODUCTION

Restricted elbow function following injury and disease leads to pathophysiological changes in the muscles, tendons, joint capsule, and cartilage. Intra-articular fibrous adhesions and arthrofibrosis develop associated with collagen deposition and synovial hypertrophy, which are difficult to treat [1–5].

In patients with elbow joint contractures without bony impediments to joint surface movement, open (including arthroscopic) and closed (elbow joint mobilization with the Ilizarov apparatus through a gradual increase in range of motion) arthrolysis are used. However, arthroscopy requires additional surgical approaches and specialized equipment. Moreover, injuries to the surrounding tissue and complications inherent to open surgical techniques may occur [6–8].

A method for joint mobilization under general anesthesia is known [9]. In Russian guidelines, this method is known as joint redressal. It is not always accepted by surgeons due to its traumatic nature and high incidence of iatrogenic complications (hemarthrosis, cartilage and ligament damage) [9]. The procedure results in secondary trauma, which causes proliferation of the extracellular matrix and proinflammatory mediators. Immune system memory and feedback may contribute to further stimulation of fibrotic changes in response to surgery, which frequently results in disease recurrence [10].

For extended mobilization of the capsular-ligamentous complex and treatment of patients with osteoarthritis, surgeons use prolonged lavage of the elbow joint [11], hydraulic mobilization (foreign sources use the terms "hydrodilation" and "hydrodistension"), hydrodilation novocaine blockade [12], hydrodilation redressal [13], and subchondral perforation of the metadiaphyses of the joint bones [14]. These procedures inhibit adhesions, do not interfere with early joint exercises, and improve the results of medical rehabilitation. However, despite treatment, pain is not always relieved, and functional limitations may persist [15, 16].

The **purpose** of the work was to present a new method of treating patients with elbow joint contractures using hydraulic mobilization that eliminates bone conflicts during flexion–extension movements.

MATERIALS AND METHODS

To improve the effectiveness of treatment in patients with flexion and flexion-extension contractures of the elbow joint without bone conflicts during movements of the articular surfaces, a method of hydraulic mobilization has been developed (application for invention No. 2025131920 dated November 14, 2025).

The instruments and medications required to perform the technique are: two 2-mm needles for punctures and 200 ml of saline solution.

Under general or local anesthesia, with the elbow joint in the maximum extension, a puncture is performed on the ventral (humeroradial joint area) and dorsal (olecranon fossa area) portions of the elbow joint (Fig. 1 a). Under pressure on the syringe plunger, hydraulic lavage of the elbow joint is performed by gradually injecting 20–40 ml of saline solution (first into the ventral portion of the elbow joint, then into the dorsal portion) and draining it through a second needle.

The needle is then removed from the olecranon fossa, and, again in the position of maximum possible extension, saline is injected into the anterior part of the joint under pressure from the syringe until it is filled to capacity (up to 10 ml) (Fig. 1 b). Next, the needle is removed from the ventral elbow joint and with the joint filled with saline, the forearm is flexed as much as possible and held under force for five minutes. The needle is then reinserted into the olecranon fossa. The forearm remains flexed (Fig. 1 c).

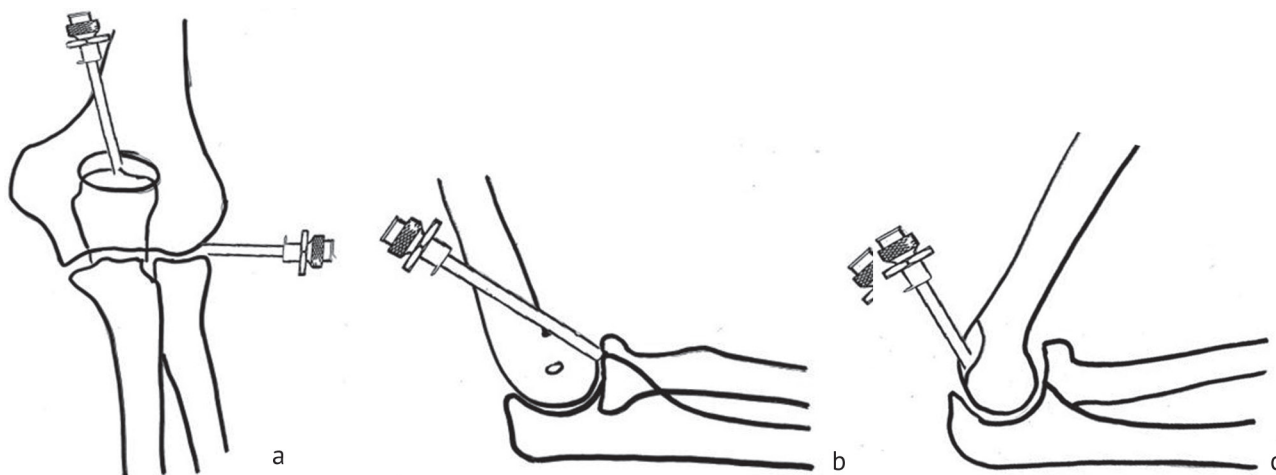


Fig. 1 Diagrams of the elbow joint with the location of puncture needles and forearm positioning: (a) lavage of the elbow joint at the first stage; (b) hydraulic mobilization of the ventral part of the elbow joint at the second stage; (c) hydraulic mobilization of the dorsal part of the elbow joint

Using pressure from the syringe, up to 10 ml of saline solution is injected until the joint is completely filled. The needle is then removed, and the elbow joint is gradually extended with the surgeon's hand and held in this position under force for five minutes. Aseptic dressings are applied to the skin at the puncture sites. The arm is immobilized in the maximum possible extension with an anterior plaster cast.

The sequence of hydraulic mobilization of the elbow joint with maximum possible extension of the forearm relative the elbow joint:

- 1) puncture of the ventral and dorsal parts of the elbow joint with needles;
- 2) hydraulic lavage;
- 3) removal of the needle from the area of the olecranon fossa, injection of saline solution into the ventral part of the elbow joint through a puncture needle inserted into the humeroradial joint;
- 4) removal of the needle from the ventral part of the elbow joint;
- 5) forearm flexion, retention of the forearm in the maximum flexion for 5 minutes;
- 6) introduction of the needle in the dorsal part of the elbow joint, injection of saline;
- 7) removal of the needle from the dorsal part of the elbow joint;
- 8) forearm extension, retention of the forearm in the maximum extension for 5 minutes;
- 9) application of an anterior plaster splint.

For residual extension deficits in the postoperative period, Mydocalm is prescribed orally at dosage of 50 mg three times daily for 30 days. Every morning, the splint is removed, and joint flexion and extension exercises are performed using the patient's own muscle strength with rest periods of up to 20 minutes that are done for two months. The forearm is then extended at the elbow using weights (for one hour), and the splint re-immobilizes the joint in the maximum extension position. Every three days after joint exercises and arm extension, the cast is changed for a new one and the splint is reshaped to increase the extension angle to 10°.

Six patients aged from 40 to 50 years were treated with this method. Informed consent was obtained from the patients included in the trial for publication of the study results.

Case presentation

A 63-year-old patient presented with complains of a sharp decline in quality of life, limitations in self-care and physical work due to impaired extension of the right elbow joint and pain during extension under load. As a child, he sustained a fracture in the upper third of his right ulna and posterior subluxation of the radial head. The fracture healed in a plaster cast during one month. Extension was incomplete after fracture healing (extension deficit of 20°). As an adult, the patient noted constant physical strain on his right elbow joint (he worked as a driver and repaired trucks). The extension restrictions gradually worsened.

On admission, the right elbow joint was capable of flexion up to 40°, with maximum extension up to 90°. The diagnosis upon admission to the clinic was post-traumatic contracture and osteoarthritis of the right elbow joint. Radiographs revealed congruent articular surfaces, with narrowing of the joint space and bone overgrowths (Fig. 2). Complete blood count and urinalysis were within normal limits. Given the congruence of the articular surfaces and the absence of bony conflicts (mechanical impediments to articular surface movement), the patient underwent surgical treatment: hydraulic lavage, hydraulic mobilization of the right elbow joint, and fixation of the right upper limb with a detachable anterior plaster cast in the position of maximum possible elbow extension. Hydraulic mobilization was performed according to the developed method described above.

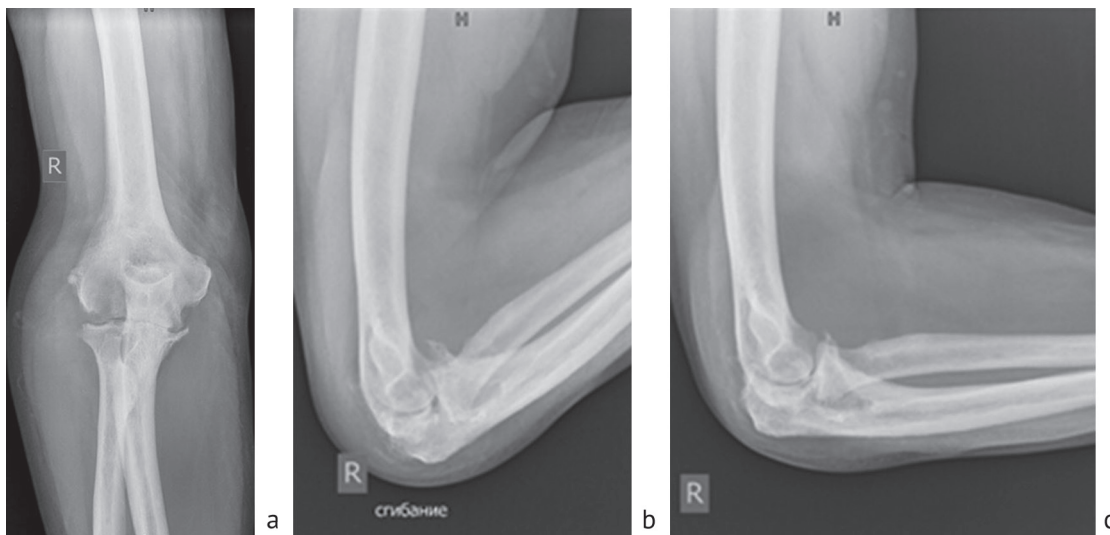


Fig. 2 Photo from radiographs of the patient's right elbow joint in direct (a) and lateral views with maximum flexion (b), lateral view with maximum possible extension (c) of the forearm before treatment

Postoperatively, Mydocalm was prescribed orally at a dose of 50 mg three times a day for 30 days. The splint was removed daily in the morning for two months, and joint flexion and extension exercises were performed using the patient's own muscle strength, with rest breaks of up to 20 minutes. The patient then passively extended the forearm at the elbow using weights (for one hour), and the limb was re-immobilized with the splint at maximum extension. Every three days after joint exercises and arm extension, a recasting was performed, with the splint being shaped to increase the extension angle by 10°. Three recastings were done. Full elbow extension was achieved; visually, the extension angle corresponded to 160° due to recurvatum deformity in the upper third of the ulna (Fig. 3). We plan to perform corrective osteotomy of the ulna to correct the deformity and closed reduction of the subluxation of the radial head in the future.

After discharge, the patient continued to do joint exercises once a day on an outpatient basis for two months; the limb was fixed with an anterior plaster splint in maximum extension.

In the immediate and long-term (one year) periods after treatment, the patient's quality of life significantly improved, self-care was complete, pain was absent, and movement in the elbow joint was restored (Fig. 3).

A ten-point scale was used for assessment: from 10 (negative characteristics) to 0 (favorable outcomes), 10 points – deficit in range of motion of 140°, 0 points – no deficit (Fig. 4).

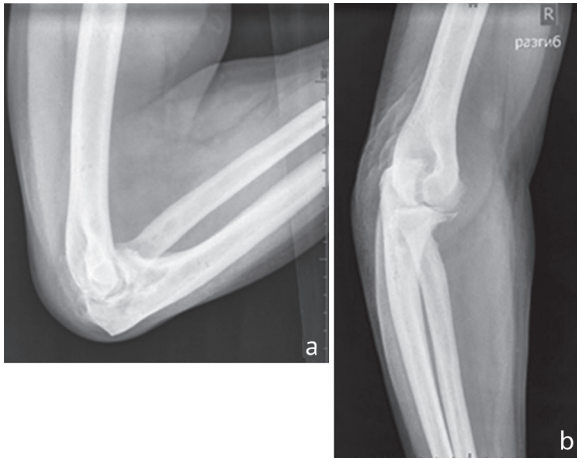


Fig. 3 Lateral X-rays of the patient's right elbow joint with maximum flexion (a) and maximum extension (b) of the forearm one year after surgery

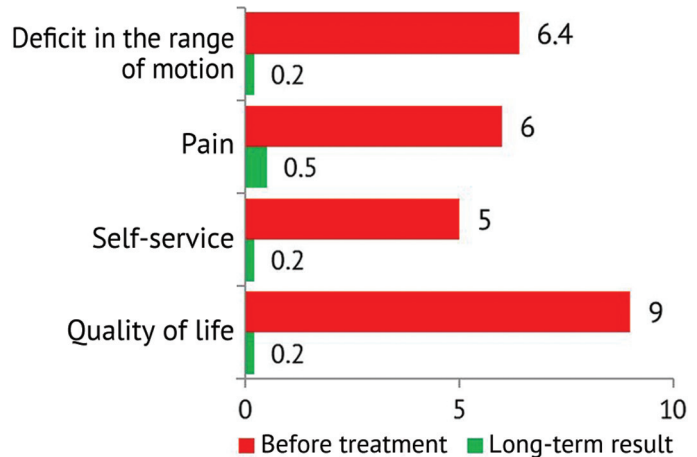


Fig. 4 Dynamics of quality of life indicators in a patient before surgery and at long-term follow-up

DISCUSSION

Fibrous adhesions and arthrofibrosis are frequent causes of post-traumatic contractures of the elbow joint without bony impediments to joint movement. Fibrous changes lead to the inability to perform professional and everyday tasks and a significant decline in quality of life [17]. Treatment strategies for such patients, as evidenced by literary sources [18], have not been fully developed.

According to the literature, the introduction of fluids under pressure for joint dilation in case of contractures is used mainly in case of shoulder joint pathology [9].

A known surgical treatment for knee arthrofibrosis involves arthroscopic debridement with continuous passive motion and intra-articular analgesic infusion [19]. However, continuous passive motion can lead to soft tissue trauma and microtears of muscle fibers, which causes pain and secondary joint contracture. This method is indicated for the treatment of the knee joint and is not used for the elbow joint.

The closest in technical essence is a method of hydraulic mobilization of the elbow joint for osteoarthritis, previously developed by the authors of this study. This method involved injecting 5 to 10 ml of saline solution into the anterior and posterior sections of the elbow joint until the joint was tightly filled, followed by flexion-extension motion exercise up to 10-15 times with moderate redress. This is followed by hydraulic lavage of the joint with 60 ml of saline solution [14]. However, the method does not involve the separation of fibrous adhesions and may be ineffective due to relapse of the disease caused by fibrosis of the joint capsule. The literature lacks information on the sequence of the operation or postoperative procedures to prevent contracture recurrence.

Studies aimed at investigating this problem may potentially provide new solutions that would complement surgical and physiotherapeutic methods to enhance the effectiveness of complex treatment [17]. They should provide a bigger sample size and extensive statistical analysis [20].

CONCLUSION

The proposed method for treating patients with elbow joint contractures using hydraulic mobilization improves elbow flexion and extension (in the absence of bony conflicts during articular surface movement) by dilating the joint cavity, leading to stretching of the joint capsule and separation of fibrous adhesions. The advantages of this method include its minimally invasive and low-trauma nature.

Conflict of Interest The authors declare no obvious or potential conflicts of interest related to the publication of this article.

Funding source The authors declare that there is no external financial support to conduct this study.

Ethical statement The study was conducted in accordance with the ethical standards of the World Medical Association's Declaration of Helsinki. Informed consent was obtained from patients involved in the trial to publish the study results.

REFERENCES

- Martinez-Lozano E, Beeram I, Yeritsyan D, et al. Management of arthrofibrosis in neuromuscular disorders: a review. *BMC Musculoskelet Disord*. 2022;23(1):725. doi: 10.1186/s12891-022-05677-z.
- Zhou H, Trudel G, Goudreau L, Laneuville O. Knee joint stiffness following immobilization and remobilization: A study in the rat model. *J Biomech*. 2020;99:109471. doi: 10.1016/j.jbiomech.2019.109471.
- Kaneguchi A, Ozawa J, Yamaoka K. Intra-articular injection of mitomycin C prevents progression of immobilization-induced arthrogenic contracture in the remobilized rat knee. *Physiol Res*. 2020;69(1):145-156. doi: 10.33549/physiolres.934149.
- Velasco BT, Patel SS, Broughton KK, et al. Arthrofibrosis of the Ankle. *Foot Ankle Orthop*. 2020;5(4):2473011420970463. doi: 10.1177/2473011420970463.
- Zhou Y, Zhang QB, Zhong HZ, et al. Rabbit Model of Extending Knee Joint Contracture: Progression of Joint Motion Restriction and Subsequent Joint Capsule Changes after Immobilization. *J Knee Surg*. 2020;33(1):15-21. doi: 10.1055/s-0038-1676502.
- Kalinsky EB, Kalinsky BM, Yakimov LA, et al. Possibilities of arthroscopy in the treatment of post-traumatic arthrofibrosis of the elbow joint. *Department of Traumatology and Orthopedics*. 2016;(Special issue):110-111. (In Russ.) URL: https://elibrary.ru/download/elibrary_28342249_96378304.pdf.
- Forsythe B, Lavoie-Gagne O, Patel BH, et al. Efficacy of Arthroscopic Surgery in the Management of Adhesive Capsulitis: A Systematic Review and Network Meta-analysis of Randomized Controlled Trials. *Arthroscopy*. 2021;37(7):2281-2297. doi: 10.1016/j.arthro.2020.09.041.
- Gupta A, Cand P, Rai D. Functional outcome of adhesive capsulitis treated by manipulation. *Int. J. Orthop. Sci*. 2020;6(3):10-14. doi: 10.22271/ortho.2020.v6.i3a.2168.
- MUA's Efficacy in Frozen Shoulder in Patients Which Already Received an Hidrodilatation. In: *ICH GCPUS Clinical Trials Registry Clinical Trial NCT05001438*. Hospital Clinic of Barcelona; .2021. <https://ichgcp.net/clinical-trials-registry/NCT05001438>.
- Luo Y, Xie X, Luo D, et al. The role of halofuginone in fibrosis: more to be explored? *J Leukoc Biol*. 2017;102(6):1333-1345. doi: 10.1189/jlb.3RU0417-148RR.
- Bayimbetov GD, Khodzhanov IYu. New approaches to pediatric treatment of post-traumatic elbow contractures. *Genij Ortopedii*. 2021;27(5):578-583. doi: 10.18019/1028-4427-2021-27-5-578-583.
- Serebryannikov N., Mashtalov V., Bekhterev A. The experience of conservative treatment of humeropathy pain syndrome. *Chief Physician of the South of Russia*. 2019;(1(65)):45-48. (In Russ.) Available at: <http://akvarel2002.ru/assets/files/GlaVrach-01-65-PREVIEW2.pdf>. Accessed Dec 12, 2025
- Naimann AI, Lychagin AV, Surin VV, et al. Our experience with the use of hydrodilatation redressation for the treatment of stiffness of the adhesive capsulitis at the shoulder joint. *Department of Traumatology and Orthopedics*. 2021;(3):37-42. (In Russ.) doi: 10.17238/issn2226-2016.2021.3.37-42.
- Stolbikov SA, Soldatov YuP. Hydraulic mobilization of the elbow joint and subchondral tunnelization of its metadiaphyseal bones as an alternative minimally invasive method of treating osteoarthritis. *Modern Problems of Science and Education*. 2018;6. (In Russ.) URL: <https://science-education.ru/ru/article/view?id=28382>.
- Barnes RH, Paterno AV, Lin FC, et al. Glenohumeral Hydrodistension for Postoperative Stiffness After Arthroscopic Primary Rotator Cuff Repair. *Orthop J Sports Med*. 2022;10(6):23259671221104505. doi: 10.1177/23259671221104505.
- Petlenko IS, Shubnyakov II, Fedunina SYu, et al. Assessing the need for improving tactics of surgical treatment in patients with elbow joint contractures (retrospective clinical study). *Saratov Journal of Medical Scientific Research*. 2024;20(2):154-159. (In Russ.) doi: 10.15275/ssmj2002154.
- Egiazaryan KA, Ratyev AP, Ershov DS, et al. Midterm outcomes of surgical treatment of patients with posttraumatic elbows arthrofibrosis. *Polytrauma*. 2025;(2):35-36. (In Russ.) doi: 10.24412/1819-1495-2025-2-28-35.
- Egiazaryan KA, Lazishvili GD, Ratyev AP, et al. Arthrofibrosis of the elbow joint: mechanisms and factors of development. *Surgical practice*. 2023;8(1):81-97. (In Russ.) doi: 10.38181/2223-2427-2023-1-7.

19. Haixiao Wu, Egiazaryan KA, Ratyev AP, Sanchez Sanchez XA. Surgical treatment of knee arthrofibrosis using arthroscopic debridement with continuous passive motion and intraarticular analgesia. *Department of Traumatology and Orthopedics*. 2018;2(32):55-59. (In Russ.) doi: 10.17238/issn2226-2016.2018.2.55-59.
20. Shchudlo NA, Stupina TA, Varsegova TN, Ostanina DA. Histological features of fascial fibromatosis in patients with rapidly progressive Dupuytren's contracture. *Traumatology and Orthopedics of Russia*. 2025;31(3): 111-120. (In Russ.) doi: 10.17816/2311-2905-17664.

The article was submitted 04.04.2024; approved after reviewing 21.01.2025; accepted for publication 06.04.2026.

Information about the authors:

Yuri Petrovich Soldatov — Doctor of Medical Sciences, Professor, Leading Researcher, Orthopaedic Surgeon, soldatov-up@mail.ru, <https://orcid.org/0000-0003-2499-3257>;

Abdulrab Nasser Abdulrab Mohammed Al Sameai — Postgraduate Student, Orthopaedic Surgeon, camiiabdolrab@gmail.com, <https://orcid.org/0009-0009-4457-5109>;

Nikita E. Ovchinnikov — Trainee.