



MSCT-semiotics of pin tract osteomyelitis

G.V. Diachkova[✉], K.A. Dyachkov, A.S. Sudnitsyn, N.M. Kliushin

Ilizarov National Medical Research Centre for Traumatology and Orthopedics, Kurgan, Russian Federation

Corresponding author: Galina V. Diachkova, dgv2003@list.ru

Abstract

Introduction Inflammation at the wire tract sites in patients treated with transosseous osteosynthesis is one of the most common complications. Bone manifestations of inflammation are quite common in clinical practice, yet characteristic radiographic findings have not been well described.

The **aim** of this study was to identify the nature of radiographic bone changes in patients with pin tract osteomyelitis at various inflammatory sites.

Materials and Methods The study included 22 patients with chronic pin tract osteomyelitis (PTO) that developed following transosseous osteosynthesis with the Ilizarov fixator. To assess structural bone changes, multislice computed tomography (MSCT) was used, including analysis of axial sections and multiplanar reconstructions (MPR) in the sagittal and coronal planes of the femur and tibia. Bone density (Hounsfield units, HU) in the inflammation area was quantitatively assessed, and the morphology of the wire tract canals (width, wall contours, and the presence of sequesters) was analyzed to identify patterns relevant for treatment decisions.

Results The data obtained indicate the presence of specific radiographic manifestations of osteomyelitis, characteristic of chronic osteomyelitis of any origin, especially in the late stages of inflammation. The most prominent symptoms of osteomyelitis in the early stages include characteristic changes in the wire tract canals: widening and blurring of the contours, increased density, and the appearance of periostitis around the wire tract. Wire canals in the metaphyseal regions are characterized by increased wall density and low density of the canal contents. In the diaphysis, the wire canals have walls with irregular contours and no density differences from the cortical plate. Small sequesters featuring the density of 650–700 HU are often visualized within the canal. "Walled-in" sequesters are also characteristic of pin tract osteomyelitis in the diaphysis.

Discussion The literature has devoted considerable attention to soft tissue inflammation, its prevention, and treatment methods during transosseous osteosynthesis. However, the radiographic semiotics of pin tract osteomyelitis have been limited, primarily presenting clinical cases without detailed analysis of bone changes. Pin tract osteomyelitis is characterized by general manifestations of osteolysis and increased density of the wire canal contours. A distinctive feature of pin tract osteomyelitis in the diaphysis is the presence of "button-shaped" sequesters, confirmed by MSCT. Information on the location and nature of the changes allows clinicians to more effectively plan the extent of surgical intervention and select the optimal treatment strategy, taking into account the characteristics of the lesion and bone condition.

Conclusion Wire tract canals in the metaphyseal regions are characterized by increased wall density. In the diaphysis, the wire tracts are wider than in the metaphysis, with walls of irregular contours and no density differences with the cortical plate. Sequestra in the metaphysis have half the density of those in the diaphysis and vary in shape and size.

Keywords: transosseous osteosynthesis, tibia, pin tract osteomyelitis, wire tract, MSCT, radiomorphological changes

For citation: Diachkova GV, Dyachkov KA, Sudnitsyn AS, Kliushin NM. MSCT-semiotics of pin tract osteomyelitis. *Genij Ortopedii*. 2026;32(1):14-22. doi: 10.18019/1028-4427-2026-32-1-14-22.

INTRODUCTION

External fixation has become a key tool in the arsenal of the orthopedic surgeon and is used in both in traumatology and reconstructive surgery. The clinical and biological advantages of transosseous osteosynthesis with the Ilizarov apparatus have been well studied. However, according to some authors, the key disadvantage of this type of fixation is inflammation and infection at the exit sites of transosseous elements, referred to in the foreign literature as pin track / tract / site infection (its incidence varies from 9 to 100 %) [1–4]. As noted by Shields et al., with a high incidence of inflammation around wires or pins, the occurrence of complications should be viewed not so much as an adverse event, but rather as an expected event of percutaneous treatment methods [5]. In such circumstances, minimizing inflammatory reactions becomes critically important to prevent the progression of infection, the development of pin tract osteomyelitis (PTO) and bone defects [6].

Classifications of inflammatory changes associated with the insertion of wires and pins have been presented in a number of studies which are based on subjective symptoms, radiographic signs, or microbiological analysis [2, 7, 8]. Thus, Checketts et al. [9] described a classification system for inflammation in the area of pins, consisting of three stages of superficial inflammation and three stages of severe inflammation [9]. The Gordon scale is a six-point classification system based on the presence of pain, radiographic results, and the appearance of erythema, serous or purulent discharge [10]. Rahbek et al modified this classification system by excluding the subjective symptom of pain and including a separate assessment for serous discharge [11]. An algorithm for detecting inflammation around the wires using only images has been proposed, which does not depend on subjective complaints of pain, radiographic results or microbiological studies, and simplifies home monitoring and early detection of inflammation around the wires using a set of high-quality digital images of “Gordon foci” [12].

Bone manifestations of inflammation around wires are quite common in clinical practice. However, radiographic manifestations have not been described despite being crucial for assessing bone quality in the area of inflammation to determine the extent of surgical intervention. A small number of foreign and domestic publications on PT osteomyelitis, primarily clinical cases, presented one or two radiographic symptoms of osteomyelitis, which is insufficient to determine its semiotics and severity [1, 13, 14, 15, 16].

The **aim** of this study was to identify the nature of radiographic bone changes in patients with pin tract osteomyelitis at various inflammatory sites.

MATERIAL AND METHODS

Study design

Inclusion criteria: age 18–60 years; availability of a complete set of radiographic images and a multislice computed tomography (MSCT) archive available to post-process the data.

MSCT was used to examine patients treated with transosseous compression-distraction osteosynthesis (TCDO) and pin osteomyelitis without other complications.

The study group included 22 patients diagnosed with osteomyelitis of the tibia and femur.

The control group consisted of seven patients with tibia fractures treated with transosseous osteosynthesis that did not develop PTO.

The average age of patients in the study group was 46.3 ± 9.9 years, and males were a majority (78.2 %). Of the 22 patients included in the study, 19 had previously been treated for tibia fractures, and three patients had undergone ankle arthrodesis. In one patient, the femur was fixed following a tibia

fracture. PTO signs were detected three to six months after the start of transosseous osteosynthesis treatment in 14 patients and in six cases after one year. Two patients with the purulent-inflammatory process that began in the area of the pin tracts continued as chronic osteomyelitis for over 10 years. In the control group, five of the seven patients were males. The average age was 44.7 ± 7.2 years. All patients in the control group were treated for tibia fracture using the Ilizarov fixator.

The studies were performed on Toshiba Aquilion-64 and GE Light Speed VCT computed tomography systems. Total and local bone density in HU was measured in various areas. Bone structure in the inflamed area and the features of the wires canal were examined using axial sections and multiplanar reconstructions (MPR) in sagittal and coronal projections of the femur and tibia (855 images). Bone density in Hounsfield units (HU) in the inflamed area was quantitatively assessed, and wire canal morphology (width, wall contours, and the presence of sequestra) was analyzed. In the control group, which had no complications, the wires canal width was determined after wire removal.

The study was conducted in accordance with the ethical standards of the World Medical Association's Declaration of Helsinki and of the Russian Ministry of Health, and was approved by the Ethics Committee of the Ilizarov National Medical Research Center of Traumatology and Orthopedics. All patients signed informed consent for publication of their data without identification.

Statistical processing of density parameters was performed using the Attestat program built into Microsoft Excel. The distribution type was determined using the Shapiro-Wilk test for samples with 50 or fewer observations. When assessing the normality of the sample distribution, most criteria revealed an abnormal data distribution, therefore, nonparametric statistical methods were used for analysis. Rates and proportions (in %) were used to describe qualitative data. The Mann-Whitney test was used to compare independent data. Comparison of mean values of two paired (dependent) groups was performed using the one-sample Wilcoxon test, described by the median (Me) and percentiles. Comparison of two qualitative independent groups of nominal data was performed using the Pearson chi-square (χ^2) test. Differences were considered statistically significant at p value < 0.05 .

RESULTS

Bone density in the proximal tibial metaphysis at the level of the wire tract varied within the range: from (223.4 ± 25.8) HU to negative Hounsfield values, mainly in the central parts of the metaphysis. The density of the wire tract walls in the metaphyseal parts always exceeded the bone density, (376.7 ± 85.4) HU, reaching (792.8 ± 69.7) HU in some areas ($p < 0.02$). The contents of the pin tract had a lower density, not exceeding (179.4 ± 65.7) HU. In some cases, the density of the contents of the wire tract was significantly lower, (12.5 ± 3.8) HU (Fig. 1).

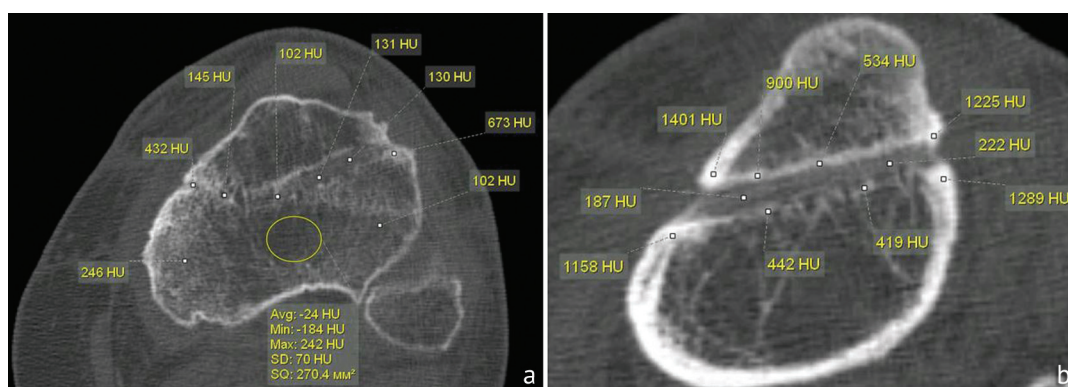


Fig. 1 MSCT of the tibia of a 50-year-old female patient diagnosed with PTO: axial sections: (a) bone and the contents of the wire tract density measurements; (b) density of the walls of the wire tract measurements

Progression of PT osteomyelitis resulted in the formation of bone defects of varying shape and length in the area of the wire canal that had clear contours and a significant increase in the density of its walls. In transcortical wire insertion through the proximal tibial epiphysis, the density of the fragment located externally to the wire canal was lower than the density of the cortical plate of the main part of the bone in 52 % of patients. Wire canals in the area of the proximal or distal metaphysis or epiphysis of the tibia and the distal metaepiphysis of the femur were characterized by an increase in the density of the canal walls, manifesting as a clear demarcation line from the adjacent areas of spongy bone with a decrease in its density. The density of the cortical plate differed in some sections by (189.7 ± 96.5) HU. The density of sequestrs in the metaepiphysis was less than the density of the cortical plate in 89.5 % of cases, (675.5 ± 93.9) HU (Fig. 2).

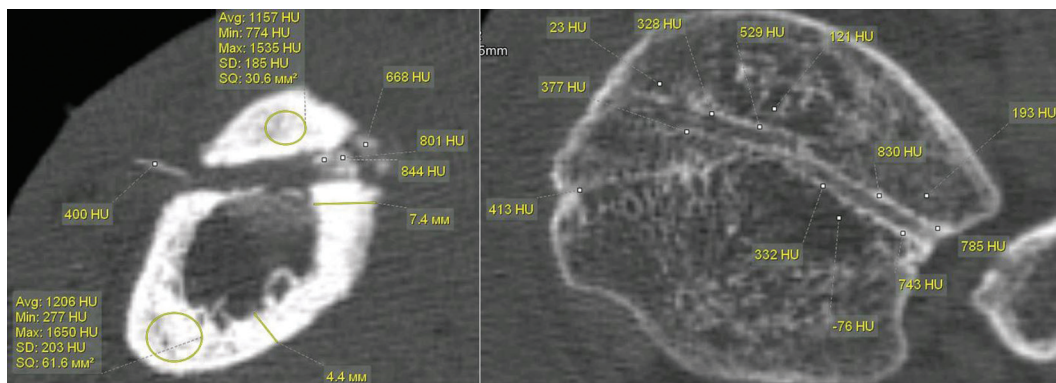


Fig. 2 MSCT of the lower leg of a 55-year-old patient with PTO, axial sections

The pattern of PT osteomyelitis in the proximal tibia depended on the duration of the disease and the level of wire insertion. Characteristic features included decreased bone density, resorption zones in the epiphysis, and significant bone destruction in the metaphysis with denser areas at the edges of the destruction. The inflammatory process was always accompanied by significant architectural changes, resorption zones, and areas of rarefaction. The wire tracts had a characteristic appearance in this bone part: distinct boundaries with a higher density than the adjacent bone areas (Fig. 3).

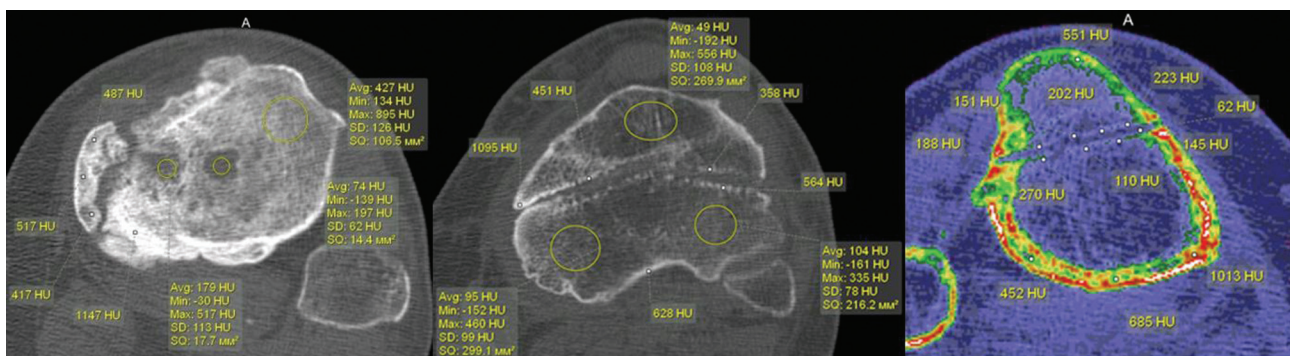


Fig. 3 MSCT of the lower legs of PTO patients, axial sections at the level of the proximal tibia

The wire canal was wider in the area of the cortical plate. The density of the wire canal walls increased to 480 [420;620] HU (median) (Fig. 4 a). If PTO was localized in the distal third of the tibia and the disease progressed for a long time (more than a year), changes in this part were manifested by areas of destruction, disruption of bone structure, the appearance of zones of rarefaction and sclerosis. In all cases, the inflammatory and destructive process spread to the bones of the foot, accompanied by defects, structural changes with disruption of the organotypic structure of the bones, and zones of resorption (Fig. 4 b, c).

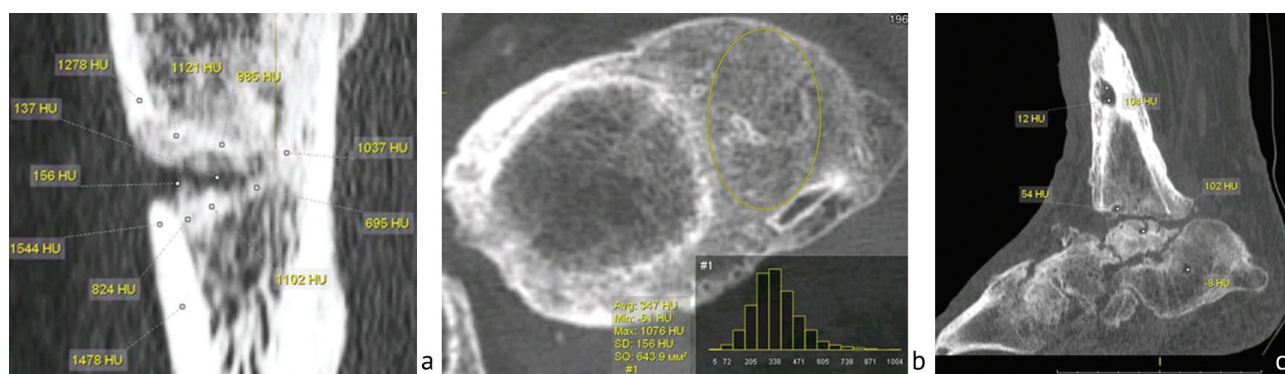


Fig. 4 MSCT of the lower legs of PTO patients: (a) 34-year-old female patient, MPR in the sagittal plane; (b) 56-year-old patient, axial section, massive periosteal layers assimilated with the cortical plate; (c) MPR of the same patient in the sagittal plane

In the diaphysis, inflammatory changes were lower, especially in cases where prompt measures were taken to eliminate the source of infection (early surgical drainage and adequate antibacterial therapy). The data were obtained from an analysis of patients' records with rapid resolution of the inflammatory process based on the comprehensive treatment within the first one to two weeks of the disease onset. In cases of prolonged disease progression (usually more than three to four weeks), wide wire canals and sequestra developed.

An increased width and unclear contours of the wire canal along with an increased density of its walls were registered in the early PTO stages. The width of the canal was compared with its dimensions after wire removal in patients without an inflammatory process (control group). The median width of the wire canal in the diaphysis in those cases was 1.6 [1.4; 1.7]. The width of the wire canal after pin removal in septic osteomyelitis in the diaphysis varied significantly, from 3.5 mm to 7.0 mm. The median width of the wire canal in the diaphysis in PTO patients was 4.1 mm [interquartile range 3.8; 5.1 mm]. For comparison, the width of the wire canal in the epiphysis was smaller and was 2.6 mm [2.8; 3.1 mm], what is associated with the anatomical features of the structure of the proximal tibia in this zone (Fig. 5).

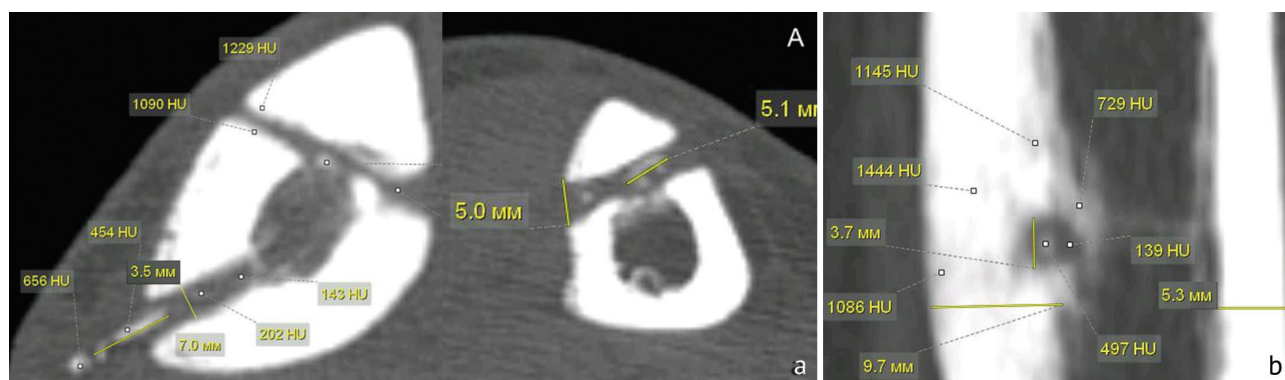


Fig. 5 MSCT of the lower leg of PTO patients aged 36 (a) and 42 (b). Width of the wire tract: (a) axial section; (b) MPR in the sagittal plane

A characteristic location of an "embedded" sequestrum in the cortex with inflammation localized at the level of the middle third of the diaphysis, identified by MSCT, was observed in five patients from the study group. This type of sequestrum is a narrow circular area of necrotic bone surrounded by a radiolucent halo, which is a characteristic sign of an active infectious process and reactive inflammation in the surrounding tissues. We reached this conclusion based on a comparison

of MSCT images with clinical data and microbiological results that confirmed infection in the focus. In the literature, such sequestra are described as "button-shaped" due to their shape and limited size [17, 18, 19] (Fig. 6).

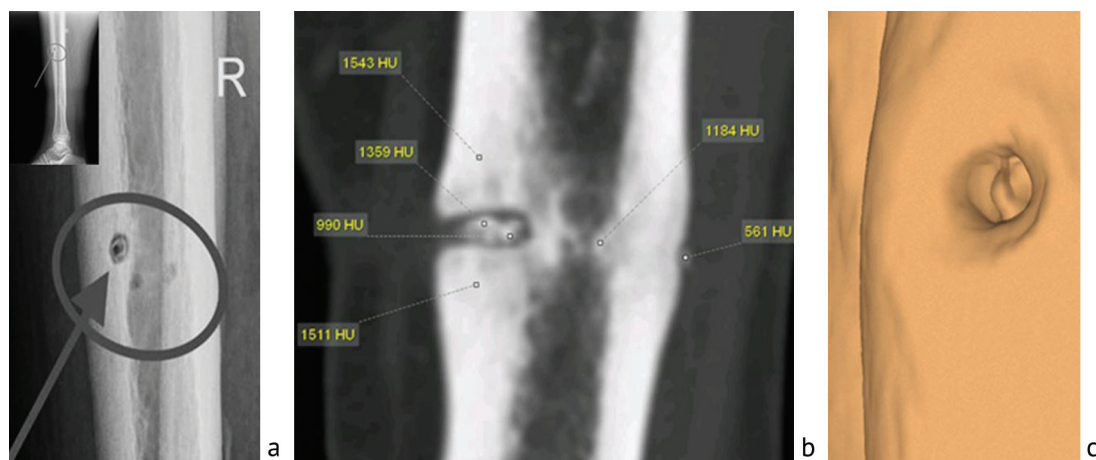


Fig. 6 X-ray of the lower leg of a 46-year-old patient with PTO in the lateral projection, circular "button-shaped" sequestrum (a); MSCT of the lower leg of a 52-year-old patient with PTO, walled-in sequestrum, MPR in the frontal plane (b); 3D reconstruction, visual representation of the circular "button-shaped sequestrum" (c)

The incidence of such "button-shaped" sequestra in our sample was approximately 15 %. The size and shape of sequestra in the metaphysis and diaphysis varied significantly. In the diaphysis, sequestra were more often rectangular in shape, with the horizontal side two to three times longer. In the metaphysis, sequestra were of indeterminate shape in 85.6 % of cases and varied in size, but were no larger than 5 mm in 80.5 %. Sequestra in different bone parts varied in density. In the metaphysis, the density was (652.4 ± 45.8) HU, while in the diaphysis it was (1388.6 ± 92.7) HU ($p < 0.01$).

Figure 7 shows the density of necrotic and normal bone areas. The median for necrotic bone was 1388 [1315;1430] and 1248 [1198;1302] for unchanged bone ($p < 0.05$).

Table 1 presents data on the density of the walls of the wire canal in transcortical insertion of the wire in various parts of the tibia.

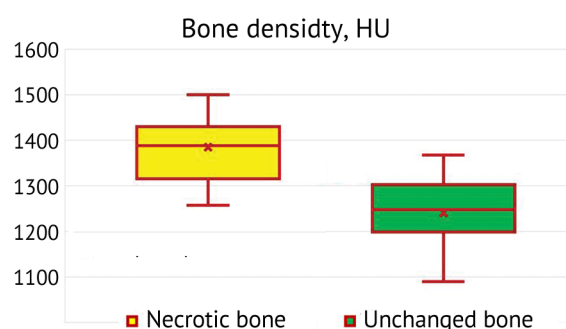


Fig. 7 Density in the area of necrotic and unchanged bone

Table 1

Density of the walls of the wire canal in transcortical insertion of the wire through the tibial tuberosity and diaphysis

Involved area	Density value, HU	
	M	σ
Density of the walls of the wire canal in the metaphysis	798.5	69.4*
Density of the walls of the wire canal in the diaphysis	1289.6	74.8

Note: * $p < 0.035$ – significant difference in the density of the walls of the wire canal in the metaphysis and diaphysis

DISCUSSION

According to a number of authors, the use of the Ilizarov transosseous osteosynthesis method is accompanied by such a frequent complication as inflammation at the site of wire/pin insertion [20, 21]. The nature and severity of the inflammatory process are determined by many factors and are either remediable soft-tissue inflammation or can lead to pin tract osteomyelitis with various

consequences such as severe bone destruction and defects. In the literature, considerable attention has been devoted to soft tissue inflammation, methods of its prevention and treatment, whereas the radiological semiotics of osteomyelitis has been described in a small number of works, which are mainly case reports without a detailed description of the nature of bone changes [22, 23, 24, 25].

Our data demonstrate both the presence of specific radiographic manifestations of pin tract osteomyelitis and signs characteristic of chronic osteomyelitis of any etiology, especially in the late stages of infectious process. The most characteristic radiographic bone changes in PT osteomyelitis, which appear in the early stages within one to three weeks of the disease onset, include: osteolysis around the pin or wire; increased bone density; and the appearance of linear or crest-like periostitis around the pin tract. To objectively evaluate these changes, we compared radiographic data with pin tracts in patients without osteomyelitis, as well as with the contralateral limb, where inflammation was not detected. This allowed us to identify pathological changes that deviate from the anatomical norm.

The wire tracts in the metaphyseal regions are characterized by increased density of their walls and low-density of the canal contents with areas having negative Hounsfield values, indicating the presence of inflammatory or necrotic material. In the diaphysis, the wire tracts were wider than in the metaphysis; the canal walls had irregular contours and showed no density differences with the cortical plate. Small sequestra with a density of 650–700 HU were often visualized within the canals.

The PTO in the diaphysis is also characterized by so-called "walled-in" sequestra in the cortical plate, which follow the contours of the wire canal and resemble a "button-like sequestra" when examined using 3D CT. This phenomenon is confirmed by data from other studies, where similar shapes of sequestra were described with inflammation localized in the cortical bone layer in the early stages of chronic osteomyelitis [13, 14].

In patients with a long course of osteomyelitis (more than three to four weeks) or recurrences of the disease, the radiomorphological picture of destructive changes in the metaphyseal bone did not differ from that of typical chronic osteomyelitis. Specifically, when chronic osteomyelitis was localized in the tibial metaphysis, the inflammatory and destructive processes also spread to the bones of the foot. We also noted anatomical changes (defects, uneven contours), decreased bone density, and areas of sclerosis and resorption. These data are supported by the results of a number of clinical and radiographic studies [26, 27] and allow us to consider them to be reliable and reproducible. In the presence of chronic infection, sequestration is the main diagnostic sign of chronic osteomyelitis. However, sequestrations can also be observed in other diseases, such as eosinophilic granuloma and osteoid osteoma, where the so-called "button-like" sequester has also been described [17, 18, 19]. These studies describe in detail the characteristics of "button" sequester and its clinical significance, which is important to consider in differential diagnosis.

Given the specific bone changes in PTO that were identified in this study and depend on the location of the inflammatory process, this work may be useful for clinicians when planning the extent of surgical intervention. The key idea is that the extent and nature of pathological changes in the diaphysis and metaphysis in PTO vary significantly. In planning a surgery, these data allow for an estimate of the required extension of the intervention, which is important for choosing a surgical technique (considering the location of inflammation in the diaphysis or metaphysis), as well as for preparing patients based on their clinical, laboratory, and MSCT status. Thus, information on radiographic and MSCT features, as well as the timing of disease manifestation, facilitates a more accurate and individualized approach to treating patients with pin tract osteomyelitis.

CONCLUSION

Early radiographic signs of pin tract osteomyelitis include widening of the wire canal, increased density of its walls, blurred contours, and the formation of linear or ridge-like periostitis around the wire. In the metaphyseal regions, the wire canals are characterized by increased wall density (200–400 HU), low-density contents, including areas with negative HU values, and clear demarcation zones, reflecting the presence of an inflammatory process with the formation of boundaries between the affected and healthy tissue. In the diaphysis, the canals are wider, the walls have irregular contours, and a density comparable to that of the cortical plate (500–700 HU), which requires differential diagnosis with other diseases, such as tumor process or benign bone tumors.

Sequestra in PTO exhibit marked variability depending on their location. In the metaphysis, sequestra have a density half that in the diaphysis (250–350 HU versus 600–700 HU), are smaller in size, and have an irregular shape. In the diaphysis, "walled-in" sequestra in the cortex are typical, as are the fragments with a density of up to 800 HU, surrounded by a demarcation zone with a density of 100–150 HU. A pathognomonic sign of a long-term (more than three to four weeks) PTO in the diaphysis is a sequestrum that follows the contour of the wire canal, a so-called "ring-shaped" or "button" sequestra, confirming the connection between sequestra formation and the inserted wire zone.

Conflict of interests The authors declare no obvious or potential conflicts of interest related to the publication of this study.

Funding source The work was carried out within the framework of the State Assignment "Study of the kinetics of antibiotic release from various materials used to manage bone tissue defects, as well as an assessment of their tolerability "in vivo".

Informed consent The patients signed informed consent for the publication of their information in the study without identification.

REFERENCES

1. Gayuk VD, Kliushin NM, Burnashov SI. Pin site soft tissue infection and osteomyelitis: literature review. *Genij Ortopedii*. 2019;25(3):407-412. doi: 10.18019/1028-4427-2019-25-3-407-412.
2. Kazmers NH, Fragomen AT, Rozbruch SR. Prevention of pin site infection in external fixation: a review of the literature. *Strategies Trauma Limb Reconstr*. 2016;11(2):75-85. doi: 10.1007/s11751-016-0256-4.
3. Lethaby A, Temple J, Santy-Tomlinson J. Pin site care for preventing infections associated with external bone fixators and pins. *Cochrane Database Syst Rev*. 2013;2013(12):CD004551. doi: 10.1002/14651858.CD004551.pub3.
4. Timms A, Pugh H. Pin site care: guidance and key recommendations. *Nurs Stand*. 2012;27(1):50-55; quiz 56. doi: 10.7748/ns2012.09.27.1.50.c9271.
5. Shields DW, Iliadis AD, Kelly E, et al. Pin-site Infection: A Systematic Review of Prevention Strategies. *Strategies Trauma Limb Reconstr*. 2022;17(2):93-104. doi: 10.5005/jp-journals-10080-1562.
6. Guerado E, Cano JR, Fernandez-Sanchez F. Pin tract infection prophylaxis and treatment. *Injury*. 2019;50 Suppl 1:S45-S49. doi: 10.1016/j.injury.2019.03.044.
7. Clint SA, Eastwood DM, Chasseaud M, et al. The "Good, Bad and Ugly" pin site grading system: A reliable and memorable method for documenting and monitoring ring fixator pin sites. *Injury*. 2010;41(2):147-150. doi: 10.1016/j.injury.2009.07.001.
8. Ward P. Care of skeletal pins: a literature review. *Nurs Stand*. 1998;12(39):34-38. doi: 10.7748/ns1998.06.12.39.34.c2514.
9. Checketts RG, Otterburn M, Graham AA. Pin track infection and the principles of pin site care. In: DeBastiani AGAA, Goldberg DE (eds.) *Orthofix external fixation in trauma and orthopedics*. London: Springer London; 2000:97-103. doi: 10.1007/978-1-4471-0691-3_11.
10. Ceroni D, Grumetz C, Desvachez O, et al. From prevention of pin-tract infection to treatment of osteomyelitis during paediatric external fixation. *J Child Orthop*. 2016;10(6):605-612. doi: 10.1007/s11832-016-0787-8.
11. Rahbek O, Husum HC, Fridberg M, et al. Intrarater Reliability of Digital Thermography in Detecting Pin Site Infection: A Proof of Concept Study. *Strategies Trauma Limb Reconstr*. 2021;16(1):1-7. doi: 10.5005/jp-journals-10080-1522.
12. Bafor A, Skals RG, Shen M, et al. An assessment of the inter-rater and intra-rater reliability of the modified Gordon pin infection classification system. *Digit Health*. 2024;10:20552076241277672. doi: 10.1177/20552076241277672.
13. Nguyen VD, London J, Cone RO 3rd. Ring sequestrum: radiographic characteristics of skeletal fixation pin-tract osteomyelitis. *Radiology*. 1986;158(1):129-131. doi: 10.1148/radiology.158.1.3940369.
14. Vaishya R, Vaish A. Ring sequestrum of the tibia. *BMJ Case Rep*. 2014;2014:bcr2013201837. doi: 10.1136/bcr-2013-201837.
15. Timmer IR, Emmink BL, Leenen LPH, Govaert GAM. Complete ejection of a ring sequestrum 8 years after external fixation of the tibia. *BMJ Case Rep*. 2020;13(3):e233196. doi: 10.1136/bcr-2019-233196.
16. Jardaly AH, LaCoste K, Gilbert SR, Conklin MJ. Late Deep Infections Complicating Percutaneous Pinning of Supracondylar Humerus Fractures. *Case Rep Orthop*. 2021;2021:7915516. doi: 10.1155/2021/7915516.

17. Mehri A, SeilanianToosi F, Samini F, et al. Parietal bone osteoid osteoma: A rare cause of button sequestrum sign in pediatrics. Case report and review of literature. *Clin Case Rep*. 2022;10(10):e6416. doi: 10.1002/ccr3.6416.
18. Christodoulou EF, Nistikoulis G, Deftereos SP. Button Sequestrum Sign Due to Osteomyelitis of the Mandible Secondary to Malignant Infantile Osteopetrosis. *Maedica (Bucur)*. 2021;16(3):531-533. doi: 10.26574/maedica.2020.16.3.531.
19. Krasnokutsky MV. The button sequestrum sign. *Radiology*. 2005;236(3):1026-1027. doi: 10.1148/radiol.2363031294.
20. Kryuchkov RA, Kunafin MS, Khunafin SN. Osteomyelitis after osteosynthesis using of metal in patients with closed fractures of tubular bones. *Creative surgery and oncology*. 2013;(4):62-64. (In Russ.) doi: 10.24060/2076-3093-2013-0-4-62-64.
21. Lethaby A, Temple J, Santy-Tomlinson J. Pin site care for preventing infections associated with external bone fixators and pins. *Cochrane Database Syst Rev*. 2013;2013(12):CD004551. doi: 10.1002/14651858.CD004551.pub3.
22. Chan CK, Saw A, Kwan MK, Karina R. Diluted povidone-iodine versus saline for dressing metal-skin interfaces in external fixation. *J Orthop Surg (Hong Kong)*. 2009;17(1):19-22. doi: 10.1177/230949900901700105.
23. Ferreira N, Marais LC. Prevention and management of external fixator pin track sepsis. *Strategies Trauma Limb Reconstr*. 2012;7(2):67-72. doi: 10.1007/s11751-012-0139-2.
24. Frank FA, Stubbs D, Ferguson JY, McNally M. A practical definition of pin site infection. *Injury*. 2024;55(2):111230. doi: 10.1016/j.injury.2023.111230.
25. Hamahashi K, Uchiyama Y, Kobayashi Y, Watanabe M. Delayed methicillin-resistant Staphylococcus aureus-induced osteomyelitis of the tibia after pin tract infection: two case reports. *J Med Case Rep*. 2017;11(1):23. doi: 10.1186/s13256-016-1187-x.
26. Diachkova GV, Diachkov KA, Larionova TA, et al. A multifaceted osteomyelitis: radiological diagnosis. *Genij Ortopedii*. 2020;26(3):385-391. doi: 10.18019/1028-4427-2020-26-3-385-391.
27. Diachkova GV, Mitina YuL, Klyushin NM, et al. Bone quality in patients with chronic osteomyelitis of the foot according to computed tomography data. *Journal of radiology and nuclear medicine*. 2016;97(4):206-214. (In Russ.) doi: 10.20862/0042-4676-2016-97-4-206-214.

The article was submitted 25.04.2025; approved after reviewing 29.10.2025; accepted for publication 08.12.2025.

Information about the authors:

Galina V. Diachkova — Doctor of Medical Sciences, Professor, dgv2003@list.ru, <https://orcid.org/0000-0003-1973-4680>;

Konstantin A. Dyachkov — Doctor of Medical Sciences, Head of Department, dka_doc@mail.ru, <https://orcid.org/0000-0002-8490-3025>;

Anatolii S. Sudnitsyn — Candidate of Medical Sciences, orthopaedic surgeon, Head of Laboratory, Associate Professor, anatol_anatol@mail.ru, <https://orcid.org/0000-0002-2602-2457>;

Nikolay M. Kliushin — Doctor of Medical Sciences, Chief Specialist, orthopaedic surgeon, klyushin_nikolay@mail.ru, <https://orcid.org/0000-0002-1601-9713>.