



Original article

<https://doi.org/10.18019/1028-4427-2023-29-6-650-655>**Aneurysmal bone cyst of the medial cuneiform bone:
a case report of a new surgical approach and literature review**Sergey S. Leonchuk^{1✉}, Tiwari Punit²¹ Ilizarov National Medical Research Centre for Traumatology and Orthopedics, Kurgan, Russian Federation² Maharishi Markandeshwar University of Health Sciences and Medical College, Kumarhatti, Solan, Himachal Pradesh, India

Corresponding author: Sergey S. Leonchuk, leon4yk@mail.ru

Abstract

Introduction An aneurysmal bone cyst (ABC) is a rare, non-neoplastic, destructive, hemorrhagic, and expansile lesion accounting for 1 % of all bone tumors. ABC of the foot is very rare. Patients with foot ABC usually complain of pain and swelling of the affected area. Radiographs and MRI may be helpful in the diagnosis of ABC. No single surgical procedure has gained wide acceptance in the treatment of foot ABC. **Purpose** To show new effective surgical approach in the treatment of patient with ABC of the medial cuneiform bone. **Material and methods** We present the case of a 47-year-old woman with a 10-months history of pain and swelling in her right foot. Postoperative histopathological evaluation of resected tissues confirmed the diagnosis of ABC. An en bloc resection (total extraction of the remnant of the medial cuneiform bone) was performed and the defect was replaced with a fibular bone graft from the right leg. Allograft (Bio-Ost®) was placed along the autograft. Tibialis anterior tendon was attached to the fibular bone graft. We performed fixation of the foot and ankle using the Ilizarov original apparatus for prevention of bone graft instability and opportunity for early weight-bearing on the operated foot. **Results** The postoperative period was uncomplicated with complete healing of the bone defect without recurrence after 12 months of observation. AOFAS score increased significantly from 34 points preoperatively to 92 at 1-year follow-up. **Discussion** The optimal treatment of this lesion is still under discussion. Different treatment modalities have been described in the literature: wide resection, curettage with or without adjuvants, arterial embolization, intralesional sclerotherapy. Biological reconstruction using bone graft seems to be the best option, but fractures and nonunion are common complications of bone grafting. **Conclusion** The combination of Ilizarov external fixation and bone grafting provided favorable conditions for the healing of foot bone defect due to ABC without complications, allowed mobility and early weight-bearing of the patient. Recurrence was not detected radiologically. Harvesting of the fibular bone graft did not affect the position of the foot and its movements. Our surgical approach should be considered as a treatment option in similar cases.

Keywords: Aneurysmal bone cyst, Foot, Ilizarov, bone graft; external fixation, allograft, medial cuneiform bone**For citation:** Leonchuk S.S., Punit T. Aneurysmal bone cyst of the medial cuneiform bone: a case report of a new surgical approach and literature review. *Genij Ortopedii*. 2023;29(6):650-655. doi: 10.18019/1028-4427-2023-29-6-650-655

Научная статья

УДК 617.586-006.03-089.227.844(048.8)

**Аневризмальная киста медиальной клиновидной кости:
клинический случай нового хирургического подхода и обзор литературы**Сергей Сергеевич Леончук^{1✉}, Tiwari Punit²¹ Национальный медицинский исследовательский центр травматологии и ортопедии имени академика Г.А. Илизарова, Курган, Россия² Maharishi Markandeshwar University of Health Sciences and Medical College, Kumarhatti, Solan, Himachal Pradesh, India

Автор, ответственный за переписку: Сергей Сергеевич Леончук, leon4yk@mail.ru

Аннотация

Введение. Аневризмальная костная киста (АКК) – редкое не неопластическое, деструктивное, геморрагическое и экспансивное поражение, составляющее 1 % от всех опухолей костей. АКК стопы встречается очень редко. Пациенты с АКК стопы обычно жалуются на боль и отек пораженной области. В диагностике АКК могут помочь рентгенография и МРТ. Ни одно хирургическое вмешательство не получило широкого признания при лечении АКК стопы. **Цель.** Представить новый эффективный хирургический подход в лечении пациента с АКК медиальной клиновидной кости. **Материалы и методы.** Мы представляем случай 47-летней женщины с 10-месячной историей боли и отека в правой стопе. Послеоперационная гистопатологическая оценка резецированных тканей подтвердила диагноз АКК. Была выполнена блоковая резекция (полное удаление остатка медиальной клиновидной кости), дефект был замещен трансплантатом из малоберцовой кости правой голени. Аллотрансплантат ("Bio-Ost"®) укладывался вдоль аутоотрансплантата. Сухожилие передней большеберцовой мышцы прикрепляли к трансплантату малоберцовой кости. Для профилактики нестабильности костного трансплантата и возможности ранней нагрузки на оперированную стопу выполняли фиксацию стопы и голеностопного сустава с помощью оригинального аппарата Илизарова. **Результаты.** Послеоперационный период протекал без осложнений с полным заживлением костного дефекта без рецидива через 12 месяцев наблюдения. Оценка по шкале AOFAS значительно увеличилась с 34 баллов до операции до 92 баллов на контрольном осмотре через 1 год. **Обсуждение.** В литературе описаны различные методы лечения: широкая резекция, кюретаж с адьювантами или без них, эмболизация артерий, склеротерапия образования. Биологическая реконструкция с использованием костного трансплантата представляется наилучшим вариантом, однако переломы и несращение являются частыми осложнениями костной пластики. **Заключение.** Применение комбинации внешней фиксации по Илизарову и костной пластики позволило создать благоприятные условия для заживления костного дефекта стопы при АКК без осложнений, сохранить пациенту подвижность и раннюю осевую нагрузку. Рецидив рентгенологически не определялся. Забор костного трансплантата из малоберцовой кости не повлиял на положение и подвижность пролеченной стопы. Наш хирургический подход следует рассматривать как вариант лечения в аналогичных случаях. **Ключевые слова:** аневризмальная костная киста, стопа, Илизаров, костный трансплантат, внешняя фиксация, аллотрансплантат, медиальная клиновидная кость

Для цитирования: Леончук С.С., Punit T. Аневризмальная киста медиальной клиновидной кости: клинический случай нового хирургического подхода и обзор литературы. *Гений ортопедии*. 2023;29(6):650-655. doi: 10.18019/1028-4427-2023-29-6-650-655. EDN: UFIEDR.

INTRODUCTION

An aneurysmal bone cyst (ABC) is a rare, non-neoplastic, destructive, hemorrhagic, and expansile lesion accounting for 1 % of all bone tumors [1]. The etiology of this pathology is unknown, although it is

now commonly accepted that benign bone cysts are caused by trauma or local circulatory disturbance, which results in an increase in venous pressure and the development of enlarged and dilated vascular components within

the affected bone [2, 3]. Overall, ABC is diagnosed more commonly in the second decade of life and is more common in females than in males [4].

Midfoot ABC is very rare. Patients with foot ABC usually complain of pain and swelling in the affected area. Radiograph and magnetic resonance imaging (MRI) may be helpful in the diagnosis of ABC. A radiograph of the patient's foot demonstrates a lytic lesion in the medial cuneiform and MRI shows cystic formations with typical fluid-fluid levels due to blood sedimentation. A histopathological examination is needed to evaluate the ABC.

The differential diagnosis associated with ABC includes giant cell tumor, giant cell reparative granuloma, Brown tumor arising from hyperparathyroidism, chondroblastoma, or telangiectatic osteosarcoma [1, 3, 5, 6].

Several classifications of ABC have been proposed based on natural history, activity, and morphological features [7-10]. There is a very useful classification of ABC

according to Capanna et al [7], which is based primarily on the extent and size of the cyst and its proximity to the cortex and soft tissues, described five morphological subgroups (types) and three distinct stages.

No single surgical procedure has gained wide acceptance in the treatment of foot ABC. The predominant therapy for ABCs is an intralesional resection performing curettage with the use of adjuvants [11]. A wide resection, especially in the foot, is not easy to achieve and can cause complications depending on the dimension of the operation and the localization [11]. Medial cuneiform bone is an important cornerstone for medial arch continuity, structural integrity, and pathological fracture risks are the conditions that should be considered in the treatment of foot ABC [12].

Purpose: to show a new effective surgical approach to the treatment of patient with ABC of the medial cuneiform bone.

MATERIALS AND METHODS

We present a clinical case of aneurysmal bone cyst of the medial cuneiform bone in an adult woman with a 10-month history of pain and swelling of her right foot and the long-term result of using Ilizarov external fixation and bone grafting.

A female patient, 47 years old, was admitted to the Ilizarov Center with complaints of pain and swelling in her right foot (Fig. 1, a). The patient had a 10-month history of complaints and was treated conservatively without any relief. Pain and swelling in right foot were increasing in the last 3 months. The patient lived in the countryside and had no history of significant personal, ethnic, demographic, or life incidents. There was no history of trauma. No allergies were reported. Blood analysis and urine analysis were normal. Electrocardiogram, chest X-ray, and arterial blood gas were also normal. Functional condition according to the American Orthopedic Foot and Ankle Society (AOFAS) was 34 points preoperatively with a full range of ankle joint motion.

Radiographs and CT showed a lytic lesion in the medial cuneiform with subtotal bone defect (Fig. 1, b). MRI revealed a well-defined lesion with multiple thin septations and typical fluid-fluid levels due to blood sedimentation (Fig. 2).

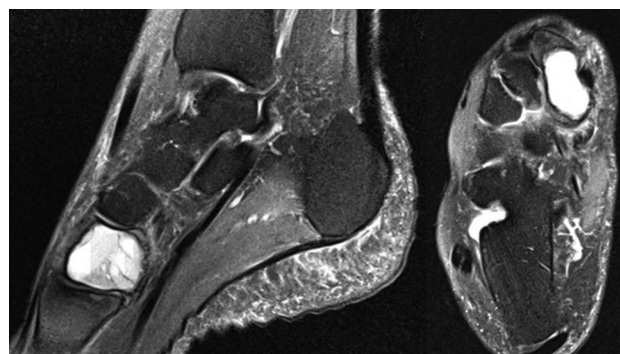


Fig. 2. MRI scans of the right foot showing a multiloculated expansile lytic lesion with multiple thin septations and typical fluid-fluid levels due to blood sedimentation

According to Capanna et al. classification, the ABC was type I (centrally located lesions that are well contained with no outline or slightly expanded) in the active stage.

Intraoperative biopsy aspirate was haemorrhagic; postoperative histopathological evaluation of resected tissues confirmed the diagnosis of ABC (Fig. 3).

Firstly, we applied the Ilizarov original frame on the right leg and foot with universal hinges (Fig. 4). At the level of the middle third of the lower leg, one wire and one half-pin were drilled, and in the lower third three wires were inserted (one was an olive wire through both bones); three wires were passed through the forefoot. We applied two full rings in the tibia and two half-rings in the forefoot.

In the 2nd step, we produced a medial longitudinal incision in the midfoot area. We cut the tibialis anterior tendon at its insertion and tagged its end with sutures. En bloc resection of the lesion (extraction of the remnant of medial cuneiform bone) was performed (Fig. 5, a, b, c). A fibular bone graft was harvested from the lower third of the right leg and the graft, about 4 cm long, was placed while preserving the medial arch of the foot (Fig. 5 d). The fibular bone graft was slightly tapered on both ends with about 3 mm bevelled edges and shaped so as to lock and fill in the defect between the first metatarsal and navicular bones. A prepared allograft (Bio-Ost®) was placed along the autograft (Fig. 5, e). The hole was drilled through the fibular bone graft and the tibialis anterior tendon was attached to it (Fig. 5, f).

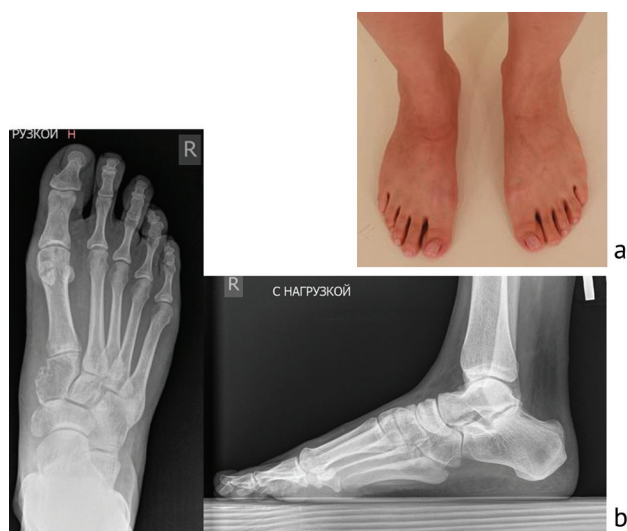

Fig. 1. Before surgery: a – photo; b – X-ray pictures in anterior-posterior (AP) and lateral views (demonstrating an osteolytic lesion of the medial cuneiform)

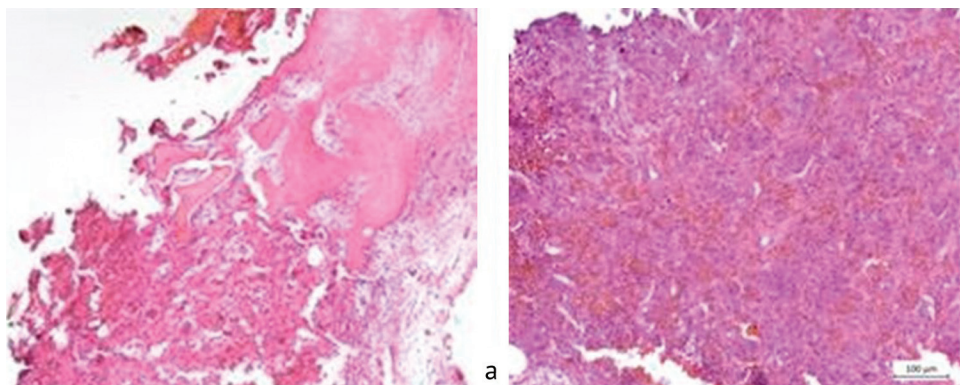


Fig. 3. HE-stained sections of resected tissues (histopathological evaluation): a – lamellae surrounded with congestion of small blood vessels, and blood-filled cystic spaces separated by fibrous septae ($\times 40$); b – multiply of osteoblast proliferation, fibrous connective tissue and multinucleated giant cell proliferation ($\times 100$). HE – hematoxylin-eosin

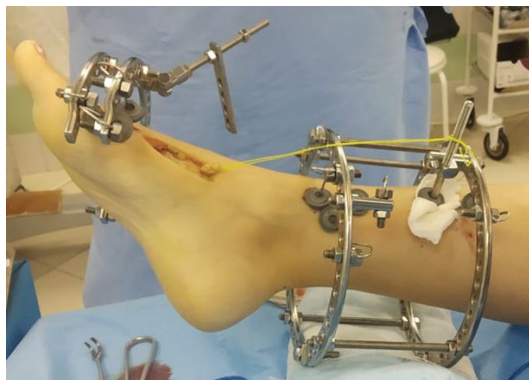

Fig. 4. Photo of the right leg and foot after partial Ilizarov frame assembly and medial longitudinal incision in the midfoot

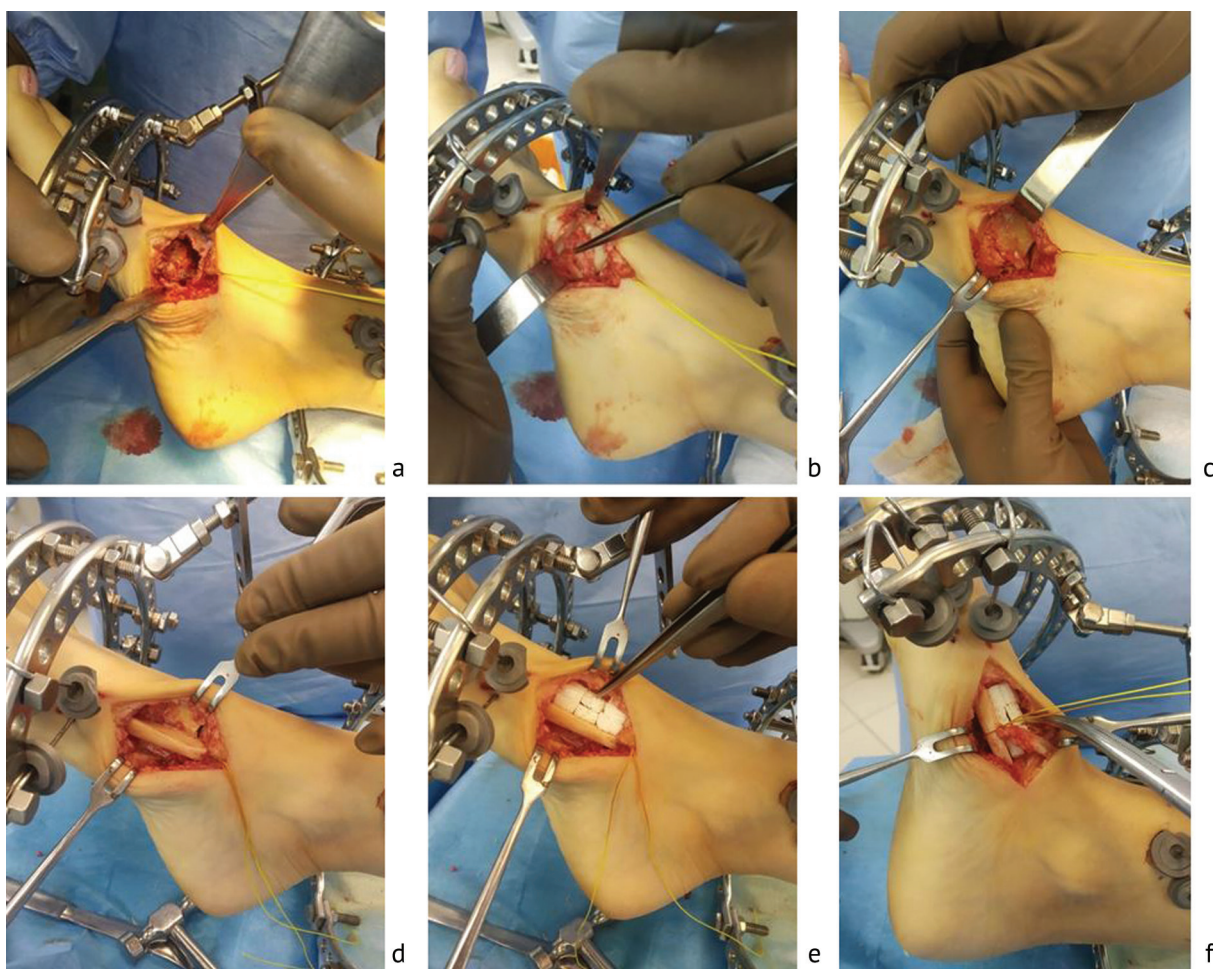


Fig. 5. Photos during the operation steps: a – view of the lytic bone process; b – zone of the defect after resection of the lesion; c – the size of the defect after resection of articular surfaces of 1st metatarsal, central cuneiform, and navicular bones; d – fibular bone graft shaped to fill the defect between the first metatarsal, central cuneiform, and navicular bones; e – placement of the allograft (Bio-Ost®) along the autograft; f – attaching the tibialis anterior tendon to the fibular bone graft

In the next step, we added two olive wires through the hindfoot (calcaneus) and one olive wire through the navicular bone (Fig. 6). The final Ilizarov frame consisted of two full rings in the leg, two half-rings in the forefoot and one half-ring in the hindfoot. Basic circular supports on the leg, forefoot, and hindfoot were connected by rods with hinges.

During the treatment, the patient was attended daily by a physiotherapist in our department. The patient

started walking gradually increasing weight-bearing on the right foot on the third day after surgery with or without crutches. Dressings after surgery were changed daily for 3 days, and then weekly. The patient was discharged for outpatient treatment after 8 days. The postoperative period was uncomplicated. The period of fixation of the right foot and ankle with the Ilizarov apparatus on was 56 days.

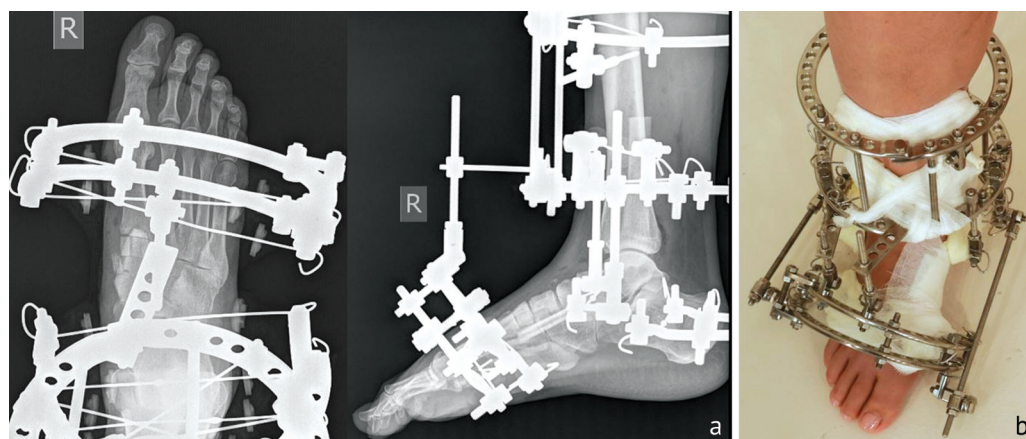


Fig. 6. Treatment: a – X-rays in AP and lateral views; b – photo of the right foot after the operation

RESULTS

Our treatment approach enabled to create favorable conditions for the healing of the defect zone without complications (Fig. 7, 8). One year after the surgery, the patient was satisfied with the result of treatment that provided free painless weight-bearing (Fig. 9). Recurrence was not detected radiologically.

AOFAS score increased significantly from 34 points preoperatively to 92 postoperatively. The ankle range of motion recovered. The muscle strength of the tibialis anterior muscle was assessed as 5 points. Harvesting of the fibular bone graft did not affect the foot position and movements.

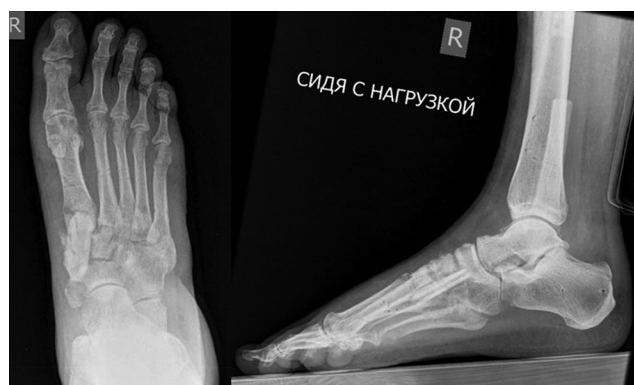

Fig. 7. X-ray pictures of the patient's foot after Ilizarov frame removal (56 days after surgery)

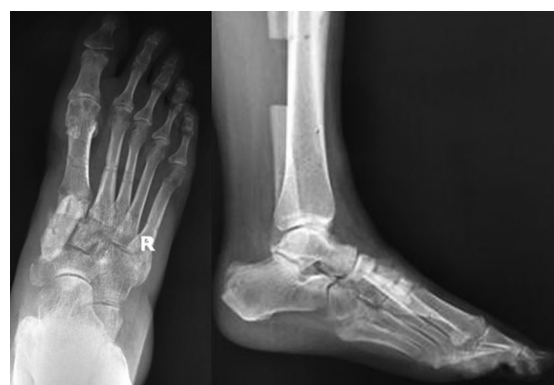

Fig. 8. X-ray pictures of the patient's foot in AP and lateral views 90 days after surgery

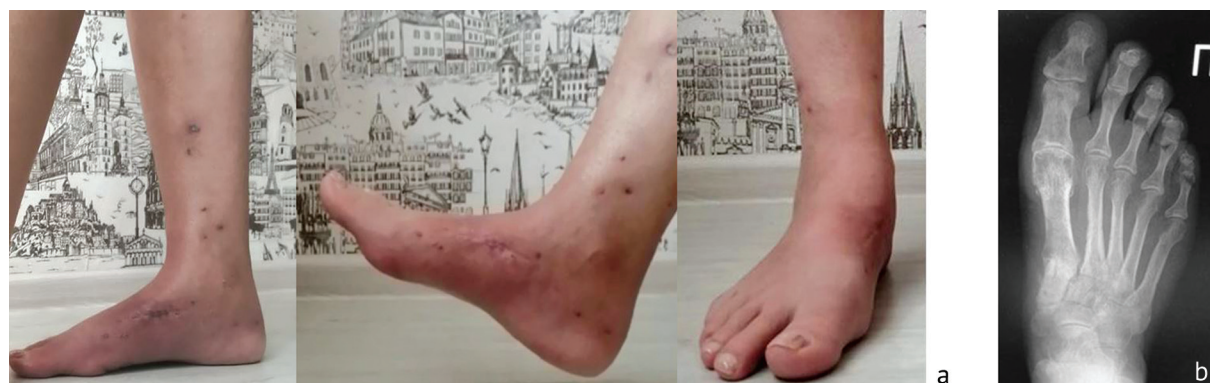

Fig. 9. A year after surgery: a – photos; b – X-ray picture in AP view

DISCUSSION

ABC is a lytic and benign but locally aggressive pseudotumor lesion. This pathology is found in long bones (tibia, femur, pelvis, or humerus) [3].

In the general population, the ABC is more frequent in children and young individuals, is diagnosed more commonly in the second decade of life, and has a male-to-female ratio of 1:1.16 [4]. ABC of the cuneiform foot bones is extremely rare [12]. CT and MRI scans may be helpful in the diagnosis of this lesion.

The optimal treatment of this lesion is still under discussion [11]. Different treatment modalities have been described in the literature: wide resection, intralesional resection such as curettage with or without adjuvants, arterial embolization, intralesional sclerotherapy using polidocanol or the systemic application of denosumab [14].

Due to the rarity of ABC of the foot, only case reports on the surgical treatment were published [1, 5, 6, 12, 15–17]. One study describes a case series treated by percutaneous instillation of polidocanol or intralesional curettage [11].

Once the cyst is removed, the cavity can be packed with either bone-graft, bone cement or other alternatives [16]. At present, biological reconstruction using bone graft seems to be the best option [16].

The adjuvant treatments such as argon beam coagulation, phenol, cryosurgery, and cement have complications such as postoperative fracture, skin necrosis/wound infection, and delayed bone healing [12]. In addition, treatment alternatives such as adjuvant radiotherapy, arterial embolization, and sclerotherapy do not contribute to the structural integrity of the bone and there could be recurrence too [12, 15, 18]. Inadvertent arterial embolization can have devastating effects, and its indications should be scrutinized accordingly [18].

The most preferred treatment option for most ABCs of the foot is curettage with bone grafting. But in our opinion, wide excision (en-block resection) of the lesion like in our ABC case might be preferable with the least chance of recurrence.

The medial cuneiform is an important cornerstone for medial arch continuity and structural integrity, and the risk of a pathological fracture should be considered in the treatment of ABC [12]. Restoring the structure and functions of the midfoot following resection is a challenging task because of its complex anatomy; the tibialis anterior tendon needs to be reattached to avoid functional disability [5]. Fractures and nonunion are common complications of bone grafting [16]. The application of fibular grafts in the reconstruction of bone defects caused by trauma, osteomyelitis, or tumor resection is an effective treatment option [19]. The use of the Ilizarov apparatus showed its effectiveness in the challenges of foot surgery [20, 21]. Due to these reasons, we decided to use

a combination technique of Ilizarov external fixation and bone grafting providing an opportunity to start early weight-bearing instead of screw or plate fixation.

Kumar et al used K-wires to secure the graft in position after the excision of an ABC lesion of the medial cuneiform [5]. Bingol et al described compression screw fixation in the case of medial cuneiform ABC [12]. In our case, we used the Ilizarov original frame. This technique has not been published earlier in literature.

High recurrence rate was reported for ABC [3, 11], the incidence might be 10 percent and higher [11, 22, 23]. Deventer et al showed a local recurrence in 60 % of the curettage subgroup of patients and the disease after sequential instillations of polidocanol in the instillation subgroup persisted in 40 % [11]. It is important to note that no patient, out of the total five treated with polidocanol, could be managed with a single injection alone. The authors concluded that the less invasive character of the instillation justifies it as primary attempt of therapy.

Chowdhry described a local recurrence rate of 21 % after intralesional curettage in 14 patients with foot ABC [22].

Mankin et al in their review of 150 ABC cases treated with curettage and packing with bone grafting or polymethylmethacrylate, found a recurrence rate of 22 % [23].

Garg et al [24] and Dormans et al [25] described a reduction of local recurrence by the use of a high speed burr, phenol, and intralesional curettage of primary ABC in children and adolescents.

Complications associated with transosseous osteosynthesis and external fixation in foot and ankle surgery were reported by many authors [26, 27]. No complications related to vessels and nerves, and wire/pin-site infection were observed during and after our treatment, using Ilizarov external fixation.

Harvesting of the fibular bone graft might result in complications, including painful neuromas, vascular injury, long-lasting ankle pain, nerve injury, and ankle instability [19]. In our clinical case, harvesting of the fibular bone graft did not affect position and movements of the treated foot, did not cause pain and neurological problems.

The procedure of tibialis anterior tendon transfer can have complications such as re-rupture, loss of strength, instability by walking, gait disturbance with forefoot drop, and weak dorsiflexion of the ankle [12]. In our ABC case of an adult patient, we applied the Ilizarov original apparatus to create favorable conditions for healing the foot bone defect and reattached the tibialis anterior tendon with stable fixation and the possibility of early weight-bearing. The patient maintained a full range of motion in the ankle joint without pain and excellent muscle strength of the tibialis anterior at the final follow-up.

CONCLUSION

The combination of Ilizarov external fixation and bone grafting provided favorable conditions for the healing of foot bone defect due to ABC without any complications,

patient's mobility and early weight-bearing. Our approach in the management of foot ABC should be considered as a treatment option in similar cases.

Conflict of interest All authors declare no conflict of interest.

Funding The authors received no financial support for the research and/or authorship of this article.

Ethics approval The study was performed in accordance with the ethical standards of the Declaration of Helsinki (revised in October 2013) and was approved by the ethics committee of the Ilizarov Center.

Informed consent The patient has provided informed consent for the case report to be published.

REFERENCES

- Shang J, Guo R, Zhan P, et al. Aneurysmal bone cyst of the metatarsal: A case report. *Oncol Lett.* 2016;12(4):2769-2771. doi: 10.3892/ol.2016.5007
- Biesecker JL, Marcove RC, Huvos AG, Miké V. Aneurysmal bone cysts. A clinicopathologic study of 66 cases. *Cancer.* 1970;26(3):615-625. doi: 10.1002/1097-0142(197009)26:3<615::aid-cnrcr2820260319>3.0.co;2-i
- Restrepo R, Zahrah D, Pelaez L, et al. Update on aneurysmal bone cyst: pathophysiology, histology, imaging and treatment. *Pediatr Radiol.* 2022;52(9):1601-1614. doi: 10.1007/s00247-022-05396-6
- Leithner A, Windhager R, Lang S, et al. Aneurysmal bone cyst. A population based epidemiologic study and literature review. *Clin Orthop Relat Res.* 1999;(363):176-179.
- Kumar VS, Jalan D, Khan SA, Mridha AR. Aneurysmal bone cyst of medial cuneiform and a novel surgical technique for mid-foot reconstruction. *BMJ Case Rep.* 2014;2014:bcr2013201709. doi: 10.1136/bcr-2013-201709
- Iltar S, Alemdaroglu KB, Karalezli N, et al. A case of an aneurysmal bone cyst of a metatarsal: review of the differential diagnosis and treatment options. *J Foot Ankle Surg.* 2009;48(1):74-79. doi: 10.1053/j.jfas.2008.10.001
- Capanna R, Bettelli G, Biagini R, et al. Aneurysmal cysts of long bones. *Ital J Orthop Traumatol.* 1985;11(4):409-417.
- Campanacci M, Capanna R, Picci P. Unicameral and aneurysmal bone cysts. *Clin Orthop Relat Res.* 1986;(204):25-36.
- Dabska M, Buraczewski J. Aneurysmal bone cyst. Pathology, clinical course and radiologic appearances. *Cancer.* 1969;23(2):371-89. doi: 10.1002/1097-0142(196902)23:2<371::aid-cnrcr2820230213>3.0.co;2-2
- Enneking WF. A system of staging musculoskeletal neoplasms. *Clin Orthop Relat Res.* 1986;(204):9-24.
- Deventer N, Toporowski G, Gosheger G, et al. Aneurysmal bone cyst of the foot: A series of 10 cases. *Foot Ankle Surg.* 2022;28(2):276-280. doi: 10.1016/j.fas.2021.03.002
- Bingol O, Ozdemir G, Yasar NE, Devci A. Aneurysmal Bone Cyst of the Medial Cuneiform: A Case Report. *J Am Podiatr Med Assoc.* 2021;111(1):Article_12. doi: 10.7547/20-011
- Kitaoka HB, Alexander IJ, Adelaar RS, et al. Clinical rating systems for the ankle-hindfoot, midfoot, hallux, and lesser toes. *Foot Ankle Int.* 1994;15(7):349-353. doi: 10.1177/10711007940150070
- Tsagozis P, Brosjö O. Current Strategies for the Treatment of Aneurysmal Bone Cysts. *Orthop Rev (Pavia).* 2015;7(4):6182. doi: 10.4081/or.2015.6182
- Günay B, Ustabasıoğlu FE, Çiftçideміr M, et al. Local Recurrence of Metatarsal Aneurysmal Bone Cyst after Percutaneous Sclerotherapy. *Balkan Med J.* 2022;39(6):448-449. doi: 10.4274/balkanmedj.galenos.2022.2022-9-104
- Lui TH. Endoscopically and Fluoroscopically Assisted Curettage and Bone Grafting of the Navicular Bone Cyst. *Arthrosc Tech.* 2016;5(6):e1221-e1227. doi: 10.1016/j.eats.2016.07.016
- Tripathy S, Varghese P, Panigrahi S, Karaniveed Puthiyapura L. Medial malleolar osteotomy for intralesional curettage and bone grafting of primary aneurysmal bone cyst of the talus. *BMJ Case Rep.* 2021;14(5):e242452. doi: 10.1136/bcr-2021-242452
- Park HY, Yang SK, Sheppard WL, et al. Current management of aneurysmal bone cysts. *Curr Rev Musculoskelet Med.* 2016;9(4):435-444. doi: 10.1007/s12178-016-9371-6
- Liu S, Tao S, Tan J, et al. Long-term follow-up of fibular graft for the reconstruction of bone defects. *Medicine (Baltimore).* 2018;97(40):e12605. doi: 10.1097/MD.00000000000012605
- Leonchuk SS, Neretin AS, Blanchard AJ. Cleft foot: A case report and review of literature. *World J Orthop.* 2020;11(2):129-136. doi: 10.5312/wjo.v11.i2.129
- Lascombes P, Popkov DA, Leonchuk SS. Reconstructive surgery in recurrent deformity (clubfoot relapse). *Genij Ortopedii,* 2021;27(4):435-440. doi: 10.18019/1028-4427-2021-27-4-435-440
- Chowdhry M, Chandrasekar CR, Mohammed R, Grimer RJ. Curettage of aneurysmal bone cysts of the feet. *Foot Ankle Int.* 2010;31(2):131-135. doi: 10.3113/FAI.2010.0131
- Mankin HJ, Hornicek FJ, Ortiz-Cruz E, ET AL. Aneurysmal bone cyst: a review of 150 patients. *J Clin Oncol.* 2005;23(27):6756-6762. doi: 10.1200/JCO.2005.15.255
- Garg S, Mehta S, Dormans JP. Modern surgical treatment of primary aneurysmal bone cyst of the spine in children and adolescents. *J Pediatr Orthop.* 2005;25(3):387-392. doi: 10.1097/01.bpo.0000152910.16045.ee
- Dormans JP, Hanna BG, Johnston DR, Khurana JS. Surgical treatment and recurrence rate of aneurysmal bone cysts in children. *Clin Orthop Relat Res.* 2004;(421):205-211. doi: 10.1097/01.blo.0000126336.46604.e1
- Dayton P, Feilmeier M, Thompson M, ET AL. Comparison of Complications for Internal and External Fixation for Charcot Reconstruction: A Systematic Review. *J Foot Ankle Surg.* 2015;54(6):1072-5. doi: 10.1053/j.jfas.2015.06.003
- Dabash S, Potter E, Catlett G, McGarvey W. Taylor Spatial Frame in Treatment of Equinus Deformity. *Strategies Trauma Limb Reconstr.* 2020;15(1):28-33. doi: 10.5005/jp-journals-10080-1452

The article was submitted 15.09.2023; approved after reviewing 25.09.2023; accepted for publication 01.10.2023.

Статья поступила в редакцию 15.09.2023; одобрена после рецензирования 25.09.2023; принята к публикации 01.10.2023.

Information about the authors:

- Sergey S. Leonchuk – MD, PhD, Head of Department, leon4yk@mail.ru, <https://orcid.org/0000-0003-0883-9663>;
- Tiwari Punit – MS (Orthopaedics), Associate Professor, punit_tiwari28@yahoo.com, <https://orcid.org/0000-0002-4174-8344>.

Информация об авторах:

- Сергей Сергеевич Леончук – кандидат медицинских наук, заведующий отделением, leon4yk@mail.ru, <https://orcid.org/0000-0003-0883-9663>;
- Tiwari Punit – магистр ортопедии, доцент, punit_tiwari28@yahoo.com, <https://orcid.org/0000-0002-4174-8344>.

Contribution of the authors:

Leonchuk S.S. – preparation, creation and/or presentation of the published work, specifically writing the initial draft (including substantive translation); preparation, creation and/or presentation of the published work, specifically visualization/ data presentation.

Punit T. – preparation, creation and/or presentation of the published work by those from the original research group, specifically critical review, commentary or revision – including pre-or postpublication stages.

Вклад авторов:

Леончук С.С. – подготовка и написание первоначального проекта (черновика) работы; подготовка, создание и представление работы к публикации, в частности, визуализация/презентация данных.

Punit T. – внесение корректировки в первоначальный вариант, подготовка работы к публикации.