

Genij Ortopedii. 2022. Vol. 28, no. 5. P. 636-642.

Гений ортопедии. 2022. Т. 28, № 5. С. 636-642.

<https://doi.org/10.18019/1028-4427-2022-28-5-636-642>

## Original article

**Analysis of the results of surgical and conservative treatment of humeral condyle fractures**Dmitry S. Nosivets<sup>1✉</sup>, Aleksey A. Vinnik<sup>2</sup><sup>1,2</sup> Oles Honchar Dnipro National University, Dnipro, Ukraine<sup>✉</sup> dsnosivets@yahoo.com, <https://orcid.org/0000-0001-9954-6027><sup>2</sup> aleks.vinnik@gmail.com, <https://orcid.org/0000-0001-9412-7093>**Abstract**

**Introduction** Fractures of the humeral condyle make up 0.5-5.0 % of all fractures and about 30.0 % of adult elbow fractures. Complications develop in 18.0-85.0 % of cases and 29.9 % of the injured have signs of disability, giving these fractures a reputation of injuries with a poor prognosis for functional recovery. **Objective** To improve the treatment results of the injured with humeral condyle fractures by developing differential treatment tactics taking into account the biomechanical characteristics of the injured anatomical structures. **Material and methods** The authors analyzed the results of conservative and surgical treatment of 194 patients with fractures of the humeral condyle. The average age of the patients was 50.2 years (range from 19 to 89 years); there were 75 (38.7 %) males and 119 (61.3 %) females. Based on the method of treatment, the patients were divided into 2 groups, each group included a control subgroup and the results of treatment were analyzed. The main subgroup of the clinical group 1 (surgical treatment) consisted of 99 patients with an average age of 49.1 years (range from 19 to 85 years). There were 49 (49.5 %) men and 50 (50.5 %) women. The control subgroup of the clinical group 1 (surgical treatment) consisted of 41 patients with an average age of 51.4 years (from 21 to 89 years). There were 17 (41.5 %) men and 24 (58.5 %) women. The main subgroup of the clinical group 2 (conservative treatment) consisted of 29 patients with an average age of 51.2 years (from 21 to 88 years). There were 5 (17.2 %) men and 24 (82.8 %) women. The control subgroup of the clinical group 2 (conservative treatment) consisted of 25 patients with an average age of 52.9 years (from 21 to 87 years). There were 4 (16.0 %) men and 21 (84.5 %) women. The fractures were rated according to the AO classification: type 13A – 15 (7.7 %) individuals, type 13B – 40 (20.7 %) subjects and type 13C – 139 (71.6 %) patients. **Results** The mean duration of follow-up was 39.0 ± 1.0 months (7 to 48 months from injury). The mean range of motion in the elbow joint was 110.5 ± 1.2° (50° to 140°), the mean score on the Mayo clinic scale was 81.7 ± 0.9 (45 to 100), and on the Score Scale was 62.7 ± 0.7 (38 to 76). Excellent functional results were obtained in 95 (49.0 %) patients (p < 0.001), good – in 41 (21.2 %) (p < 0.001), fair – in 28 (14.4 %) (p < 0.001) and poor – in 30 (15.5 %) patients (p < 0.001). **Conclusion** Differentiated treatment tactics in humeral condyle fractures permitted to obtain positive results in 92.2 % (p < 0.001) of the patients in comparison with 89.4 % (p < 0.001) of the control group and to decrease the number of complications by 20.2 % (p < 0.001).

**Keywords:** humeral condyle, fracture, elbow joint, conservative and surgical treatment methods**For citation:** Nosivets D.S., Vinnik A.A. Analysis of the results of surgical and conservative treatment of humeral condyle fractures. *Genij Ortopedii*, 2022, vol. 28, no. 5, pp. 636-642. DOI: 10.18019/1028-4427-2022-28-5-636-642.

## Научная статья

УДК 616.717.46-001.5-08

**Анализ результатов оперативного и консервативного лечения переломов мыщелка плечевой кости**Дмитрий Сергеевич Носивец<sup>1✉</sup>, Алексей Александрович Винник<sup>2</sup><sup>1,2</sup> Днепропетровский национальный университет им. О. Гончара, Днепр, Украина<sup>✉</sup> dsnosivets@yahoo.com, <https://orcid.org/0000-0001-9954-6027><sup>2</sup> aleks.vinnik@gmail.com, <https://orcid.org/0000-0001-9412-7093>**Аннотация**

**Введение.** Переломы мыщелка плечевой кости составляют 0,5-5,0 % всех переломов и около 30,0 % переломов в области локтевого сустава у взрослых. Осложнения и неудовлетворительные результаты лечения развиваются в 18,0-85,0 % случаев, а 29,9 % потерпевших имеют признаки инвалидности, что создает данным переломам репутацию повреждений с плохим прогнозом для восстановления функции. **Цель.** Улучшить результаты лечения пострадавших с переломами мыщелка плечевой кости путем разработки дифференцированной тактики с учетом биомеханических характеристик поврежденных анатомических структур. **Материалы и методы.** Авторами проанализированы результаты консервативного и оперативного лечения 194 пострадавших с переломами мыщелка плечевой кости. Средний возраст пациентов составил 50,2 года (от 19 до 89 лет), мужчин – 75 (38,7 %), женщин – 119 (61,3 %). В зависимости от способа лечения пациенты разделены на 2 группы, в каждой из которых выделена контрольная подгруппа и проведен анализ результатов лечения. Основную подгруппу I клинической группы (оперативное лечение) составили 99 больных, средний возраст которых был 49,1 года (от 19 до 85 лет). Мужчин было 49 (49,5 %), женщин – 50 (50,5 %). Контрольную подгруппу I клинической группы (оперативное лечение) составил 41 пациент со средним возрастом 51,4 года (от 21 до 89 лет). Мужчин было 17 (41,5 %), женщин – 24 (58,5 %). Основную подгруппу II клинической группы (консервативное лечение) составили 29 больных, средний возраст которых был 51,2 года (от 21 до 88 лет). Мужчин было 5 (17,2 %), женщин – 24 (82,8 %). Контрольную подгруппу II клинической группы (консервативное лечение) составили 25 больных, средний возраст которых был 52,9 года (от 21 до 87 лет). Мужчин было 4 (16,0 %), женщин – 21 (84,5 %). Переломы распределены согласно классификация АО: тип 13А – 15 (7,7 %) человек, тип 13В – 40 (20,7 %) и тип 13С – 139 (71,6 %). **Результаты.** Средняя длительность диспансерного наблюдения составила 39,0 ± 1,0 месяц (от 7 до 48 месяцев с момента травмы). Средняя амплитуда активных движений в локтевом суставе составила 110,5 ± 1,2° (от 50° до 140°), средний балл по шкале клиники Мейо – 81,7 ± 0,9 (от 45 до 100) и шкале балльной оценки – 62,7 ± 0,7 (от 38 до 76). Отличные функциональные результаты получены у 95 (49,0 %) больных (p < 0,001), хорошие – у 41 (21,2 %) (p < 0,001), удовлетворительные – у 28 (14,4 %) (p < 0,001) и неудовлетворительные – у 30 (15,5 %) больных (p < 0,001). **Выводы.** Дифференцированная тактика лечения переломов мыщелка плечевой кости позволила получить положительные результаты у 92,2 % (p < 0,001) пострадавших по сравнению с 89,4 % (p < 0,001) контрольной группы и на 20,2 % (p < 0,001) снизить количество осложнений.

**Ключевые слова:** мыщелок плечевой кости, перелом, локтевой сустав, консервативные и оперативные способы лечения**Для цитирования:** Носивец Д.С., Винник А.А. Анализ результатов оперативного и консервативного лечения переломов мыщелка плечевой кости // Гений ортопедии. 2022. Т. 28, № 5. С. 636-642. DOI: 10.18019/1028-4427-2022-28-5-636-642. EDN QVBSKV.

## INTRODUCTION

Fractures of the humeral condyle (HC) are common in all age groups and account for 0.5-5.0 % of musculoskeletal fractures and about 30.0 % of fractures in the elbow joint (EJ). At the same time, intraarticular fractures of the HC were reported in 10.0-24.0 % of all intraarticular injuries in adults [1-5].

Treatment of HC fractures is aimed at anatomical restoration of the damaged segment in order to recover the adequate function of the EJ necessary for daily life activity of the patient, which is characterized by the value of the Morrey range of motion of 100° [6].

The numerous ways of operative and conservative treatment developed for HC fractures indicate the search for optimal treatment tactics. Conservative methods of treatment for HC fractures may result in contractures of the EJ and cause treatment complications if used unreasonably and incorrectly. Surgical treatment is used for comminuted fractures, displaced fractures, and intraarticular fractures. The surgical treatment of HC fractures has been based on the principles proposed by the AO group [7-11].

Currently, there are various designs and approaches for stable-functional osteosynthesis using plates, screws, wires, pins, and external fixation devices (EFD). This fact indicates that there are unresolved issues of stable fixation

of fracture fragments and early mobilization of the EJ. At present, the predominant methods of surgical treatment are those of the AO group associated with open reduction and the use of plates and screws for osteosynthesis, as well as methods of external fixation with the use of EFD [12-16].

To date, the problem of surgical and conservative treatment of HC fractures cannot be considered solved, since the disability rate due to these injuries ranges from 5.8 % to 45.8 % [17, 18]. Complications of HC fractures are caused by the intraarticular localization of the fracture and damage to the surrounding structures. Contractures of the EJ, paraarticular ossifications, and pseudarthrosis predominate among the causes of disability [19-23].

All of the above indicates the relevance of this problem and confirms the need to improve the results of treatment of patients with HC fractures, which can be achieved by improving the existing techniques of osteosynthesis and restorative treatment by studying the biomechanical characteristics and optimizing osteosynthesis techniques.

**Objective** To improve the treatment results of the injured with humeral condyle fractures by developing differential treatment tactics taking into account the biomechanical characteristics of the injured anatomical structures.

## MATERIALS AND METHODS

The study was carried out in accordance with the ethical principles presented by the World Medical Association Declaration of Helsinki, 1964, as amended in 2011, and the study was approved by the local bioethics committee (Bioethics Commission of Oles Honchar Dnipro National University, protocol No. 9 of 15.09.2021). Informed consent was obtained from all patients included in the study.

The study analyzed the results of treatment of 194 patients with closed fractures of the humeral condyle with an average age of 50.2 years (from 19 to 89 years). There were 75 (38.7 %) men and 119 (61.3 %) women (Table 1).

Depending on the method of treatment, patients were divided into two clinical groups – I surgical and II conservative treatment. Each group of clinical observation consisted of a main and control subgroup (Fig. 1).

Table 1

Distribution of patients by gender and age

Gender		Age								Total (n, %)
		up to 20 years	21-30	31-40	41-50	51-60	61-70	71-80	over 80 years old	
Males	n	0	22	16	11	13	6	4	3	75
	%	0.0 %	29.3 %	21.3 %	14.7 %	17.3 %	8.0 %	5.3 %	4.0 %	38.7 %
Females	n	1	12	17	17	25	20	21	6	119
	%	0.8 %	10.1 %	14.3 %	14.3 %	21.0 %	16.8 %	17.7 %	5.0 %	61.3 %
Total	n	1	34	33	28	38	26	25	9	194
	%	0.5 %	17.5 %	17.0 %	14.4 %	19.6 %	13.4 %	12.9 %	4.7 %	100 %

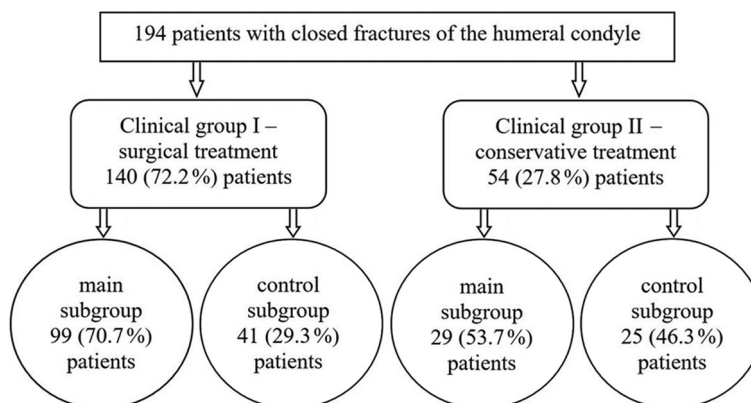


Fig. 1. Division of patients into clinical groups and subgroups depending on the method of treatment of HC fractures

The main subgroup of the I clinical group (surgical treatment) consists of 99 patients with an average age of 49.1 years (from 19 to 85 years). There were 49 (49.5 %) men and 50 (50.5 %) women. The control subgroup of the I clinical group (surgical treatment) consists of 41 patients with an average age of 51.4 years (from 21 to 89 years). There were 17 (41.5 %) men and 24 (58.5 %) women.

The main subgroup of the II clinical group (conservative treatment) consists of 29 patients with an average age of 51.2 years (from 21 to 88 years). There were 5 (17.2 %) men and 24 (82.8 %) women. The control subgroup of the II clinical group (conservative treatment) consists of 25 patients with an average age of 52.9 years (from 21 to 87 years). There were 4 (16.0 %) men and 21 (84.5 %) women.

The AO classification was used to distribute patients according to the type of fracture [14]. There were 15 (7.7 %) patients with extra-articular fractures of type 13A, 40 (20.7 %) with partial intra-articular fractures of type 13B and 139 (71.6 %) with complete intra-articular fractures of type 13C.

Methods of treatment in group I were: osteosynthesis with K-wires in 10 (7.1 %) patients, osteosynthesis with external fixation devices (EFD) in 10 (7.1 %) patients, osteosynthesis with screws in 17 (12.2 %) patients, combined osteosynthesis in 49 (35.0 %) patients and osteosynthesis with plate in 54 (38.6 %) patients. Methods of treatment in group II were: cast immobilization in 43 (79.6 %) patients and continuous skeletal traction in 11 (20.4 %) patients.

To solve our objective, six models of fractures were created to study stresses in various types of fractures (Fig. 2).

Then we performed mathematical modeling of the stress-strain state of the humerus when fixing fractures

in the distal third using K-wires, screws, external fixation devices (ring type device, pin fixation), combined osteosynthesis (unilateral rod-type tubular device with a ball hinge at the level of the EJ + plate fixation) [6], and plates. The analysis of the results was performed by a software package that runs on personal computers in the Windows® 10 Pro operating environment and is based on the finite element method (FEM) (Fig. 3).

The modeling of fixation of fracture type 13B1 showed that with screw fixation the tension spread was from 21.3 kPa to 76.6 kPa, with plate – from 21.3 kPa to 71.2 kPa, with external fixation device (ring device) – from 7.1 kPa to 114.0 kPa and with combined osteosynthesis – from 18.7 kPa to 93.5 kPa. The lowest (7.1 kPa) and highest (114.0 kPa) stresses were observed in modeling using the external fixation device (ring device), which is associated with the unloading of the main bone mass and EJ.

The modeling of a 13C1 type fracture fixation showed that the stresses during fixation with screws ranged from 21.3 kPa to 78.3 kPa, with the plate from 21.3 kPa to 75.1 kPa, with the external fixation device (ring device) from 2.3 kPa to 93.9 kPa, and with combined osteosynthesis from 18.7 kPa to 97.2 kPa.

The modeling of fixation of fracture type 13C3 showed that fixation with screws ranged from 21.3 to 87.4 kPa, with the plate from 21.3 to 86.8 kPa, with the external fixation device (ring device) from 2.3 to 91.5 kPa, and with combined osteosynthesis from 18.7 to 95.2 kPa. It was revealed that fixation with the external fixation device (ring device) and the presence of bone fragments at the level of the HC results in loose contact between the fragments, which leads to low stresses (2.3 kPa) as the bone is practically unloaded at EJ level (Fig. 3).

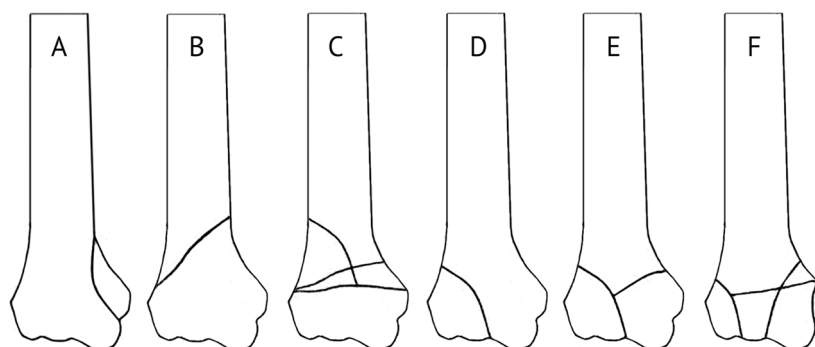


Fig. 2. Models of fractures of the HC in the frontal section according to the classification of the AO group. A – type 13A1; B – type 13A2; C – type 13A3; D – type 13B1; E – type 13C1; F – type 13C3

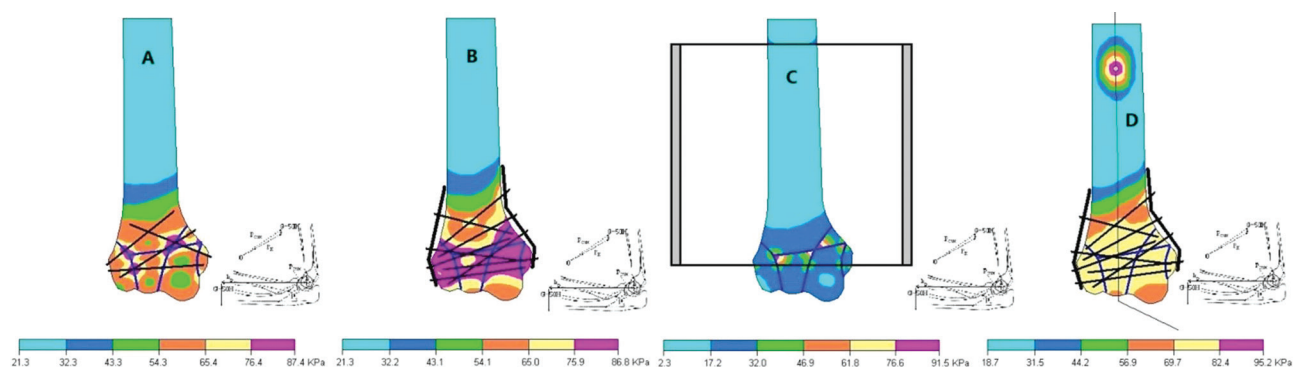


Fig. 3. Stress fields arising during the simulation of fracture fixation type 13C3: A – screws; B – plates; C – external fixation device; D – combined osteosynthesis

To optimize rehabilitation treatment, there are 4 periods of rehabilitation: 1 – preoperative or immobilization period; 2 – the period of early mobilization of EJ; 3 – period of late mobilization of EJ; 4 – period of outpatient rehabilitation treatment. In each period of rehabilitation, an appropriate set of exercise therapy and medical treatment aimed at preventing complications was used [6].

To study the intensity of blood circulation at the level of macro- and microcirculatory systems, the method of rheovasographic examination was used, which was performed in the acute period of injury (the first 3 days) and 1-2-4-6 months after injury.

Analysis of the results of treatment of patients with HC fractures was performed 3, 6, and 9 months after

treatment, and long-term treatment results were evaluated within 1 year or more after treatment. The results of treatment up to 6 months after injury were studied in 185 (95.4 %) patients, and long-term results of treatment more than 1 year after injury were studied in 172 (88.7 %) patients. The average duration of the follow-up period for 194 patients of clinical I and II groups was ( $M \pm m$ )  $39.0 \pm 1.0$  months (from 7 to 48 months from the time of injury). The results of treatment were evaluated on a Score Scale [6] and the Mayo clinic scale [24, 25].

Statistical processing of the study results was performed using biostatistics methods implemented in the software packages Statistica v6.1 (Statsoft Inc., USA, licensed No. AJAR909E415822FA) and MS Excel for Windows®.

## RESULTS

Experimental studies showed that methods of fracture fixation in all fracture models with the use of K-wires, screws, plates, and combined osteosynthesis create a compression force from 54.1 kPa to 86.8 kPa on the main bone mass and on each other. With the use of an external fixation device in the models of complete intraarticular and comminuted fractures, a compression force from 17.0 to 32.0 kPa was created on fractures to the bone mass. The results obtained in the experimental study were used to select the treatment method for 128 (66.0 %) patients in the main subgroups of groups I and II of clinical observation.

At the end of the follow-up period for 194 patients, the mean range of active flexion/extension movements in the EJ was  $110.5 \pm 1.2^\circ$  ( $50^\circ$  to  $140^\circ$ ), the mean score on the Mayo clinic scale was  $81.7 \pm 0.9$  (45 to 100) and the Score Scale was  $62.7 \pm 0.7$  (38 to 76) (Table 2).

Excellent functional results were obtained in 95 (49.0 %) patients, good in 41 (21.2 %), satisfactory in 28 (14.4 %), and poor in 30 (15.5 %) patients (Table 3).

The best results of treatment and a shorter period of disability were in 55 (28.4 %) patients with type 13A and 13B fractures, the worst results of treatment and longer periods of disability were observed in 139 (71.6 %) patients with type 13C fractures, which is due to the nature of the injury and the used treatment methods. Type 13C fractures were characterized by a more severe injury and required

more intensive treatment than type 13A and 13B fractures. Complications were more often observed in patients of the control subgroups, where differentiated treatment approaches were not used. Poor results of treatment were noted in 30 (15.5 %) patients with type 13C fractures and were associated with the development of flexion-extension contractures (the range of motion in the EJ at the end of the follow-up period was less than  $100^\circ$  (from  $50^\circ$  to  $100^\circ$ ), in 5 patients the cause of contracture had heterotopic ossification.

The analysis of rheovasograms performed in the acute period of trauma in patients showed disturbances of regional circulation processes in 100 % of cases ( $p < 0.001$ ). In all patients, qualitative parameters changed equally, what was associated with impaired peripheral circulation due to the trauma. When investigated 1-2-4-6 months after injury, a decrease in asymmetry in the value of pulse blood circulation of the upper extremities was noted. In the patients of the main subgroup, it decreased to  $65.0 \pm 5.6$  %, and the rheovasographic index value increased to  $0.88 \pm 0.08$  Ohm, while in the control subgroup, the same indices were  $50.1 \pm 7.2$  % ( $p > 0.10$ ) and  $0.90 \pm 0.06$  Ohm ( $p > 0.80$ ). However, a comparative analysis of the rheovasographic findings in the patients did not reveal a statistically significant difference in the nature and degree of regional blood flow impairment.

Table 2

Characteristics of the treatment results in patients of clinical groups 1 and 2 ( $M \pm m$ )

Characteristics	Group 1 (n = 140)		Group 2 (n = 54)	
	Main subgroup (n = 99)	Control subgroup (n = 41)	Main subgroup (n = 29)	Control subgroup (n = 25)
Average range of motion, degrees	$116.2 \pm 1.2$	$96.6 \pm 2.5$	$121.7 \pm 2.9$	$98.0 \pm 2.9$
Average duration of rehabilitation treatment, weeks	$8.7 \pm 0.1$	$9.7 \pm 0.4$	$7.7 \pm 0.3$	$10.3 \pm 0.3$
Average duration of disability, weeks	$11.3 \pm 0.3$	$14.3 \pm 0.5$	$8.5 \pm 0.4$	$13.7 \pm 0.4$
Average score on the Mayo scale, points	$84.7 \pm 0.9$	$73.7 \pm 1.3$	$91.4 \pm 2.4$	$71.8 \pm 2.2$
Average score on the Score Scale, points	$64.7 \pm 0.6$	$56.6 \pm 1.2$	$68.9 \pm 1.6$	$57.3 \pm 1.8$

Table 3

Comparative characteristics of treatment results of patients in clinical groups 1 and 2 ( $M \pm m$ )

Results of treatment	Group 1 (n = 140)				Group 2 (n = 54)			
	Main subgroup (n = 99)		Control subgroup (n = 41)		Main subgroup (n = 29)		Control subgroup (n = 25)	
	n	%	n	%	n	%	n	%
Excellent	48	48.5	15	36.6	22	75.9	10	40.0
Good	26	26.3	8	19.5	3	10.3	4	16.0
Satisfactory	15	15.1	6	14.6	3	10.3	4	16.0
Unsatisfactory	10	10.1	12	29.3	1	3.5	7	28.0
Total	99	100	41	100	29	100	25	100



## DISCUSSION

On the basis of comparative characteristics of the treatment results of 194 patients from clinical observation in groups 1 and 2, it has been established that treatment methods involving immobilization of the EJ for more than 4 weeks since the injury require a longer period of rehabilitation, have worse functional results and are associated with a longer period of disability compared with the methods of treatment in which immobilization of the EJ is up to 4 weeks since the injury or operations of stable-function osteosynthesis are performed [6].

However, in the work of Pidhorz L. et al. (2013), the authors concluded that conservative treatment of HC fractures in patients older than 65 years is an exception, but can be used in patients of this age group and provides satisfactory clinical results without the formation of a severe contracture of the EJ or its instability [26]. In our work, the best functional results in patients older than 65 years were obtained with stable-function osteosynthesis and early mobilization of the EJ.

Also, Li H. et al. (2017) studied the effect of functional exercises on the functional state of the EJ in type C distal humerus fractures. The authors concluded that early functional exercises can alleviate pain and improve flexion and extension of the EJ after surgery. EJ fixation at 30° extension is better than flexion at 90° with flexion-extension activity at the elbow [27]. The results obtained by these researchers correlate with our experience in treating victims with HC fractures and indicate the advisability of early mobilization of the EJ after injury and surgery [17, 18].

In our opinion, the work of Chen C. et al. (2021) evaluated the difference in functional outcomes between open type C fractures (Gustilo I/II) and closed distal humerus fractures after open reduction and internal fixation. The authors found that open type C distal humerus fractures can have satisfactory clinical results similar to those of closed distal humerus fractures after open reduction and internal fixation [28]. The results allow for the use of internal osteosynthesis, whereas we use an external fixation device in similar clinical situations.

Yetter T.R. et al. (2021) performed a major systematic review of complications and reoperations in intra-articular fractures of the distal humerus and concluded that complications may be more frequent than described in the current literature. The overall complication rate was 53 % and the overall reoperation rate was 21 %. The authors attribute the results to a higher complication rate with parallel plate fixation than with perpendicular fixation. In our study, the incidence of poor results was 15.5 % and we used only parallel plate fixation during surgical treatment, and the results obtained are most likely related to different postoperative rehabilitation approaches [29].

At the beginning of the current century, methods of combined osteosynthesis for HC fractures began to

appear [2, 6, 11, 12]. Thus, Shuisky A.A. (2022) developed a method of surgical treatment that allows performing osteosynthesis of intra-articular fractures with both moderate and severe displacement, provides conditions for early development of movements, relieving the load from the fracture zone by separating articular surfaces in the articular-distraction device, which significantly reduces patient rehabilitation time and have positive effects on the final results [2].

Kong L. et al. (2021) conducted an investigation using finite element mathematical modeling to study the properties of the original constructs and substantiate the proposed method for fixing fractures of the HC. The authors created a simple model of an intra-articular fracture of the distal humerus (type C1 according to the AO classification) on which the mechanical properties of the double plate were studied. On the basis of the study, it was found that the new double plate showed greater stiffness than the orthogonal double plate [30].

Wei L. et al. (2019) modeled simple intraarticular fractures of the distal humerus based on the three-dimensional structure of the humerus of a healthy person. Two plate configurations were used to fix the models. Stresses, displacements, and stiffness were modeled and calculated in axial compression, rotational torsion, bending torsion, and valgus torsion using the finite element method. The authors concluded that the proposed plate is stronger than the traditional plate and its use is a rational alternative [31].

Hara A. et al. (2019) performed a biomechanical study of a dorsolateral plate and a single 2.7-mm locking screw for type C distal humeral fractures (according to the AO classification). The authors concluded that the transcondylar screw from the dorsolateral plate did not affect the axial compression of the radial column [32].

Thus, the use of mathematical modeling in the study of surgical treatment of HC fractures has an important practical value and is widely used in modern orthopedics and traumatology.

Despite the absence of significant differences in the indices of the Mayo clinic scale and Score Scale before treatment, they were significantly higher in patients who received differentiated treatment approaches ( $p < 0.001$  compared to controls) during the subsequent stages of follow-up [6].

Thus, comparative characteristics of the results of treatment of 194 patients with HC fractures showed significantly better indicators in patients in the main subgroups of groups I and II, which was associated with earlier mobilization of the EJ after injury, a shorter period of rehabilitation treatment, duration of temporary disability and restoration of the physiological range of motion in the EJ as compared to patients in the control subgroups.

## CONCLUSIONS

1. The treatment of humeral condyle fractures is characterized by unsatisfactory results and complications in 18.0-85.0 % of patients and is the cause of disability in 18.0-20.0 % of patients. The most frequent cause of complications is the incorrect choice of the treatment method, technical errors in performing osteosynthesis, and

prolonged immobilization of the elbow joint, which leads to the formation of contractures, ankylosis, and heterotopic ossification.

2. Methods for fixation of humeral condyle fractures using K-wires, screws, plates, and combined structures generate fixation forces between fracture fragments with

the main bone mass and with each other from 54.1 kPa to 86.8 kPa. When using external fixation devices in the models of comminuted fractures and complete intraarticular fractures, forces between the fracture fragments range from 17.2 to 32.0 kPa.

3. Fractures without fragment displacement or with intraarticular fragment displacement up to 2.0 mm and the perspective of consolidation within 3-4 weeks after injury are indications for treatment with the cast immobilization method. The continuous skeletal traction technique for humeral condyle fractures is of limited use and is indicated for supracondylar fractures with displacement when other interventions cannot be performed.

4. The preferred methods of fixation are osteosynthesis with screws, plates, external fixation devices, and combined osteosynthesis. K-wires osteosynthesis is reasonable for non-comminuted fractures of the humeral condyle. External fixation devices are used for non-

articular condyle fractures, supracondylar and intraarticular fractures of the humerus. Osteosynthesis with screws is justified for fractures of the condyles, capitulum fractures, and the humerus block. Plate osteosynthesis and combined osteosynthesis – for comminuted fractures of the humeral condyle with fragment displacement.

5. The biomechanically justified approach to the choice of treatment method and fixation structures in the surgical treatment of humeral condyle fractures allows us to reduce the risk of complications and provides an opportunity to increase the final functional outcome by 19.2 % ( $p < 0.001$ ) compared with the control group.

6. The differentiated tactics of conservative and surgical treatment of fractures of the humeral condyle permitted to obtain positive results in 92.2 % ( $p < 0.001$ ) of patients in comparison with 89.4 % ( $p < 0.001$ ) of the control group and decrease the number of complications by 20.2 % ( $p < 0.001$ ).

#### REFERENCES

1. Zalavras C.G., Papasoulis E. Intra-articular fractures of the distal humerus – a review of the current practice // *Int. Orthop.* 2018. Vol. 42, No 11. P. 2653-2662. DOI: 10.1007/s00264-017-3719-4.
2. Шуйский А.А. Комбинированный остеосинтез внутрисуставных переломов дистального мета-эпифиза плечевой кости: Дис. ... канд. мед. наук. Москва, 2022. 131 с.
3. Кленин А.А. Оперативное лечение эпифизарных переломов дистального отдела плечевой кости и их последствий: Дис. ... канд. мед. наук. Нижний Новгород, 2017. 162 с.
4. Ратев А.П. Лечение повреждений области локтевого сустава: Дис. ... докт. мед. наук. Москва, 2015. 252 с.
5. Морозов Д.С. Лечение внутрисуставных переломов дистального отдела плечевой кости: Дис. ... канд. мед. наук. Москва, 2009. 162 с.
6. Носивец Д.С. Сравнительные характеристики способов лечения переломов дистального мета-эпифиза плечевой кости: Дис. ... канд. мед. наук. Донецк, 2012. 197 с.
7. Some outcomes of patients treated operatively for distal humerus fractures are affected by hand dominance / C.N. Shields, J.R. Johnson, J.M. Haglin, S.R. Konda, K.A. Egol // *Eur. J. Orthop. Surg. Traumatol.* 2021. Vol. 31, No 7. P. 1507-1513. DOI: 10.1007/s00590-021-02915-3.
8. Adolescent distal humerus fractures: ORIF versus CRPP / P. Bell, B.P. Scannell, B.J. Loeffler, B.K. Brighton, R.G. Gaston, V. Casey, M.E. Peters, S. Frick, L. Cannada, K.L. Vanderhave // *J. Pediatr. Orthop.* 2017. Vol. 37, No 8. P. 511-520. DOI: 10.1097/BPO.0000000000000715.
9. Локтевой сустав: учебное пособие. Под ред. К.А. Егизаряна, А.П. Ратева. Москва: ООО «Медицинское Информационное Агентство». 2019. 464 с.
10. Кривенко С.Н. Остеосинтез мелких фрагментов при многооскольчатых переломах дисатального мета-эпифиза плечевой кости // *Гений Ортопедии.* 2018. Т. 24, № 4. С. 436-443. DOI: 10.18019/1028-4427-2018-24-4-436-443.
11. Науменко Л.Ю., Носивец Д.С. Оперативное лечение пациентов с переломами дистального мета-эпифиза плечевой кости методом комбинированного остеосинтеза // *Травматология и Ортопедия России.* 2009. Т. 51, № 1. С. 16-20.
12. Самусенко Д.В., Крылов В.А. Использование комбинированного остеосинтеза при лечении больного с оскольчатый внутрисуставным переломом мыщелка плеча // *Гений Ортопедии.* 2009. № 2. С. 96-98.
13. Швед С.И. Наш многолетний опыт применения чрескостного остеосинтеза в лечении больных с внутри- и околосуставными переломами // *Гений Ортопедии.* 2013. № 2. С. 112-116.
14. Bicolumnar 90-90 plating of AO 13C type fractures / C. Kural, E. Ercin, M. Erkilinc, E. Karaali, M.G. Bilgili, S. Altun // *Acta Orthop. Traumatol. Turc.* 2017. Vol. 51, No 2. P. 128-132. DOI: 10.1016/j.aott.2016.09.003.
15. Lauder A., Richard M.J. Management of distal humerus fractures. *Eur. J. Orthop. Surg. Traumatol.* 2020. Vol. 30, No 5. P. 745-762. DOI: 10.1007/s00590-020-02626-1.
16. Abdoli A., Farhoud A.R., Kamrani R.S. Treatment of distal humerus articular fracture with pin-and-plate technique. *J. Hand Surg. Asian Pac.* Vol. 2020. Vol. 25, No 3. P. 332-339. DOI: 10.1142/S242483552050037X.
17. Науменко Л.Ю., Носивец Д.С. Функциональные результаты консервативных и хирургических способов лечения переломов дистального мета-эпифиза плечевой кости // *Украинский Журнал Экстремальной Медицины им. Г.О. Можаяева.* 2010. Т. 11, № 3. С. 104-110.
18. Носивец Д.С. Результати порівняльної характеристики способів лікування переломів дистального метаепіфіза плечової кістки // *Травма.* 2013. Т. 14, № 5. С. 23-27.
19. Some outcomes of patients treated operatively for distal humerus fractures are affected by hand dominance / C.N. Shields, J.R. Johnson, J.M. Haglin, S.R. Konda, K.A. Egol // *Eur. J. Orthop. Surg. Traumatol.* 2021. Vol. 31, No 7. P. 1507-1513. DOI: 10.1007/s00590-021-02915-3.
20. Мурадян Д.Р. Лечение посттравматических анкилозов и контрактур локтевого сустава с применением шарнирно-дистракционных аппаратов (ошибки и осложнения): Дис. ... канд. мед. наук. Москва, 2009. С. 114.
21. Джумабеков С.А., Борукеев А.К. Ошибки и осложнения при лечении переломов дистального отдела плечевой кости // *Успехи Науки и Образования.* 2016. Т. 10, № 11. С. 59-60.
22. Реабилитация пациентов после оперативного лечения переломов дистального конца плеча / Е.И. Солод, А.Ф. Лазарев, Я.Г. Гудушаури, Е.Г. Ермолаев, М.Х. Джанибеков // *Врач-аспирант.* 2016. Т. 77, № 4. С. 30-36.
23. Чибиров Г.М., Солдатов Ю.П. Оперативное лечение больных с последствиями травм локтевого сустава с применением аппарата Илизарова // *Современные Проблемы Науки и Образования.* 2015. № 5. С. 85.
24. Functional outcome of extra-articular distal humerus fracture fixation using a single locking plate: A retrospective study / V. Trikha, P. Agrawal, S. Das, S. Gaba, A. Kumar // *J. Orthop. Surg. (Hong Kong).* 2017. Vol. 25, No 3. 2309499017727948. DOI: 10.1177/2309499017727948.
25. Gupta A.K., Samal B.P., Dalei T.R. Functional and radiological outcome in distal third humerus fracture treated with extra-articular locking plate: a multicentric retrospective study // *J. Pharm. Bioallied Sci.* 2021, Vol. 13, No Suppl. 2. P. 1483-1487. DOI: 10.4103/jpbs.jpbs\_263\_21.
26. Distal humerus fracture in the elderly: does conservative treatment still have a role? / L. Pidhorz, P. Alligand-Perrin, E. De Keating, T. Fabre, P. Mansat; Société Française de Chirurgie Orthopédique et Traumatologie (SoFCOT) // *Orthop. Traumatol. Surg. Res.* 2013. Vol. 99, No 8. P. 903-907. DOI: 10.1016/j.otsr.2013.10.001.

27. Effect of functional exercise at different time and different immobilization positions on functional recovery of elbow joint with type C distal humeral fractures / H. Li, Y. Wang, Z. Che, Y. Gou, L. Xu, B. Lu // Zhongguo Xiu Fu Chong Jian Wai Ke Za Zhi. 2017. Vol. 31, No 8. P. 946-951. doi:10.7507/1002-1892.201701021.
28. Comparative study of functional outcomes between OTA/AO type C, Gustilo type I/II open fractures and closed fractures of the distal humerus treated by open reduction and internal fixation / C. Chen, D. Xiao, T. Li, M. Gong, Y. Zha, K. Hua, W. Sun, S. Ji, X. Jiang // BMC Musculoskelet. Disord. 2021. Vol. 22, No 1. P. 939. DOI: 10.1186/s12891-021-04817-1.
29. Yetter T.R., Weatherby P.J., Somerson J.S. Complications of articular distal humeral fracture fixation: a systematic review and meta-analysis // J. Shoulder Elbow Surg. 2021. Vol. 30, No 8. P. 1957-1967. DOI: 10.1016/j.jse.2021.02.017.
30. Biomechanical properties of a novel fixation system for intra-articular distal humerus fractures: a finite element analysis / L. Kong, Y. Wang, Q. Lu, Y. Han, F. Wang // J. Orthop. Surg. Res. 2021. Vol. 16, No 1. P. 674. DOI: 10.1186/s13018-021-02836-1.
31. Wei L., Ling M., An Z. Biomechanical analysis of a novel plating for intra-articular distal humerus fractures: combined anteromedial and anterolateral plating // J. Orthop. Surg. Res. 2019. Vol. 14, No 1. P. 132. DOI: 10.1186/s13018-019-1181-2.
32. Biomechanical evaluation of a transcondylar screw from the dorsolateral plate support on the stabilization of orthogonal plate configuration in distal humeral fracture / A. Hara, T. Kudo, S. Ichihara, H. Iwase, M. Nagao, Y. Maruyama, K. Kaneko // Injury. 2019. Vol. 50, No 2. P. 256-262. DOI: 10.1016/j.injury.2018.12.017.

The article was submitted 02.02.2022; approved after reviewing 11.05.2022; accepted for publication 30.08.2022.

Статья поступила в редакцию 02.02.2022; одобрена после рецензирования 11.05.2022; принята к публикации 30.08.2022.

#### Information about the authors:

1. Dmitry S. Nosivets – Doctor of Medical Sciences, Assistant Professor, Scopus Author ID: 57210982456;
2. Aleksey A. Vinnik – Candidate of Medical Sciences, Assistant Professor.

#### Информация об авторах:

1. Дмитрий Сергеевич Носивец – доктор медицинских наук, доцент, Scopus Author ID: 57210982456;
2. Алексей Александрович Винник – кандидат медицинских наук, доцент.

**Conflict of interests:** *there is no conflict of interests.*

**Source of funding:** *the study was conducted without sponsorship.*