

**Experimental and clinical studies on the reduction of bone lengthening terms at the Ilizarov Center**A.V. Popkov<sup>✉</sup>, D.A. Popkov, E.N. Gorbach, N.A. Kononovich, A.A. Antonov

Ilizarov National Medical Research Centre for Traumatology and Orthopedics, Kurgan, Russian Federation

**Corresponding author:** Arnold V. Popkov, [apopkov.46@mail.ru](mailto:apopkov.46@mail.ru)**Abstract**

**Introduction** The list of pathological conditions that need surgical correction of bone length is very long. In the literature on the topic under discussion, it is reported that the best results are obtained by lengthening according to the Ilizarov method. But many surgeons are not satisfied with the long duration of external fixation, which requires a large number of adjustments and patient compliance. **The aim** of this work is a analysis of the modern technologies for limb lengthening that actually shorten the time of osteosynthesis using the apparatus for external fixation. **Materials and methods** Literary sources have been analyzed since the first publication on limb lengthening according to Ilizarov in 1963. The search was carried out in the databases of the RSCI, NCBI Pubmed, Medline. The developments of the employees of the Ilizarov Center are presented. **Results** An analysis of the literature showed that the fixation units of the apparatus, units for providing movement for distraction, compression and correction of angles have been improved. The invasiveness of the surgical intervention is minimized. Best results can be obtained using automatic lengthening. The Ilizarov Center has developed and experimentally proven methods for reducing the period of distraction and the period of fixation with the apparatus. We combined three factors: an increased round-the-clock distraction rate (2 or 3 mm) with a motorized distractor adjusted to the Ilizarov frame and fixation reinforcement along with regeneration stimulation with HA-coated intramedullary wires in our experimental and clinical trials. This technology has easily conquered a number of clinical practices in Russia, France and Serbia. **Conclusion** Experimental and clinical substantiation of a two- or three-fold increase in the rate of automated distraction in the conditions of intramedullary reinforcement with a bioactive implant can drastically reduce not only the time of the distraction period, but also the duration of the fixation period with the Ilizarov apparatus.

**Keywords:** Ilizarov apparatus, distraction osteogenesis, osteosynthesis, automated distractor, hydroxyapatite coating**For citation:** Popkov A.V., Popkov D.A., Gorbach E.N., Kononovich N.A., Antonov A.A. Experimental and clinical studies on the reduction of bone lengthening terms at the Ilizarov Center. Genij Ortopedii, 2022, vol. 28, no 4, pp. 584-591. DOI: 10.18019/1028-4427-2022-28-4-584-591.**Обзорная статья**

УДК 616.71-089.818.3-001.5-089.227.84-092.6(048.8)

**Экспериментальные и клинические исследования по сокращению сроков удлинения костей в Центре Илизарова**A.B. Попков<sup>✉</sup>, Д.А. Попков, Е.Н. Горбач, Н.А. Кононович, А.А. Антонов

Национальный медицинский исследовательский центр травматологии и ортопедии имени академика Г.А. Илизарова, Курган, Россия

**Автор, ответственный за переписку:** Арнольд Васильевич Попков, [apopkov.46@mail.ru](mailto:apopkov.46@mail.ru)**Аннотация**

**Введение.** Перечень патологических состояний, при которых требуется хирургическая коррекция длины кости, очень велик. В литературе по обсуждаемой теме сообщается, что наилучшие результаты дает удлинение по методу Илизарова. Но многих хирургов не устраивает значительная продолжительность внешней фиксации, необходимость большого количества коррективов и комплаентности пациента. **Цель.** Анализ современных технологий удлинения конечностей, реально сокращающих время остеосинтеза аппаратом внешней фиксации. **Материалы и методы.** Проанализированы литературные источники с момента первой публикации об удлинении конечностей по Илизарову в 1963 г. Поиск осуществлялся в базах данных РИНЦ, NCBI Pubmed, Medline. Представлены разработки сотрудников Центра Илизарова. **Результаты.** Анализ литературы показал, что усовершенствованы узлы фиксации аппарата, узлы обеспечения движения для distraction, компрессии и коррекции углов. Инвазивность оперативного вмешательства сведена к минимуму. Наилучшие результаты можно получить, используя автоматическое удлинение. В Центре Илизарова разработаны и экспериментально доказаны методологические подходы для сокращения периода distraction и периода фиксации аппаратом. В экспериментальных и клинических исследованиях объединены три фактора: повышенная круглосуточная скорость distraction (2 или 3 мм) с помощью моторизованного дистрактора, смонтированного на аппарате Илизарова, и усиление жесткости фиксации вместе со стимуляцией регенерации интрамедуллярными спицами с гидроксиапатитным покрытием. Эта технология в настоящее время активно применяется в клинической практике в России, Франции и Сербии. **Выводы.** Экспериментально-клиническое обоснование двукратного или трехкратного увеличения скорости автоматизированной distraction в условиях интрамедуллярного армирования биоактивным имплантатом позволяет значительно сократить не только время distractionного периода, но и продолжительность периода фиксации при использовании аппарата Илизарова.

**Ключевые слова:** аппарат Илизарова, distractionный остеогенез, остеосинтез, автоматический дистрактор, гидроксиапатитное покрытие**Для цитирования:** Experimental and clinical studies on the reduction of bone lengthening terms at the Ilizarov Center / A.V. Popkov, D.A. Popkov, E.N. Gorbach, N.A. Kononovich, A.A. Antonov // Гений ортопедии. 2022. Т. 28, № 4. С. 584-591. DOI: 10.18019/1028-4427-2022-28-4-584-591. EDN VVTPKM.**INTRODUCTION**

Distraction osteogenesis developed by G.A. Ilizarov is a unique method of bone tissue bioengineering due to its ability to generate vascularized bone tissue *in vivo* that features the micro – and macrostructure of the native bone. Moreover, the surrounding soft tissues simultaneously undergo regeneration and stretching due to tension stress [1–5]. The successful evolution of the distraction osteogenesis techniques resulted in creation of a number of methods for management of various orthopaedic

pathologies such as bone shortening in the upper and lower extremities, bone defects and bone deformities.

The Ilizarov method for correction of limb length discrepancy (LLD) remains relevant up to date although new technologies based on distraction osteogenesis have appeared [6–11]. Its main principles are stable osteosynthesis, maximum preservation of the bone marrow osteogenic potential, periosteum and paraosseous tissues, partial corticotomy, optimal rate and rhythm of distraction,

and functional load on the limb during treatment. The list of pathological conditions that need surgical correction of bone length is very long but the main ones are systemic diseases of the skeleton, congenital and post-traumatic bone shortening, and osteomyelitis [11–15].

The literature on the topic under discussion reports that lengthening with the Ilizarov method provides the best results in the treatment of such conditions [6, 16]. However, the expansion of the external fixation practice across the world revealed a number of complications that may lead to poor results [17–22]. The causes of complications are seen primarily in the loss of fixation stability during a long period of osteosynthesis, bone resorption and soft-tissue infection around metal wires and half-pins. Many surgeons, paying tribute to the advantages of the Ilizarov apparatus, are not satisfied with the long duration of external fixation that needs a lot of adjustments and patients' compliance. Significant discomfort and worsened quality of life are important issues [21]. Complications also occur with other limb lengthening technologies [23].

Indeed, according to the reported data, a limb lengthening index of 30 days/cm is considered to be excellent, while 45 days/cm and 60 days/cm are good and satisfactory indices [18, 24]. Eralp L et al reported the mean healing index equal to 1.65 months/cm [25]. The index of lengthening varied from 0.7 to 5.9 months/cm depending on age, etiology, bone segment involved and the magnitude of lengthening in the study of Koczewski P and Shadi M [26]. In our opinion, such a long time of osteosynthesis really increases the likelihood of soft tissue inflammation around the connection elements (ES) of the Ilizarov fixator, wires and half-pins. Thus, during the terms reported, the risk of soft tissue inflammation around the communication elements (CE) of the Ilizarov frame, wires and half-pins, really increases.

Most surgeons, using external fixation devices and G.A. Ilizarov's technology of lengthening, passively monitor the consolidation process and do not set tasks to reduce the time of osteosynthesis. Only at the Ilizarov Center at the end of the 20th century the works appeared aimed at increasing the rate of distraction and osteogenesis stimulation.

The aim of this work is a review of the modern technologies for limb lengthening that actually shorten the time of osteosynthesis using the apparatus for external fixation.

### **Current technologies of Limb Length Lengthening**

Colossal changes have occurred both in the design of the Ilizarov apparatus itself and in the lengthening technology since the first publication on the Ilizarov limb lengthening in 1963 [1, 6, 16, 27]. The fixation units of the apparatus (supports and wires), nodes of providing motion for distraction, compression and angular correction (rods, hinges, beams) have been improved. The surgical intervention invasiveness has been minimized to preserve blood supply to the bone and the functional ability of parosseous tissues [28, 29].

Greater efficiency in surgical limb lengthening was achieved by the technology of round-the-clock high-frequency rate of distraction implemented with the latest version of the automated distractor designed at our

institution (patent for utility model No. 30073 RU by Shevtsov V.I., Burlakov E.V., Nemkov V.A. obtained in 2003). The principal solution to the problem of controlled distraction was the emergence of distractors with an autonomous control program for each node of transport [28]. Attempts to automate the lengthening process were undertaken by other researchers on the basis of plating and external fixation devices, but they have not found wide application in the clinical conditions due to failures and high costs [11]. In recent years, motorized intramedullary nails have been used to lengthen limb segments through distraction osteogenesis [6, 30–32]. This technology features invasiveness of surgical intervention, especially when revising and removing the nail. It is impossible to use it for associated multi-planar deformities. Moreover, it shows low reliability in case of systemic diseases of the skeleton. High costs of the products even for Western Europe are its significant disadvantage.

The Ilizarov Center has accumulated sufficient experience in the design and clinical use of automated distractors [28, 33–35]. The automatic round-the-clock high-frequency mode of limb lengthening is tolerated by patients much easier (almost painlessly) compared to the classical method of lengthening with the Ilizarov apparatus with the daily rate of distraction of 1.0 mm achieved within 10–12 hours of daytime in 4 doses of 0.25 mm. No inflammation of the soft tissues in the area of the wires (more than 90 % of patients), no edema of the elongated limb, no disturbances in sensitivity were observed in the cases of automated distraction. Mild inflammations were stopped by conservative treatment. The patients were more active and increased functional weight-bearing, which undoubtedly had a positive effect on reparative tissue regeneration. All patients achieved the planned amount of segment lengthening while the number of complications decreased.

Moreover, radiological studies established a greater intensity of bone formation in the conditions of automated distraction if 1 mm was achieved daily for 60 increments [33, 34, 36]. On the 10th day of distraction, the first signs of bone regeneration were detected represented by a light shadow filling the distraction gap between the bone fragments. In classical Ilizarov distraction, the same signs were seen two weeks later. Further lengthening revealed a continuous bone regenerate of uniform density formed without the signs of the so-called "regenerate growth zone". It indicates a high reparative bone activity stimulated by automated distraction. The optical bone regenerate density (40–50 % of the one of the diaphysis of the lengthened segment) was maintained the entire period of distraction and reached 90–100 % after 1.5–2 months of the fixation period. The optical density of bone regenerate in the regular mode of distraction reached 70–80 % only after 3 to 4 months of fixation. A study of the quantitative content of minerals showed a higher content of minerals in the distraction regenerate in the conditions of automated distraction compared to the classical one [34, 36].

One of the most important tasks that the patient always sets before the doctor is the reduction of the duration of external fixation and functional rehabilitation. The optimal daily rate and frequency (rhythm) of distraction, which are

one of the basic principles of distraction osteogenesis, may also solve this problem. In the conditions of automated limb lengthening, the external fixation index (from the moment of the operation to the moment of dismantling the Ilizarov apparatus) remains within the excellent level (30 days/cm).

In recent years, we have been paying special attention not only to increasing the rate of distraction, but also to shortening the duration of the fixation period. Fundamental studies of reparative regeneration at the tissue, cellular and molecular levels enabled to propose several ways to accelerate the process of regenerate mineralization in the fixation period. Thus for this purpose, a culture of fetal fibroblasts, blood plasma, and acute phase blood proteins were introduced into the growth zone of the distraction regenerate. Pre-clinical trials of such technologies enabled to achieve the consolidation of bone fragments in 2 or 3 weeks. In clinical practice, a modified blood plasma preparation containing bone growth-regulating factors from the same patient was successfully used. It was harvested in the first week post-surgery and was administered in the fixation period, if consolidation was delayed. Similar results have been obtained by other authors [37]. The method is effective, but needs expensive production means. Promising results were obtained in the studies that investigated the effect of some physical methods on reparative osteogenesis: hyperbaric oxygenation, pulsed ultrasound, mechanical effects [38–45].

Also, active searches are currently underway for effective methods of stimulating distraction osteogenesis with various pharmacological substances of general and local action [46–49].

#### Ways of Accelerating Bone Lengthening Terms in External Fixation

The orthopaedic surgeon practicing distraction osteogenesis divides the entire pro-cess of lengthening procedure into two large periods, the period of distraction or direct lengthening, and the period of fixation, the time of mineralization of the regenerated organic matrix or regenerate consolidation. Our studies convincingly prove that a fundamental reduction in the total timing is possible due to decrease in the terms of both periods [34–36].

G.A. Ilizarov and the researchers of our institute found experimentally the optimal rate of bone distraction of 1 mm/day for bone tissue regeneration with the apparatus

that has been acknowledged as the classical one. Simple calculations showed that with round-the-clock (24 hours) automated bone lengthening, the real distraction rhythm is only 0.04 mm/h against 0.08 mm/h with classical Ilizarov lengthening by which 1 mm is achieved only during the daytime. The earlier mechanical biological studies of other re-searchers showed that high distraction rates may impair vascularization and local blood supply to the regenerated bone and thus prolong its healing. It may result in the formation of cartilaginous and fibrous tissue in the distraction gap preventing consolidation [50]. From the other side, high frequency of distraction at the standard rate may not control bone cell differentiation and subsequent bone formation and cause premature consolidation [51]. However, high daily rate along with low frequency of distraction may result in chondroid or fibrous tissue instead of bone tissue in the distraction gap. In this case, osteogenesis stimulation is required for improving regeneration [52].

Therefore, we combined three factors: an increased round-the-clock distraction rate (2 or 3 mm) with a motorized distractor adjusted to the Ilizarov frame and fixation reinforcement along with regeneration stimulation with HA-coated intramedullary wires in our experimental and clinical trials.

Indeed, an experimental increase in the rate of automated distraction up to 2 and even 3 mm/day did not reveal any fundamental radiological differences in the intensity of bone regeneration (Fig. 1). The morphological study of the features of the regenerative process in automated high-frequency lengthening of the tibia of mongrel dogs showed significant differences in the structure of the distraction regenerate in comparison with the classical rhythm, both in the period of distraction and in the period of fixation [53].

This was expressed in a higher content of the bone component in the regenerates with automatic highly fractional limb lengthening, the proportion of which decreased with increasing tempo. However, in all cases after the cessation of distraction, by the 30<sup>th</sup> day of fixation of the limb in the apparatus, supportable bone regenerate was formed in the interfragmentary diastasis. Thus, high-frequency automated distraction (3 mm with 120 increments day per) may reduce the external fixation period in tibial lengthening by 31 % in comparison with the classical Ilizarov technique [34, 53].

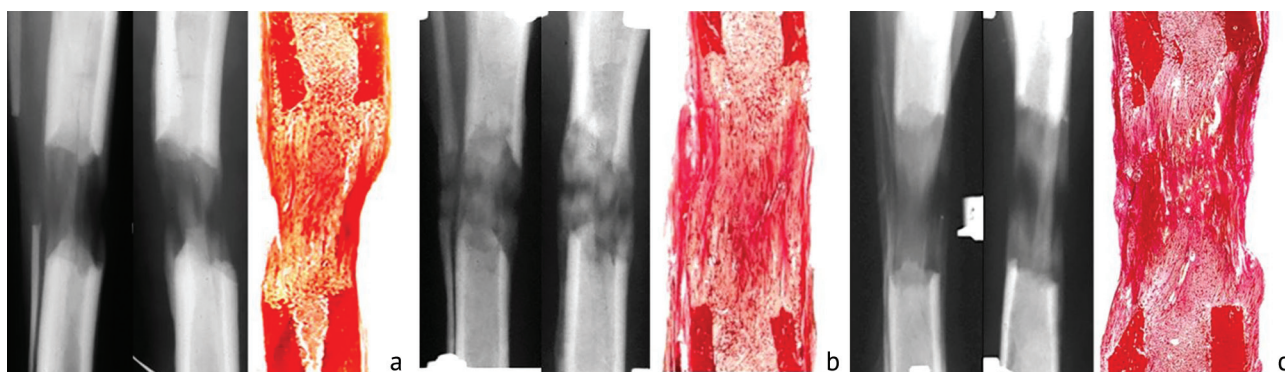


Fig. 1. Radiographs and histotopograms of the regenerate tibia of the lower leg of the experimental animal at the end of the distraction period for 3-cm lengthening taken by different rates of automated lengthening: a – 1 mm per day for 30 days; b – 2 mm per day for 15 days; c, d – 3 mm per day for 10 days



One of the simple but very promising ways to stimulate reparative regeneration of bone tissue is the technology of combined Ilizarov osteosynthesis and intramedullary elastic reinforcement with titanium hydroxyapatite-coated wires [54, 55]. According to experimental studies conducted at our institution, it does not contradict the principles of the Ilizarov method and ensures the safety of intramedullary blood supply. This technology has easily conquered a number of clinical practices in Russia, France and Serbia. Simplicity and efficiency in terms of reducing the osteosynthesis time allow this method to compete with lengthening technologies using the Ilizarov apparatus on massive in-traosseous implants that destroy the bone marrow foreign intramedullary implants used for LLD correction [14, 30]. It primarily relies on the osteogenic potential of the bone marrow.

Experimental and clinical substantiation of a two- or three-fold increase in the rate of automated distraction in the conditions of intramedullary reinforcement with a bioactive implant can drastically reduce not only the time of the distraction period, but also the duration of the fixation period with the Ilizarov apparatus. An experimental trial of the new technology of high-frequency distraction osteogenesis (3 mm/day with 120 increments) and combined osteosynthesis is presented in Figure 2.

The Ilizarov apparatus in this case was dismantled almost immediately after the end of the distraction period and the mechanical strength of the regenerate strengthened with an HA-coated intramedullary wire was sufficient to avoid complications such as its deformation or fracture in the follow-up period of six months.

In a clinical trial of this technology, the Ilizarov apparatus was removed early after a two-week fixation period due to purely subjective reasons, both on the part of the patient and on the part of surgeons (Fig. 3). The femur in this patient was shortened by 2.5 cm after a comminuted intertrochanteric fracture treated with intramedullary nailing. The patient wished to remove the intramedullary nail and restore the length of the thigh within 1–1.5 months. The intervention was performed on 21.08.2015 and included removal of a foreign body, introduction of two HA-coated intramedullary wires, placement of the Ilizarov frame supplied with a device for automated high-frequency distraction rate of 2 mm/day. The fixation period continued two weeks, so the index of osteosynthesis was 13 days/cm. It should be noted that the patient could walk with full load on the operated leg immediately after dismantling the Ilizarov apparatus. The follow-up three months later showed complete functional recovery.

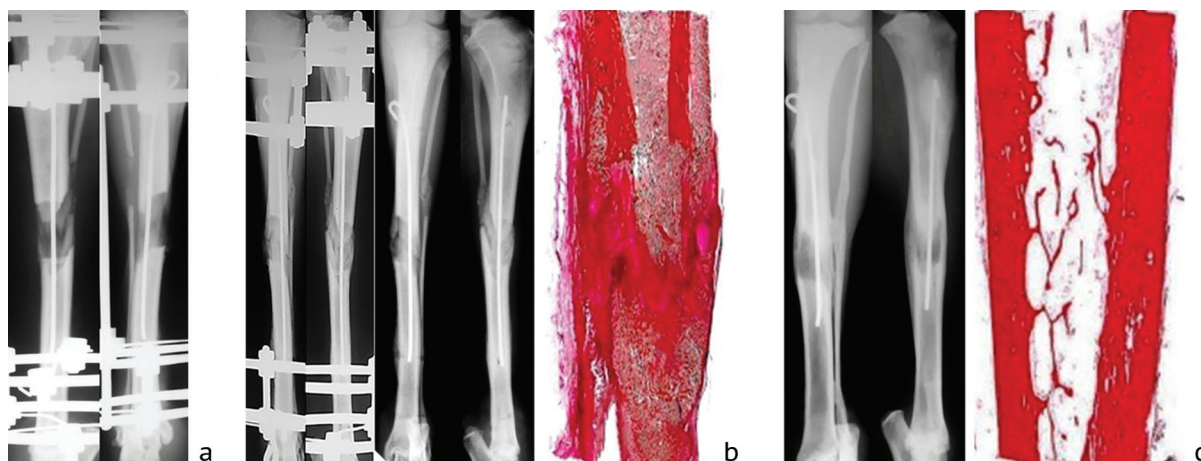


Fig. 2. Combined distraction osteosynthesis of the canine lower leg performed with the optimal mode of automated distraction (distraction rate – 3 mm/day, the period of distraction – 10 days): a – X-rays on the day of the end of distraction; b – X-rays and histotopograms on the day of the end of fixation with the Ilizarov apparatus (X-rays before dismantling and immediately after dismantling the Ilizarov apparatus, index of osteosynthesis – 7 days/cm); c – X-rays and histotopograms of the tibia 6 months later

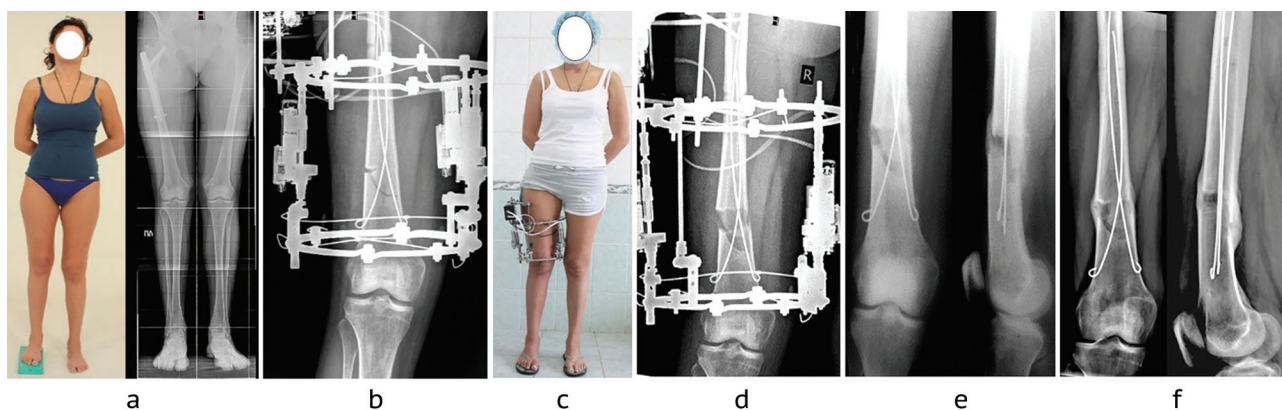


Fig. 3. Patient, 42 years old, diagnosed with 2.5-cm post-traumatic shortening of the right thigh, foreign body in the right femur: a – photo of the patient and radiographs of the bones of the lower extremities before surgery; b – radiograph of the right femur on the day of surgery (corticotomy, combined osteosynthesis); c – patient in the course of treatment; d – radiograph of the right femur on the day of distraction completion; e – radiographs of the right femur after two weeks of fixation on the day dismantling the Ilizarov apparatus; f – radiographs of the right thigh three months after dismantling the apparatus

In delayed consolidation, a way of stimulating the distraction regenerate has been proposed by acute one-step compression stress executed to the distraction regenerate (Fig. 4) [56]. This technique works well with the classic Ilizarov limb lengthening, with automated round-the-clock lengthening, as well as with combined distraction osteosynthesis.




Fig. 4. Diagram of performing distraction regenerate compression (on the left) and histotopogram in the contact zone of bone trabeculae (on the right)

The supports of the Ilizarov apparatus were brought together so that the trabecular structures of the regenerate could contact. The average compression stress experienced by the distraction regenerate was  $1.92 \pm 0.26 \text{ kgf/cm}^2$ . It was proven that due to compression the trabecular structures got in contact with each other and, due to their high mineralization, did not collapse under the impact of applied compression forces. The latter were sufficient to crush the connective tissue layer in the regenerate. After two to 3 weeks of fixation, the diameter of the regenerate exceeded the diameter of the adjacent bone fragments by one to 3 mm, and consolidation was revealed (Fig. 5). On the periphery of the regenerate, the shadows of the cortical plate undergoing formation were determined from all sides.

Clinical practice has confirmed that this technology for stimulating distraction regenerate allows the bone fragments to be brought closer to the height of the "growth zone" which averaged  $5.0 \pm 1.0 \text{ mm}$ . Therefore, it is recommended to overlengthen the limb segment to the height of the "growth zone" and then proceed to compression.

In combined technology with automated high-frequency distraction, the intensity of reparative regeneration is high and the "growth zone" of the distraction regenerate is usually not traced, therefore, immediate compression after the completion of lengthening will not result in the loss of limb length. The intensity of mineralization of the distraction regenerate is significantly higher in intramedullary osteosynthesis with HA-coated wires, and the content of mineral substances in the "growth zone" of the regenerate is 2 times higher compared to the classical Ilizarov elongation method.

The level of distraction efforts and their dynamics are influenced by such factors as the etiology of the disease, the amount of shortening, atrophy of soft tissues, muscle strength and range of motion in adjacent joints, extension of scar tissue due to previous surgical interventions, invasiveness of surgery. However, the greatest distraction efforts (65–74 %) developed by the apparatus are due to resistance from the distraction bone regenerate. Optimal tension at the beginning of distraction is provided by a low-traumatic technique of partial compactotomy and is explained by the maximum preservation of soft tissue connections between bone fragments (muscles, fascia, periosteum, vessels, etc.). The higher the level of distraction forces at the beginning of lengthening, the more optimal the dynamic curve will be, the shorter the treatment time. The magnitude of the daily increase in distraction efforts is inversely correlated with the time of fixation of the limb, while the technique of surgical intervention and the rate of distraction are of great importance. The implementation of the Ilizarov method achieves a daily increase in efforts from 3 to 9 kg, depending on the etiology of shortening, the magnitude of elongation and other objective factors.

In a clinical setting, individual dynamic control over the distraction efforts of each patient is important as the forces experienced by the external fixation apparatus continuously increase during the lengthening process. Under these conditions, the time of fixation, and, consequently, the total period of treatment is the shortest. Sudden drops in distraction forces are associated with the fact that the rate of distraction begins to exceed the rate of bone formation, and the continuity of the regenerate may disrupt. Thus, a decrease in the rate of distraction or even a temporary cessation of limb lengthening is required. Therefore, control over the dynamics of distraction efforts becomes the most important condition for programming the operation of a robotic automatic distractor and control of the limb lengthening process based on feedback principles.

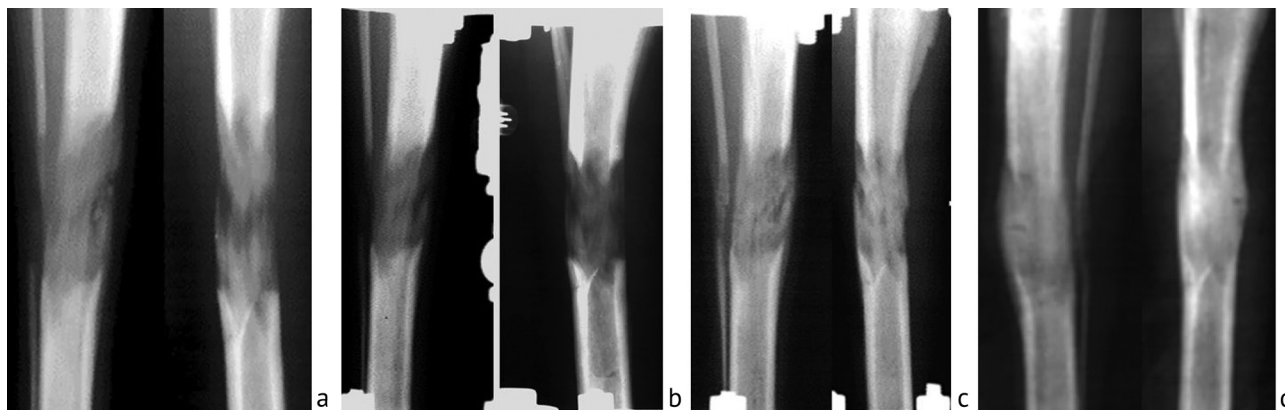


Fig. 5. X-ray of the canine lower leg by performing one-step compression: a - 35 days of distraction, in the center of the distraction regenerate, a translucency zone with a height of 5 mm is visible, which is called the "zone of the distraction regenerate growth"; b - compression of the regenerate, mineralized areas of the distraction regenerate are in contact, and there is no "zone of the distraction regenerate growth"; c - 19 days of fixation, the frame was removed; d - 30 days without the frame



The patient has the right to expect a good functional result in terms of both the range of motion in the joints and muscle strength, full blood supply and trophism of the limb. The experimental studies allowed us to determine previously unknown mechanisms of the distraction bone regenerate formation in the conditions of high-frequency lengthening with an increased rate (3 mm/day), associated with the peculiarities of its blood supply and muscle condition. It was shown that this rate, in the presence of intramedullary reinforcement with a bioactive implant, is not critical for the adaptation of the tibial bloodstream and ensures high activity of angiogenesis processes. The study of the stages of regenerate formation under these conditions found good vascularization of the regenerate by the end of the lengthening period. Intramedullary insertion of HA-coated wires provided an earlier weight-bearing ability of the newly formed bone area, which further reduced the apparatus treatment period. The index of osteosynthesis was 14 days/cm, which is more than 2 times lower than the highest index reported. These studies have brought us very close to fulfilling the dream of an orthopedic surgeon, when the end of the distraction period will become an indication for the termination of external fixation and ensure positive treatment outcome.

The experimental conditions did not affect the soft tissues of the lengthened segment either. It was due to both the use of a more sparing variant of osteosynthesis with

the Ilizarov apparatus and a rather short fixation period. The latter circumstance decreased the impact of negative consequences associated with the imbalance of antagonistic muscles. Histological analysis of the tibialis anterior muscle, which undergoes the greatest morphofunctional changes in lower leg lengthening, was characterized by the absence of gross irreversible destructive changes [35].

In the experiment with rapid distraction, we did not observe the development of contractures of the adjacent joints with lengthening by 20–25 % of the original tibia length. In the clinic, when the limb was lengthened by 6 cm, we observed limitations in the range of motion in the adjacent joints, which were restored 2–3 months after the Ilizarov apparatus dismounting. Further experimental and clinical studies should give an answer about the degree of influence of the rate and rhythm of distraction, the amount of lengthening and an intraosseous implant with a hydroxyapatite coating on the functional state of muscles and joints.

The orthopaedic world has witnessed extraordinary advances in limb lengthening [57]. The results of this automated distraction technology supported by a stimulating effect of HA-coated intramedullary implants allows us to set new targets in terms of lower limb lengthening with external fixation. We believe that it should not exceed 2 months for 3-cm lengthening; 3 months for 6 cm; 3–4 months for 9 cm; and 3–4 months for 12 cm.

## REFERENCES

- Илизаров Г.А. Наш опыт остеосинтеза аппаратом автора // 1 съезд травматол.-ортопедов СССР: материалы съезда. М., 1963. С. 166–168.
- Ilizarov G.A. The tension-stress effect on the genesis and growth of tissues. Part I. The influence of stability of fixation and soft-tissue preservation // *Clin. Orthop. Relat. Res.* 1989. No 238. P. 249–281.
- Gubin A.V., Borzunov D.Y., Malkova T.A. The Ilizarov paradigm: thirty years with the Ilizarov method, current concerns and future research // *Int. Orthop.* 2013. Vol. 37, No 8. P. 1533–1539. DOI: 10.1007/s00264-013-1935-0.
- Morcos M.W., Al-Jallad H., Hamdy R. Comprehensive Review of Adipose Stem Cells and Their Implication in Distraction Osteogenesis and Bone Regeneration // *Biomed. Res. Int.* 2015. Vol. 2015. P. 842975. DOI: 10.1155/2015/842975.
- Rozis M., Polyzois V., Pneumatics S. The Distraction Osteogenesis Callus: a Review of the Literature // *Clinic Reviews in Bone and Mineral Metabolism.* 2021. Vol. 19, No 2. P. 1–12. DOI: 10.1007/s12018-021-09282-x.
- Hosny G.A. Limb lengthening history, evolution, complications and current concepts // *J. Orthop. Traumatol.* 2020. Vol. 21, No 1. P. 3. DOI: 10.1186/s10195-019-0541-3.
- Tibial lengthening using a fixator-assisted lengthening plate: a new technique / H.B. Tosun, I. Agir, S. Gumustas, S. Serbest, A. Uludag, S. Celik // *Trauma Mon.* 2016. Vol. 21, No 5. P. e25340. DOI: 10.5812/traumamon.25340.
- Limb lengthening and deformity correction of congenital and acquired deformities in children using the Taylor Spatial Frame / J. Horn, H. Steen, S. Huhnstock, I. Hvid, R.B. Gunderson // *Acta Orthop.* 2017. Vol. 88, No 3. P. 334–340. DOI: 10.1080/17453674.2017.1295706.
- Lengthening over an existing intramedullary nail in cases of post-traumatic femoral shortening. Technical Note. Case Series Study / A. Boutsidiadis, E. Iosifidou, X. Nikolaos, I. Hatzokos // *Open Orthop. J.* 2016. Vol. 10. P. 12–18. DOI: 10.2174/1874325001610010012.
- Morrison S.G., Georgiadis A.G., Dahl M.T. What's new in limb lengthening and deformity correction // *J. Bone Joint Surg. Am.* 2020. Vol. 102, No 16. P. 1391–1396. DOI: 10.2106/JBJS.20.00531.
- Preliminary experience with motorized distraction for tibial lengthening / A.S. Bright, J.E. Herzenberg, D. Paley, I. Weiner, R.D. Burghardt // *Strategies Trauma Limb Reconstr.* 2014. Vol. 9, No 2. P. 97–100. DOI: 10.1007/s11751-014-0191-1.
- Horn A., Sipilä M. Femoral lengthening in children // *SA Orthop. J.* 2020. Vol. 19, No 1. P. 12–17. DOI: 10.17159/2309-8309/2020/v19n1a1.
- Лабораторные критерии мониторинга патологического процесса у больных с хроническим остеомиелитом голени на этапах восстановительного лечения / М.В. Стогов, Д.С. Леончук, Н.М. Ключин, Н.В. Тушина // *Гений Ортопедии.* 2017. Т. 23, № 3. С. 346–350. DOI: 10.18019/1028-4427-2017-23-3-346-350.
- Tibial lengthening over intramedullary nails: A matched case comparison with Ilizarov tibial lengthening / R.D. Burghardt, A. Manzotti, A. Bhav, D. Paley, J.E. Herzenberg // *Bone Joint Res.* 2016. Vol. 5, No 1. P. 1–10. DOI: 10.1302/2046-3758.51.2000577.
- Calder P.R., Faimali M., Goodier W.D. The role of external fixation in paediatric limb lengthening and deformity correction // *Injury.* 2019. Vol. 50, No Suppl. 1. P. S18–S23. DOI: 10.1016/j.injury.2019.03.049.
- Malkova T.A., Borzunov D.Y. International recognition of the Ilizarov bone reconstruction techniques: Current practice and research (dedicated to 100th birthday of G.A. Ilizarov) // *World J. Orthop.* 2021. Vol. 12, No 8. P. 515–533. DOI: 10.5312/wjo.v12.i8.515.
- Results of tibial lengthening with the Ilizarov technique / D.F. Stanitski, H. Shahcheraghi, D.A. Nicker, P.F. Armstrong // *J. Pediatr. Orthop.* 1996. Vol. 16, No 2. P. 168–172. DOI: 10.1097/00004694-199603000-00006.
- Surgical Results of Limb Lengthening at the Femur, Tibia, and Humerus in Patients with Achondroplasia / K.R. Ko, J.S. Shim, C.H. Chung, J.H. Kim // *Clin. Orthop. Surg.* 2019. Vol. 11, No 2. P. 226–232. DOI: 10.4055/cios.2019.11.2.226.
- Femoral lengthening over an intramedullary nail using the external fixator: risk of infection and knee problems in 22 patients with a follow-up of 2 years or more / H.R. Song, C.W. Oh, R. Mattou, B.C. Park, S.J. Kim, I.H. Park, I.H. Jeon, J.C. Ihn // *Acta Orthop.* 2005. Vol. 76, No 2. P. 245–252. DOI: 10.1080/00016470510030652.

20. Complications and outcome of tibial lengthening using the Ilizarov method with or without a supplementary intramedullary nail: a case-matched comparative study / X.T. Sun, T.R. Easwar, S. Manesh, J.H. Ryu, S.H. Song, S.J. Kim, H.R. Song // J. Bone Joint Surg. Br. 2011. Vol. 96, No 6. P. 782-787. DOI: 10.1302/0301-620X.93B6.25521.
21. Is bilateral lower limb lengthening appropriate for achondroplasia?: midterm analysis of the complications and quality of life / S.J. Kim, G.C. Balce, M.V. Agashe, S.H. Song, H.R. Song // Clin. Orthop. Relat. Res. 2012. Vol. 470, No 2. P. 616-621. DOI: 10.1007/s11999-011-1983-y.
22. Fracture following lower limb lengthening in children: a series of 58 patients / F. Launay, R. Younsi, M. Pithioux, P. Chabrand, G. Bollini, J.L. Jouve // Orthop. Traumatol. Surg. Res. 2013. Vol. 99, No 1. P. 72-79. DOI: 10.1016/j.otsr.2012.08.005.
23. Femoral lengthening over a pediatric femoral nail: results and complications / J.E. Gordon, M.C. Manske, T.R. Lewis, J.C. O'Donnell, P.L. Schoencker, K.A. Keeler // J. Pediatr. Orthop. 2013. Vol. 33, No 7. P. 730-736. DOI: 10.1097/BPO.0b013e3182a122a1.
24. Lower limb lengthening over an intramedullary nail: a long-term follow-up study of 28 cases / P. Farsetti, F. De Maio, V. Potenza, K. Efremov, M. Marsiolo, A. Caterini, E. Ippolito // J. Orthop. Traumatol. 2019. Vol. 20, No 1. P. 30. DOI: 10.1186/s10195-019-0538-y.
25. A comparison of two osteotomy techniques for tibial lengthening / L. Eralp, M. Kocaoglu, K. Ozkan, M. Türker // Arch. Orthop. Trauma Surg. 2004. Vol. 124, No 5. P. 298-300. DOI: 10.1007/s00402-004-0646-9.
26. Koczewski P., Shadi M. Factors influencing bone regenerate healing in distraction osteogenesis // Ortop. Traumatol. Rehabil. 2013. Vol. 15, No 6. P. 591-599. DOI: 10.5604/15093492.1091515.
27. Sheridan G.A., Fragomen A.T., Rozbruch S.R. Integrated limb lengthening is superior to classical limb lengthening: a systematic review and meta-analysis of the literature // J. Am. Acad. Orthop. Surg. Glob. Res. Rev. 2020. Vol. 4, No 6. P. e20.00054. DOI: 10.5435/JAAOSGlobal-D-20-00054.
28. Réduction de la durée du traitement dans les allongements osseux progressifs. Technique et avantage / V. Shevtsov, A. Popkov, D. Popkov, J. Prévot // Rev. Chir. Orthop. Reparatrice Appar. Mot. 2001. Vol. 87, No 3. P. 248-256.
29. Limb lengthening and deformity correction of congenital and acquired deformities in children using the Taylor Spatial Frame / J. Horn, H. Steen, S. Huhnstock, I. Hvid, R.B. Gunderson // Acta Orthop. 2017. Vol. 88, No 3. P. 334-340. DOI: 10.1080/17453674.2017.1295706.
30. Stature lengthening using the PRECICE intramedullary lengthening nail / D. Paley, K. Debiparshad, H. Balci, W. Windisch, C. Lichtblau // Author Information Techniques in Orthopaedics. 2015. Vol. 30, No 3. P. 167-182. DOI: 10.1097/BTO.0000000000000140.
31. Limb lengthening and deformity correction with externally controlled motorized intramedullary nails: evaluation of 50 consecutive lengthenings / J. Horn, I. Hvid, S. Huhnstock, A.B. Breen, H. Steen // Acta Orthop. 2019. Vol. 90, No 1. P. 81-87. DOI: 10.1080/17453674.2018.1534321.
32. Lengthening with monolateral external fixation versus magnetically motorized intramedullary nail in congenital femoral deficiency / V.L. Szymczuk, A.I. Hammouda, M.G. Gesheff, S.C. Standard, J.E. Herzenberg // J. Pediatr. Orthop. 2019. Vol. 39, No 9. P. 458-465. DOI: 10.1097/BPO.0000000000001047.
33. Функциональное восстановление после оперативного удлинения нижних конечностей в высокоточном режиме у детей / Д.А. Попков, А.В. Попков, В.А. Щуров, Н.А. Кононович // Новости Хирургии. 2016. Т. 24, № 4. С. 373-378. DOI: 10.18484/2305-0047.2016.4.373.
34. Особенности формирования костного регенерата, структурных изменений суставного хряща и большеберцового нерва в условиях автоматического удлинения голени по Илизарову с темпом 3 мм с применением ахиллотомии (экспериментальное исследование) / Е.Н. Горбач, Т.А. Ступина, Т.Н. Варсегова, М.А. Степанов, Е.С. Горбач // Гений Ортопедии. 2018. Т. 24, № 4. С. 507-514.
35. Bone Formation and Adaptive Morphology of the Anterior Tibial Muscle in 3-mm Daily Lengthening Using High-Fractional Automated Distraction and Osteosynthesis with the Ilizarov Apparatus Combined with Intramedullary Hydroxyapatite-Coated Wire / A.V. Popkov, N.A. Kononovich, G.N. Filimonova, E.N. Gorbach, D.A. Popkov // Biomed. Res. Int. 2019. Vol. 2019. P. 3241263. DOI: 10.1155/2019/3241263.
36. Автоматический дистракционный остеосинтез / В.И. Шевцов, А.В. Попков, С.А. Ерофеев, А.М. Чиркова // Анналы Травматологии и Ортопедии. 1995. № 1. С. 44-47.
37. Can platelet-rich plasma shorten the consolidation phase of distraction osteogenesis? An experimental study / A.M. Ali, B. El-Alfy, M. Amin, M. Nematalla, el-S.A. El-Shafaey // Eur. J. Orthop. Surg. Traumatol. 2015. Vol. 25, No 3. P. 543-548. DOI: 10.1007/s00590-014-1542-9.
38. Borzunov D.Y., Shastov A.L. Mechanical solutions to salvage failed distraction osteogenesis in large bone defect management // Int. Orthop. 2019. Vol. 43, No 5. P. 1051-1059. DOI: 10.1007/s00264-018-4032-6.
39. Mechanical regulation of bone regeneration during distraction osteogenesis / R. Fu, Y. Feng, Y. Liu, H. Yang // Medicine in Novel Technology and Devices. 2021. Vol. 11. P. 100077. DOI: 10.1016/j.medntd.2021.100077.
40. Effect of low-intensity pulsed ultrasound on distraction osteogenesis treatment time: a meta-analysis of randomized clinical trials / H. Raza, H. Saltaji, H. Kaur, C. Flores-Mir, T. El-Bialy // J. Ultrasound Med. 2016. Vol. 35, No 2. P. 349-358. DOI: 10.7863/ultra.15.02043.
41. Effect of low-intensity pulsed ultrasound on distraction osteogenesis: a systematic review and meta-analysis of randomized controlled trials / S. Lou, H. Lv, Z. Li, P. Tang, Y. Wang // J. Orthop. Surg. Res. 2018. Vol. 13, No 1. P. 205. DOI: 10.1186/s13018-018-0907-x.
42. Electrical stimulation in bone tissue engineering treatments / L. Leppik, K.M.C. Oliveira, M.B. Bhavsar, J.H. Barker // Eur. J. Trauma Emerg. Surg. 2020. Vol. 46, No 2. P. 231-244. DOI: 10.1007/s00068-020-01324-1.
43. Овчинников Е.Н., Стогов М.В. Стимуляция остеогенеза постоянным электрическим током (обзор литературы) // Травматология и ортопедия России. 2019. Т. 25, № 3. С. 185-191. DOI: 10.21823/2311-2905-2019-25-3-185-191.
44. Iryanov Y.M., Sazonova N.V., Kiryanov N.A. The Effect of Ultra-High Frequency Electromagnetic Radiation on Reparative Osteogenesis and Angiogenesis under Transosseous Osteosynthesis // J. Orthop. Res. Physiother. 2015. Vol. 1, No 010. DOI: 10.24966/ORP-2052/100009.
45. The assessment of new bone formation induced by unfocused extracorporeal shock wave therapy applied on pre-surgical phase of distraction osteogenesis / E. Senel, E. Ozkan, M.C. Bereket, M.E. Onger // Eur. Oral Res. 2019. Vol. 53, No 3. P. 125-131. DOI: 10.26650/eor.20190041.
46. Effect of Systemic Oxytocin Administration on New Bone Formation and Distraction Rate in Rabbit Mandible / B. Altay, E.Ç. Dede, Ö. Özgül, F. Atıl, İ.D. Koçyiğit, K. Orhan, U. Tekin, P. Korkusuz, M.E. Önder // J. Oral Maxillofac. Surg. 2020. Vol. 78, No 7. P. 1171-1182. DOI: 10.1016/j.joms.2020.03.005.
47. Do antiosteoporotic drugs improve bone regeneration *in vivo*? / M. Leiblein, D. Henrich, F. Fervers, K. Konradowitz, I. Marzi, C. Seebach // Eur. J. Trauma Emerg. Surg. 2020. Vol. 46, No 2. P. 287-299. DOI: 10.1007/s00068-019-01144-y.
48. Vitamin E promotes bone formation in a distraction osteogenesis model / H. Akçay, K. Kuru, B. Tatar, F. Şimşek // J. Craniofac. Surg. 2019. Vol. 30, No 8. P. 2315-2318. DOI: 10.1097/SCS.0000000000005685.
49. Effects of local low-dose alendronate injections into the distraction gap on new bone formation and distraction rate on distraction osteogenesis / Y.E. Alp, A. Taskaldiran, M.E. Onder, S. Karahan, İ.D. Kocyigit, F. Atıl, U. Tekin // J. Craniofac. Surg. 2017. Vol. 28, No 8. P. 2174-2178. DOI: 10.1097/SCS.0000000000002615.
50. Tissues formed during distraction osteogenesis in the rabbit are determined by the distraction rate: localization of the cells that express the mRNAs and the distribution of types I and II collagens / G. Li, A.S. Virdi, D.E. Ashhurst, A.H. Simpson, J.T. Triffitt // Cell Biol. Int. 2000. Vol. 24, No 1. P. 25-33. DOI: 10.1006/cbir.1999.0449.
51. Чиркова А.М., Ерофеев С.А. Репаративная регенерация и перестройка кости после разрыва дистракционного регенерата // Гений Ортопедии. 1997. № 4. С. 39-42.
52. Assessment of cell proliferation in regenerating bone during distraction osteogenesis at different distraction rates / G. Li, A.H. Simpson, J. Kenwright, J.T. Triffitt // J. Orthop. Res. 1997. Vol. 15, No 5. P. 765-772. DOI: 10.1002/jor.1100150520.
53. Горбач Е.Н., Степанов М.А. Особенности морфогенеза костной ткани при удлинении голени методом чрескостного дистракционного остеосинтеза при повышенном суточном темпе // Морфология. 2015. Т. 147, № 2. С. 69-74.

54. Role of the flexible intramedullary nailing in limb lengthening in children: comparative study based on the series of 294 lengthenings / D. Popkov, P. Lascombes, A. Popkov, P. Journeau, T. Haumont // Eur. Orthop. Traumatol. 2012. Vol. 3, No 1. P. 17-24. DOI: 10.1007/s12570-012-0090-1.
55. Влияние кальций-фосфатного покрытия спиц на процессы минерализации и активность остеогенеза при чрескостном дистракционном остеосинтезе / В.И. Шевцов, Ю.М. Ирьянов, Н.В. Петровская, Т.Ю. Ирьянова // Морфологические Вестники. 2008. № 3-4. С. 231-234.
56. Шевцов В.И., Леончук С.С. Стимуляция дистракционного остеогенеза при удлинении конечностей: наша концепция. Травматология и ортопедия России. 2021. Т. 27, № 1. С. 75-85. DOI: 10.21823/2311-2905-2021-27-1-75-85.
57. Birch J.G. A Brief History of Limb Lengthening // J. Pediatr. Orthop. 2017. Vol. 37, No Suppl. 2. P. S1-S8. DOI: 10.1097/BPO.0000000000001021.

The article was submitted 24.01.2022; approved after reviewing 01.02.2022; accepted for publication 23.05.2022.

Статья поступила в редакцию 24.01.2022; одобрена после рецензирования 01.02.2022; принята к публикации 23.05.2022.

#### Information about the authors:

1. Arnold V. Popkov – Doctor of Medical Sciences, Professor, apopkov.46@mail.ru;
2. Dmitry A. Popkov – Doctor of Medical Sciences, Professor of RAS, correspondent member French Academy of Medical Sciences, dpopkov@mail.ru, <https://orcid.org/0000-0002-8996-867X>;
3. Elena N. Gorbach – Candidate of Biological Sciences, gorbach.e@mail.ru;
4. Natalia A. Kononovich – Candidate of Veterinary Sciences, n.a.kononovich@mail.ru;
5. Alexander A. Antonov – M.D., verdanastrife@gmail.com, <https://orcid.org/0000-0002-8402-5242>.

#### Информация об авторах:

1. Арнольд Васильевич Попков – доктор медицинских наук, профессор, apopkov.46@mail.ru;
2. Дмитрий Арнольдович Попков – доктор медицинских наук, профессор РАН, член-корр. Французской Академии медицинских наук, dpopkov@mail.ru, <https://orcid.org/0000-0002-8996-867X>;
3. Елена Николаевна Горбач – кандидат биологических наук, gorbach.e@mail.ru;
4. Наталья Андреевна Кононович – кандидат ветеринарных наук, n.a.kononovich@mail.ru;
5. Александр Алексеевич Антонов – verdanastrife@gmail.com, <https://orcid.org/0000-0002-8402-5242>.