

Original article

<https://doi.org/10.18019/1028-4427-2022-28-4-503-506>

Treatment of chronic plantar fasciitis: a comparative study between shockwave therapies and local corticosteroid injection

Dheyaa Mohammed Abdulwahab¹✉, Sarmed Muhamad Mutaesm², Waleed Faris Abdul Qader³

Al-Iraqia Medical School, Al-Iraqia university

¹ Diaamalosh@gmail.com

² dr.sarmadnaji@yahoo.com

³ waleedfaris44@gmail.com

Abstract

Introduction One of the most prevalent ailments for which people seek treatment at a foot and ankle surgery facility is heel discomfort. Plantar fasciitis (PF) is one of the most common causes of adult heel pain and accounts for 11 to 15 % of all foot illnesses requiring medical care. The major symptom is pain and soreness at the heel where the plantar fascia is attached while starting weight-bearing after lengthy periods of rest. Rest, non-steroidal anti-inflammatory drugs (NSAIDs), stretching of the plantar fascia, physical therapy, foot cushioning, and orthotic devices, which may be utilized to meet the patient's demands, are some of the current conservative therapies for PF (planter fasciitis). In intractable instances of plantar fasciitis, where conservative therapy have failed to provide relief, steroid injections into the plantar fascia are often employed. Other treatment options for PF, including extracorporeal shockwave therapy (ESWT) are advised if patients do not react to conservative therapies. **Patients and methods** This study included 50 patients with chronic PF who had failed to react to conservative treatments such as physical therapy, NSAIDs, stretching exercises, and heel cushions for at least 6 months, and who did not have flatfeet or gastrocnemius contracture met the inclusion criteria. Patients were randomly divided into 2 groups: 25 patients received radial extracorporeal shockwave therapy (ESWT) once a week for six weeks (Group I); 25 patients got a single local corticosteroid injection at the plantar fascia's origin (40 mg / 2 ml of methylprednisolone together with 1 ml of local anesthesia, once) (Group II). Assessment of heel pain was done at the start of the trial and before each session using VAS score which was the primary outcome measure at 1, 3 and 6 months. **Results** A total of 50 individuals with persistent planter fasciitis (PF) were included in this investigation. Their age varied from 25 to 45 years old. Females made up 70 % of the sample, while males made up 30 %. Group I: 25 patients with PF who got extracorporeal shockwave treatment for 6 weeks at a time (once a week). There were 17 females (68 %) and 8 males (32 %), in the age ranging from 28 to 44 (mean SD 18.2). Group II: consisted of 25 individuals with PF who were given a local corticosteroid injection. There were 18 females (86.7 percent) and 7 males (13.3 percent) with ages ranging from 25 to 45 years (mean SD 21.9). Group I included 20 patients (80 %) and group II had 22 patients (88 %) who had pain in one foot, whereas 5 (20 %) patients and 3 (12 %) patients had pain in both feet, with no statistically significant difference. There was no significant difference between the groups in terms of the VAS score at the start of the trial ($p = 0.26$), the mean VAS scores were 6.4 and 6.2 in groups I and II, respectively. At one month, the mean VAS scores were 1.6 and 1.2 in group I and II, respectively. At 3 months, the mean VAS score were 2.2 and 1.7, at 6 months 5.1 and 2.3 for groups I and II, respectively. **Conclusion** ESWT and local corticosteroid injection therapies are safe and effective but local corticosteroid injection is more effective than ESWT in the treatment of chronic plantar fasciitis.

Keywords: planter fasciitis (PF), steroid injection, extracorporeal shock wave therapy

For citation: Dheyaa Mohammed Abdulwahab, Sarmed Muhamad Mutaesm, Waleed Faris Abdul Qader. Treatment of chronic plantar fasciitis: a comparative study between shockwave therapies and local corticosteroid injection. *Genij Ortopedii*, 2022, vol. 28, no 4, pp. 503-506. DOI: 10.18019/1028-4427-2022-28-4-503-506.

INTRODUCTION

One of the most prevalent ailments for which people seek treatment at a foot and ankle surgery facility is heel discomfort. Plantar fasciitis is one of the most common causes of adult heel pain, accounting for 11 to 15 % of all foot illnesses requiring medical care [1, 2]. The major presenting symptom is pain and soreness at the calcaneal origin of the plantar fascia after weight bearing after lengthy periods of rest [3].

Weak foot biomechanics, intrinsic foot muscle weakness, lengthy durations of standing and walking, lower plantar fascia flexibility, a higher BMI, and foot abnormalities such as pes planus are all considered risk factors for PF [4].

Plantar fasciitis has an unclear pathophysiology. Plantar fasciitis, according to Lemont et al., is a

degenerative alteration dominated by metatarsal fascia degradation [5]. Heel discomfort, according to Nery et al., is caused by chronic metatarsal fascia tension, which is subsequent to aseptic inflammation induced by microtears caused by repetitive microinjury [6].

Rest, nonsteroidal anti-inflammatory drugs (NSAIDs), stretching exercises of the plantar fascia, foot cushion inserts, and different orthotic devices, which may be utilized to meet the patient's demands, are some of the current conservative therapies for PF [7].

In intractable instances of plantar fasciitis, where conservative therapy has failed to provide relief, steroid injections into the plantar fascia are often employed.

Other treatment options for PF, including extracorporeal shockwave therapy (ESWT) are advised

if patients do not react to conservative therapies [8]. Shockwaves are pulsed acoustic waves with a short duration (10 microseconds), very high pressure amplitudes and low tensile waves amplitude [9]. They are created in water outside of the human body and transferred over a vast skin area to the target site, where the acoustic energy is condensed into a 2–8 mm diameter focal area [10].

If individuals with persistent plantar fasciitis fail to respond to conservative therapy after 6 months, surgical

options may be considered [9, 11]. Surgical therapy options are many. Open surgery, endoscopic plantar fascia debridement, laser, platelet-rich plasma injection, radiofrequency ablation, and other treatments have shown some success [12, 13, 14, 15].

The purpose of this study is to compare the effectiveness and safety of extracorporeal shockwave therapy (ESWT) versus local corticosteroid injection in the treatment of persistent plantar fasciitis (PF).

PATIENTS AND METHODS

This study included 50 patients with chronic PF who had failed to react to conservative treatments such as physical therapy, NSAIDs, stretching exercises, and heel cushions for at least 6 months, and who did not have flatfeet or gastrocnemius contracture met the inclusion criteria.

Patients with a history of heel surgery, associated pathology involving the lower limb such as tarsal tunnel syndrome, effusion of the ankle indicating intra-articular disease, Achilles tendinopathy, patients with systemic disorders such as diabetes mellitus and rheumatoid arthritis, and any recent history of aspirin or aspirin-like drug intake were all excluded.

Informed consents were obtained by all patients.

Patients were randomly divided into 2 groups:

Group I: 25 patients underwent radial extracorporeal shockwave therapy (ESWT) once a week for six weeks.

Group II: 25 patients were administered a single local corticosteroid injection at the plantar fascia's origin (40 mg/2 ml of methylprednisolone together with 1 ml of local anesthesia, once).

Patients had a detailed history, clinical examination, and basic laboratory tests, including a complete blood picture (CBC), erythrocyte sedimentation rate, blood urea, serum creatinine, alanine transaminase (ALT), aspartate transaminase (AST), and fasting blood sugar.

To identify patients with calcaneal spurs, a plain radiograph of the afflicted foot was taken in the lateral view.

Assessment of heel pain was done at the start of the trial and before each session using VAS score which was the primary outcome measure at 1, 3 and 6 months.

Group I treatment plan: ESWT treatments, in which the patient sits or lies comfortably on a sofa, followed by cleaning of the treatment area. Sequences of 2000 shockwave pulses delivered at a rate of 2 pulses per second were used to treat the damaged area. The patient selected the energy level or intensity to 0.2 mJ/mm², which was an acceptable amount. The entire procedure took 15 minutes and did not need the use of any local anesthetics. All of the patients had their sessions once a week for six weeks in a row, with no changes in the therapy settings. All patients were notified to cease using non-steroid anti-inflammatory drugs two weeks after treatment since they slowed down the healing process. During this time, just 500 mg of acetaminophen was permitted for pain relief.

Group II patients: The skin was cleansed and draped before the injection, and 40 mg of 2 ml methylprednisolone with 1 ml of 1 percent lidocaine was administered under aseptic circumstances with a 22-gauge needle through medial plantar heel approach.

All Patients in either group were examined for 30 minutes after therapy to document any adverse events. They were also told not to put their entire weight on their heels for two days. Heel cushions and orthotic insoles were available if needed.

RESULTS

A total of 50 individuals with persistent plantar fasciitis were included in this investigation (PF). Their age varied from 25 to 45 years old. Females made up 70 % of the group, while males made up 30 %.

In terms of therapy, they were separated into two groups at random, as shown in Figure 1 which shows the demographic distribution of participants.

Group I were 25 patients with PF who got extracorporeal shockwave treatment for 6 weeks once a week. There were 17 females (68 %) and 8 males (32 %), in the age ranging from 28 to 44 years (mean SD 18.2).

Group II consisted of 25 individuals with PF who were given a local corticosteroid injection. There were 18 females (86.7 percent) and 7 males (13.3 percent) in the age ranging from 25 to 45 years (mean SD 21.9).

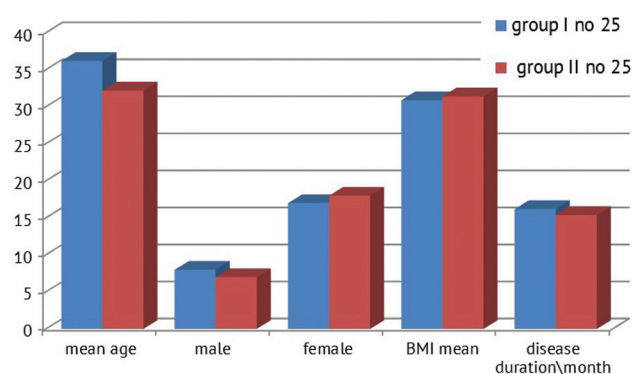


Fig. 1 Demographic distribution of participants

Active employment (hard work, heavy lifting, extended standing or walking for long durations) were

associated with PF in 29/50 patients (58 %), obesity in 24/50 patients (48 %), and females wearing high heels in 18/50 patients (36 %). There were no significant variations in the causes of PF across the groups tested.

Group I included 20 patients (80 %) and group II had 22 patients (88 %) with pain in one foot, whereas 5 (20 %) patients, 3 (12 %) patients had pain in both feet, with no statistically significant difference. There was no significant difference between the groups in terms of the VAS score at the start of the trial ($p = 0.26$); mean VAS scores were 6.4 (mean SD 2.31) and 6.2 (mean SD 2.28) in groups I and II, respectively.

DISCUSSION

Plantar fasciitis is believed to account for 11–15 percent of all foot illnesses requiring medical treatment, according to epidemiological research [1]. It is very frequent among the elderly, especially those between the ages of 40 and 70. Workers who spend a lot of time standing, runners, and obese individuals with a BMI of more than 30 kg/m² are at a higher risk of experiencing more intense pain [16]. According to estimates, nearly 90 % of patients with plantar fasciitis responded well to conservative therapy, including local steroid injections and ESWT and so no surgical intervention was required [17, 18]. Although PF is thought to be self-limiting, chronic cases are resistant to treatment and do not respond to standard conservative measures [19]. Previous research has found that corticosteroid injections are as effective as or more effective than alternative therapies for chronic PF [20].

ESWT's effectiveness for the treatment of chronic PF has been studied, and it is generally considered safe. The best therapy, on the other hand, has yet to be identified [21].

In the current study, we evaluated and compared the short term outcomes of the first 6 months following the treatment with either local steroid injection or ESWT which demonstrated a statistically significant improvement in both groups of patients in the change from baseline to 1 and 3 months in the primary outcome of pain measured by a VAS and although local steroid injection was superior to ESWT but the difference was not significant at this period (Fig. 2).

This might be explained by the fact that ESWT has been demonstrated to boost blood circulation and activity in the cells in the treatment region, which helps the body's natural healing process. The shockwave can potentially overstimulate nerves, resulting in diminished pain station [22].

CONCLUSION

Extracorporeal shock wave therapy and local corticosteroid injection therapies are safe and effective

At 1 month, mean VAS scores were 1.6 (mean SD 1.21) and 1.2 (mean SD 1.12) in groups I and II, respectively.

At 3 months, mean VAS scores were 2.2 (mean SD 1.92) and 1.7 (mean SD 1.78), then 5.1 (mean SD 2.34) and 2.3 (mean SD 2.14) at 6 month for groups I and II, respectively.

Regarding side effects after treatment; not all patients reported side effects ; skin reddening was reported in 31 patients (62 %) of group I patients while pain at the site of injection occurred in 28 patients (56 %) and 1 patient had local site infection.

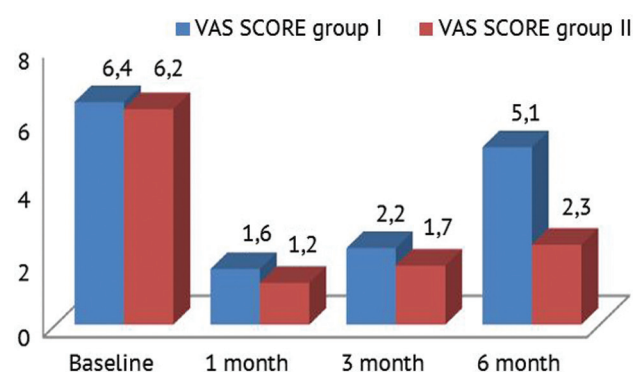


Fig. 2 Changes among the studied groups regarding VAS score before and after treatment

Other investigations have stated that ESWT may impact local pain parameters by causing excessive axon excitation. Then, by eliminating unmyelinated sensory fibers, an analgesic effect is reflexively produced, and so the pain is lessened. Several recent investigations have revealed that ESWT-induced nitric oxide (NO) generation is important in regulating the inflammatory process [10]. Furthermore, direct healing stimulation and neovascularization promotion have been documented [23].

As shown in Figure 2, at 6 months, when compared to the ESWT group, the corticosteroid injection group had remarkably better VAS scores for pain following therapy. Mark D. Porter [24] study concluded that corticosteroid injection is more efficacious and multiple times more cost-effective than ESWT in the treatment of plantar fasciopathy, and this is consistent with our results.

Regarding side effects, for both groups, these can be properly controlled with caution, and a full recovery is expected. Thus, both treatment modalities might be considered safe.

but local corticosteroid injection is more effective than ESWT in the treatment of chronic plantar fasciitis.

REFERENCES

1. Lane G.D., London B. Heel spur syndrome: a retrospective report on the percutaneous plantar transverse incisional approach. *J. Foot Ankle Surg.*, 2004, vol. 43, no. 6, pp. 389-394. DOI: 10.1053/j.jfas.2004.09.004.
2. Jain S.K., Suprashant K., Kumar S., Yadav A., Kearns S.R. Comparison of plantar fasciitis injected with platelet-rich plasma vs corticosteroids. *Foot Ankle Int.*, 2018, vol. 39, no. 7, pp. 780-786. DOI: 10.1177/1071100718762406.
3. Young C. In the clinic. Plantar fasciitis. *Ann. Intern. Med.*, 2012, vol. 156, no. 1, Pt. 1-16. ITC1-1, ITC1-2, ITC1-3, ITC1-4, ITC1-5, ITC1-6, ITC1-7, ITC1-8, ITC1-9, ITC1-10, ITC1-11, ITC1-12, ITC1-13, ITC1-14, ITC1-15; quiz ITC1-16. DOI: 10.7326/0003-4819-156-1-201201030-01001.
4. Li H., Lv H., Lin T. Comparison of efficacy of eight treatments for plantar fasciitis: A network meta-analysis. *J. Cell Physiol.*, 2018, vol. 243, no. 1, pp. 860-870. DOI: 10.1002/jcp.26907.
5. Lemont H., Ammirati K.M., Usen N. Plantar fasciitis: a degenerative process (fasciosis) without inflammation. *J. Am. Podiatr. Med. Assoc.*, 2003, vol. 93, no. 3, pp. 234-237. DOI: 10.7547/87507315-93-3-234.
6. Nery C., Raduan F., Mansur N., Baunfeld D., Del Buono A., Maffulli N. Endoscopic approach for plantar fasciopathy: a long-term retrospective study. *Int. Orthop.*, 2013, vol. 37, no. 6, pp. 1151-1156. DOI: 10.1007/s00264-013-1847-z.
7. Schwartz E.N., Su J. Plantar fasciitis: a concise review. *Perm. J.*, 2014, vol. 18, no. 1, pp. e105-e107. DOI: 10.7812/TPP/13-113.
8. Thomas J.L., Christensen J.C., Kravitz S.R., Mendicino R.W., Schubert J.M., Vanore J.V., Weil L.S. Sr., Zlotoff H.J., Bouché R., Baker J.; American College of Foot and Ankle Surgeons heel pain Committee. The diagnosis and treatment of heel pain: A clinical practice guideline-revision. *J. Foot Ankle Surg.*, 2010, vol. 49, no. 3 Suppl., pp. S1-S19. DOI: 10.1053/j.jfas.2010.01.001.
9. Eslamian F., Shakouri S.K., Jahanjoo F., Hajjaliloo M., Notghi F. Extra corporeal Shockwave therapy versus local corticosteroid injection in the treatment of chronic plantar fasciitis, a single blinded randomized clinical trial. *Pain Medicine*, 2016, vol. 17, no. 9, pp. 1722-1731. DOI: 10.1093/pm/pnw113.
10. Seok H., Kim S.H. The effectiveness of extracorporeal Shockwave therapy vs. local steroid injection for management of carpal tunnel syndrome: a randomized controlled trial. *Am. J. Phys. Med. Rehabil.*, 2013, vol. 92, no. 4, pp. 327-334. DOI: 10.1097/PHM.0b013e31826edc7b.
11. Luffy L., Grosel J., Thomas R., So E. Plantar fasciitis: a review of treatments. *JAAPA*, 2018, vol. 31, no. 1, pp. 20-24. DOI: 10.1097/01.JAA.0000527695.76041.99.
12. Cottom J.M., Baker J.S. Endoscopic plantar fascia debridement for chronic plantar fasciitis. *Clin. Podiatr. Med. Surg.*, 2016, vol. 33, no. 4, pp. 545-551. DOI: 10.1016/j.cpm.2016.06.004.
13. Franceschi F., Papalia R., Franceschetti E., Paciotti M., Maffulli N., Denaro V. Platelet-rich plasma injections for chronic plantar fasciopathy: a systematic review. *Br. Med. Bull.*, 2014, vol. 112, no. 1, pp. 83-95. DOI: 10.1093/bmb/ldu025.
14. Ordahan B., Karahan A.Y., Kaydok E. The effect of high-intensity versus low-level laser therapy in the management of plantar fasciitis: a randomized clinical trial. *Lasers Med. Sci.*, 2018, vol. 33, no. 6, pp. 1363-1369. DOI: 10.1007/s10103-018-2497-6.
15. Chou A.C., Ng S.Y., Su D.H., Singh I.R., Koo K. Radiofrequency microtenotomy is as effective as plantar fasciotomy in the treatment of recalcitrant plantar fasciitis. *Foot Ankle Surg.*, 2016, vol. 22, no. 4, pp. 270-273. DOI: 10.1016/j.fas.2015.11.006.
16. Riddle D.L., Pulisic M., Pidcoe P., Johnson R.E. Risk factors for plantar fasciitis: a matched case-control study. *J. Bone Joint Surg. Am.*, 2003, vol. 85, no. 5, pp. 872-877. DOI: 10.2106/00004623-200305000-00015.
17. Martin R.L., Irrgang J.J., Conti S.F. Outcome study of subjects with insertional plantar fasciitis. *Foot Ankle Int.*, 1998, vol. 19, no. 12, pp. 803-811. DOI: 10.1177/107110079801901205.
18. Riddle D.L., Schappert S.M. Volume of ambulatory care visits and patterns of care for patients diagnosed with plantar fasciitis: a national study of medical doctors. *Foot Ankle Int.*, 2004, vol. 25, no. 5, pp. 303-310. DOI: 10.1177/107110070402500505.
19. Goff J.D., Crawford R. Diagnosis and treatment of plantar fasciitis. *Am. Fam. Physician*, 2011, vol. 84, no. 6, pp. 676-682.
20. Ryan M., Hartwell J., Fraser S., Newsham-West R., Taunton J. Comparison of a physiotherapy program versus dexamethasone injections for plantar fasciopathy in prolonged standing workers: a randomized clinical trial. *Clin. J. Sport Med.*, 2014, vol. 24, no. 3, pp. 211-217. DOI: 10.1097/JSM.0000000000000021.
21. Moghtaderi A., Khosrawi S., Dehghan F. Extracorporeal shock wave therapy of gastrocnemius trigger points in patients with plantar fasciitis: A randomized, placebo-controlled trial. *Adv. Biomed. Res.*, 2014, vol. 3, pp. 99. DOI: 10.4103/2277-9175.129369.
22. Schmitz C., Császár N.B., Rompe J.D., Chaves H., Furia J.P. Treatment of chronic plantar fasciopathy with extracorporeal shock waves (review). *J. Orthop. Surg. Res.*, 2013, vol. 8, pp. 31. DOI: 10.1186/1749-799X-8-31.
23. Krishnan A., Sharma Y., Singh S. Evaluation of therapeutic effects of extracorporeal shock wave therapy in resistant plantar fasciitis patients in a tertiary care setting. *Med. J. Armed Forces India*, 2012, vol. 68, no. 3, pp. 236-239. DOI: 10.1016/j.mjafi.2012.01.007.
24. Porter M.D., Shadbolt B. Intralesional corticosteroid injection versus extracorporeal shock wave therapy for plantar fasciopathy. *Clin. J. Sport Med.*, 2005, vol. 15, no. 3, pp. 119-124. DOI: 10.1097/01.jsm.0000164039.91787.dc.

The article was submitted 14.12.2021; approved after reviewing 26.01.2022; accepted for publication 23.05.2022.

Information about the authors:

1. Dheyaa Mohammed Abdulwahab – Lec. Dr., orthopedic surgeon, Department of surgery, Diaamalosh@gmail.com;
2. Sarmed Muhamad Mutaesm – Lec. Dr., orthopedic surgeon Department of surgery, dr.sarmadnaji@yahoo.com;
3. Waleed Faris Abdul Qader – Ass. Prof. Dr., orthopedic surgeon Department of surgery, waleedfaris44@gmail.com.