

Лечение запущенной косолапости методами Илизарова и Понсети**Neglected clubfoot treated by Ilizarov and Ponseti methods****M.M. Chaudhary, I.M. Chaudhary**

Centre for Ilizarov Techniques, Chaudhary Hospital, AKOLA, India

Метод Понсети произвел революцию в лечении косолапости. Несмотря на то, что полностью запущенная косолапость в настоящее время встречается редко, частичная, неполная или неправильно пролеченная косолапость не является редкостью. Рецидивы после успешной коррекции могут возникать в связи с несоблюдением принципов фиксации. В случае рубцовых изменений после предыдущих операций дистракция мягких тканей с помощью внешней фиксации помогает добиться коррекции. Фиксатор Илизарова позволяет нам следовать протоколу Понсети, используя методы коррекции, которые могут включать как ограниченную, так неограниченную шарнирную коррекцию. Приложение векторов силы перпендикулярно плечу момента позволяет нам исправить эквинусную деформацию без повреждения голеностопного сустава. Все вышеперечисленное возможно, когда таранная кость имеет округлую форму. Возможна полная коррекция деформации, однако при длительном наблюдении этих пациентов выявляется ригидность голеностопного сустава, часто с наличием тибео-таранных остеофитов в переднем отделе. Вероятно, это реакция на чрезмерное давление в полости сустава, обусловленное напряжением мягких тканей. В настоящее время вместо пролонгированной мобилизации рубцовых тканей авторы практикуют небольшое укорочение большеберцовой и малоберцовой костей с целью уменьшения натяжения мягких тканей. Это обеспечивает более быструю коррекцию с помощью протокола Понсети-Илизарова и позволяет сохранить хороший диапазон движений голеностопного сустава.

Ключевые слова: метод Илизарова, метод Понсети, косолапость

The Ponseti method has revolutionized clubfoot treatment. Though completely neglected clubfeet are now rare, partially or incompletely and improperly treated feet are not uncommon. Relapses after successful correction may occur due to non-compliance with bracing. In scarred soft tissues due to previous surgery, soft tissue distraction using external fixation helps achieve correction. The Ilizarov fixator permits us to follow the Ponseti protocol, using correction methods that may either be constrained or unconstrained by hinges. Applying force vectors perpendicular to the moment arm allows us to correct the equinus without damaging the ankle joint. All of the above is possible when the talus is round. Full correction of the deformity is possible. However, long-term follow-up of these patients has revealed stiffness of the ankle setting and frequently with tibio-talar osteophytes anteriorly. They are probably a reaction to excessive pressure developed in the joint due to the tight soft tissues. Hence the author has now added a mild shortening of the tibia and fibula to reduce soft tissue tension, rather than resorting to further soft tissue releases through scarred tissues. This allows faster correction with the Ponseti-Ilizarov protocol and allows good ankle range of motion to persist.

Keywords: the Ilizarov method, the Ponseti method, clubfoot

INTRODUCTION

Relapsed or recurrent clubfeet in older children and young adults are not uncommon, especially with large

deformities and scarred soft tissues due to previous surgery.

CLINICAL EXAMINATION

Older children and young adults may present with varying degrees of forefoot supination, cavus, hindfoot varus, and equinus. Few patients with large deformities will have large callosities on the dorsum, which may turn painful due to bursitis. Other visible signs in the limb can be a thinner calf, smaller foot size, and mild limb length discrepancy (LLD). Despite the severe appearance of the deformity, some feet may be supple, and deformity reasonably correctible, except for the hindfoot equinus. While most deformed clubfeet will have a tight equinus due to scarring from previous surgeries, a few may be partially correctible with the knee flexed.

The underlying disorder may be arthrogryposis or myelomeningocele or Streeter's syndrome with a constriction band. Rarely, the child or adolescent may present with neglected clubfoot as part of a congenital anomaly like fibular hemimelia, congenital femoral deficiency, or tibial hemimelia. Features like sensory loss with decubiti, supernumerary or absent toes, significant LLD, lurch due to an unstable knee or hip may point towards an X-ray examination that will reveal the underlying pathology.

STIFF CLUBFOOT

In most stiff and recurrent clubfoot, previous operative scarring either posteriorly or posteromedially is visible, and little movement is present, either in the ankle or hindfoot joints. Using soft tissue distraction with external fixation is a natural choice.

A rounded talus will allow good correction of the deformity by soft tissue distraction. Repeat soft tissue surgery is not a good idea. The Ilizarov fixator is an ideal tool and has comprehensive capabilities under all clinical circumstances to achieve full correction. The Ponseti method has a sound kinesiological foundation and works well in babies as well as older children. We have used the Ponseti principles reliably with the Ilizarov fixator since the last 19 years at our institute to correct 62 recurrent and relapsed clubfeet.

This article aims to describe how to use the Ponseti principles faithfully using the modular and universal Ilizarov fixator. The Ilizarov fixator is mounted with two rings on the tibia, with two half pins and wires. The configuration for the foot fixation depends upon whether the equinus deformity is accompanied by cavus or varus or valgus or there is no deformity between the hindfoot and forefoot. If there is no

deformity within the foot (as when serial casting has corrected the forefoot deformity), a horseshoe-shaped ring is used for foot fixation. A half pin is inserted in the calcaneum from the tuberosity from posterior to anterior. One or two olive wires are inserted in the calcaneum from the posteromedial aspect from behind the neurovascular structures to exit laterally distally. This configuration is sufficient fixation for the hindfoot. In more rigid deformities, another wire is inserted from anteromedial direction to engage in the sustentaculum, just underneath the tendons but dorsal to the neurovascular structures to exit posterolaterally. These two wires subtend a right angle to each other and hence offer robust fixation.

Another option in older children is to fix the calcaneum with one more half pin; a tapering paediatric 4-mm-to-3 mm threaded pin can give very good fixation. At least two more wires are inserted in the mid and forefoot. An olive from the lateral aspect is inserted through the cuneiforms to exit medially. Just proximal to the MTP joints, an olive wire is inserted from the medial side into the first metatarsal, passing underneath the second and the third and exiting laterally through the substance of the fourth and fifth metatarsals. These two wires are attached to a half ring which is perpendicular to the forefoot. Vertical connections are made to this ring, one medially and one laterally. A wire is also inserted in the head-neck junction of the talus, an olive from the lateral side, offering control over the talus. Most importantly, it offers counter-pressure to allow the forefoot to abduct. This wire is dropped off of the tibial ring. After tensioning, the foot frame becomes rigid.

Step 1: Correction of Forefoot Supination

The forefoot ring is vertical and has two vertical connections (with hinges and struts) connected to the anterior part of the lower tibial ring. By pulling up (compression) on the medial side and pushing down (distraction) on the lateral side; a 'force-couple' action is taken (somewhat akin to turning a steering wheel), which turns the forefoot into supination. This action continues for about 3 to 4 weeks until we clinically decide that the supination of the forefoot matches that with the hindfoot.

Step 2: Correction of Forefoot Adduction

In this phase, we change the connections between the forefoot ring and the lower tibial ring. The vertical connections are removed. A connection is dropped below the lower tibial ring on the medial side. From this connection, a motor rod is deployed, which helps to push the forefoot ring out into abduction. During this phase, a second connection may be employed between the forefoot ring and hindfoot ring. Nevertheless, this connection behaves passively. It allows the hindfoot position to adjust to the changing abduction of the forefoot. The hindfoot is not attached or anchored to the lower tibial ring, allowing the calcaneum to slide out from underneath the talus, as its anterior border is pushed by the forefoot-cuboid.

This phase ends when clinically the forefoot has reached 70° of abduction. An AP x-ray of the foot will reveal a Talo-Calcanal angle of at least 20°. This phase may last for another 3 to 4 weeks.

Step 3: Correction of Equinus

Soft tissue distraction at the ankle may be performed by using two principles: constrained correction or unconstrained correction. We may constrain the correction to occur around hinges which we place in the apparatus. The center of rotation of the ankle is located around the lateral process of the talus. If we can locate the medial

and lateral hinges to overlap accurately at this level, we can place the posterior distraction motor rods posteriorly anywhere convenient. The rate of distraction is calculated depending on the distance between the posterior rods and hinge locations.

The anterior rods do not perform compression. They are kept in "passive" mode: they are loosened just before posterior distraction is performed and then locked in any new (slightly changed) position they may assume a few minutes after the posterior distraction.

The distraction process is monitored with AP & LAT X-rays to ensure that the tibiotalar joint remains congruent that it is neither overdistracted nor crushing of the cartilage occurs at the joint level.

Once the correction is achieved, we aim to achieve overcorrection by a few degrees into dorsiflexion. The apparatus is maintained for a few more weeks in this mode. Extensions are made to the apparatus to enable the patient to walk almost full weight-bearing. After the apparatus is removed, a walking cast is applied for a few weeks, and a brace is made to be worn at night to ensure there is no recurrence of deformity.

Unconstrained Correction (Kinesiological Correction)

In more complex corrections, when equinus is accompanied by varus as in an uncorrected clubfoot, the better option is to perform the unconstrained correction. Here no hinges determine the exact center around which to rotate the ankle. The determinants of correction are the anatomical shape of the articular surfaces and the direction of the motor forces. The initial steps for supination and abduction are similar, and we now describe only the steps for correction of equinus. After the rotation is complete, some inversion of the heel may remain before the equinus can be corrected. Inversion of the heel can be corrected by distracting medially and keeping the lateral end passive.

Finally, the equinus can be corrected. The motors for equinus correction are posterior rods directed from anterior to posterior, connected over multiplane hinges attached to the tibial rings. The aim is to angle them in such a way as to remain perpendicular to the moment arm at the ankle.

The moment arm of the ankle (Fig. 1 a to d) is an imaginary line joining the center of rotation of the ankle with the posterior aspect of the tuberosity. Hence, the forces applied are accurately used to rotate the foot in the ankle without causing distraction, crushing at the ankle, or subluxation.

This motor rod is changed a few times as the correction progresses, always remaining perpendicular to the moment arm. As correction proceeds, the motor rod becomes more and more vertical. This correction is monitored by X-rays to ensure the ankle remains congruent and stable.

During the correction, outriggers can be attached to these foot rings to enable the patient to walk, ensuring that there is no osteoporosis and that the fixator remains stable.

At the end of correction, casting is done, and braces may be worn at night to prevent a recurrence.

Overdistracted of the ankle joint or the subtalar joint should be prevented. This should be observed during the equinus correction phase and an attempt must be made to move the talus and calcaneus simultaneously. The talus wire which is dropped of the lower tibial ring is turned around and attached to the hindfoot ring, ensuring that the talus and calcaneus move together. Crushing of the ankle cartilage can occur or anterior subluxation (Fig. 2 c, d) of the talus anteriorly can occur if the motor rods are not angled.

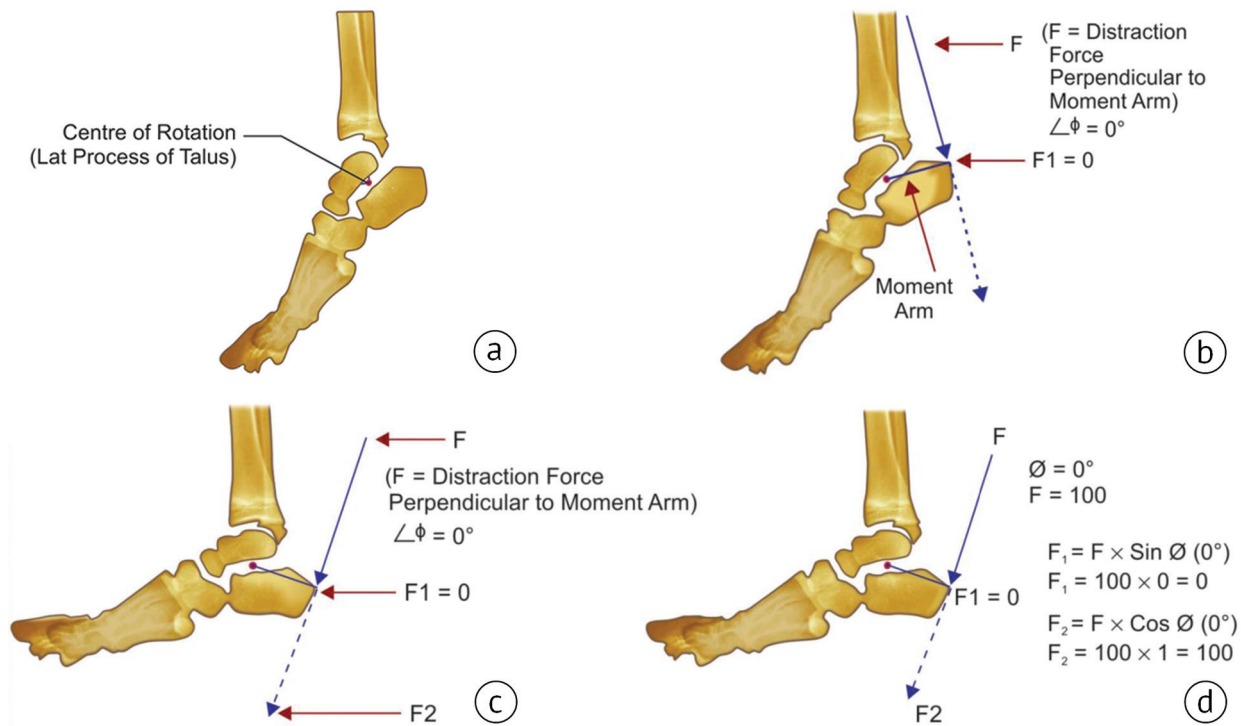


Fig. 1: a, b – equinus with a round talus. The center of rotation is at the lateral process of the talus. The moment arm is a line joining the center of rotation to apply the distraction force at the calcaneal tuberosity. The force F is applied accurately perpendicular to the moment arm. Hence it resolves into a force vector F_1 & F_2 ; c, d – the vector F_1 is derived by a formula of $F \times \sin$ of the angle differing from the perpendicular. Since the Force F is perpendicular, & differing angle is 0, $\sin 0 = 0$ & $F_1 = 0$. The resolved vector F_2 , responsible for all movement at the ankle, is derived from cosine of angle differing from perpendicular. $\cos 0 = 1$, hence all the force applied for distraction acts around the center of rotation accurately, and a perfect correction of ankle equinus is obtained

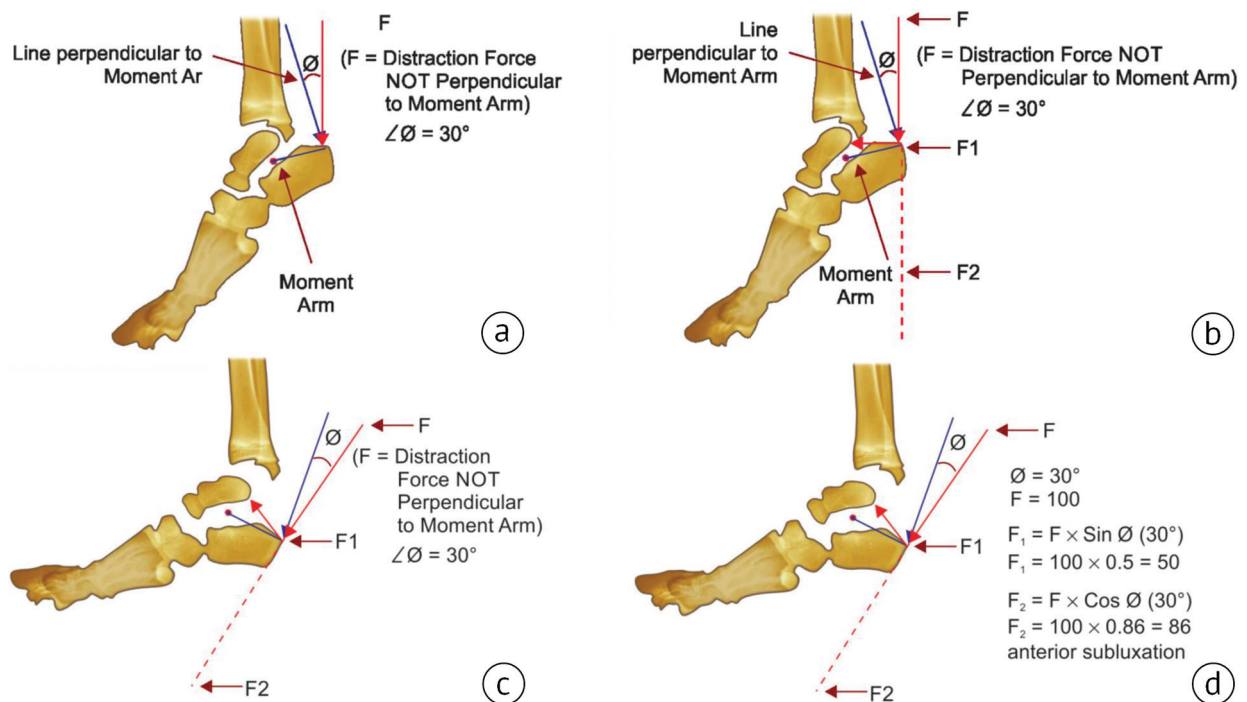


Fig 2: a, b – this situation considers a force F applied at an angle differing from perpendicular by the $\tan \phi$, say 30° . The force F resolves into two vectors F_1 & F_2 ; c, d – F_1 vector is now non-zero and has a value of 0.5, and the F_2 vector has a value less than 100. Hence the anteriorly directed force vector F_1 will anteriorly translate the talus and cause subluxation. Similarly, the force F in any other direction could also cause ankle joint crushing

Similarly, a force F in any other direction could also cause the ankle joint crushing.

Hence during the equinus correction phase, the posterior ankle motors must be made to change direction

at least 3 to 4 times so that they are always perpendicular to the moment arm, which is the centre of rotation of the ankle. Examples of correction performed at a young age (Fig. 3) and in much older patients are also shown (Fig. 4).

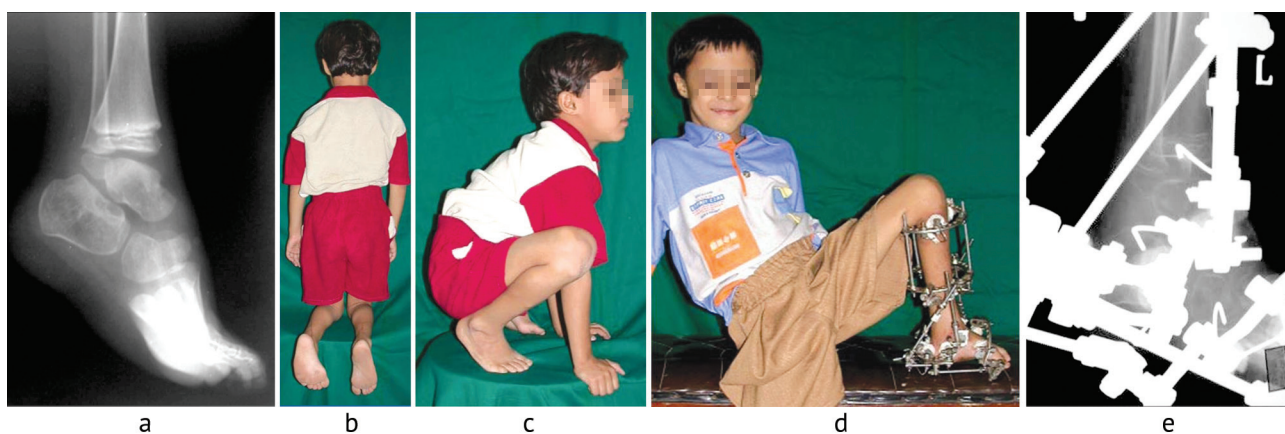


Fig. 3: a, b, c – 8-year old boy with recurrent clubfoot after soft tissue release at 8 months of age. Talus is round. Squatting not possible due to equinus; d, e – Ilizarov apparatus mounted with two rings in tibia serving as a base. Notice hindfoot and forefoot half rings. A dropped wire fixes the talus and is an olive from lateral side. Notice the direction of the hindfoot motors pushing the talus out of equinus. These are kept perpendicular to the moment arm joining the centre of rotation of the talus to posterior calcaneal tuberosity; f, g, – full correction of deformities is visible. Child can squat which shows full dorsiflexion is possible; h – X-rays show a congruent ankle joint

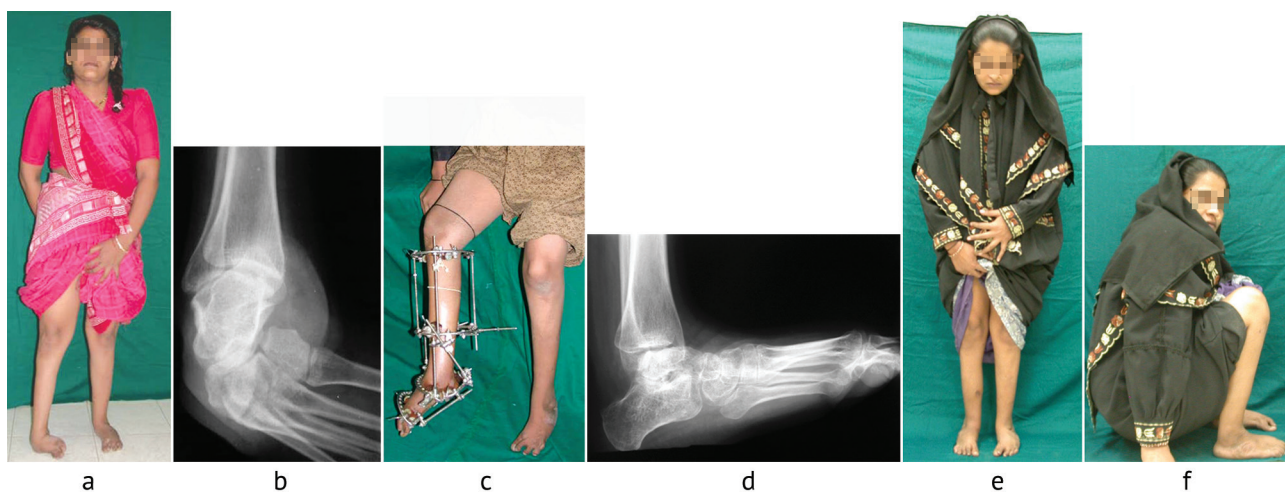
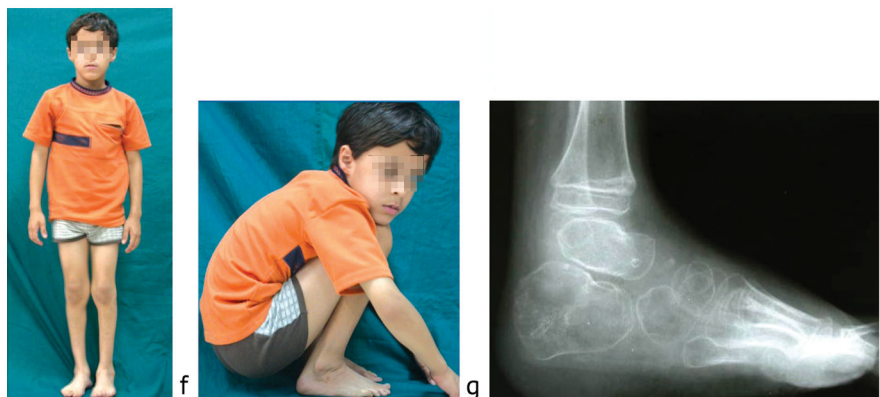

Fig. 4: a, b – 33-year old mother of three with neglected clubfoot with severe deformity. Talar dome is not flattened and hence she is amenable to soft tissue distraction; c – Ilizarov fixator applied with two rings in the tibia. Due to a large foot size, a half-ring is used to fix the talar wire, which is then connected to the lower tibial ring. Forefoot and hind foot rings are now connected in third stage to correct equinus (first stage is correction into supination, second stage is correction of forefoot abduction; both these stages requiring separate montages of the Ilizarov fixator). Notice: the hindfoot motors angled posteriorly to correct equinus deformity; d – X-ray shows full correction of deformity with a congruent ankle joint; e, f – good clinical correction with ability to squat denoting restored dorsiflexion

Maintenance of Correction

After correction has been achieved, it needs to be maintained. The initial period of casting is needed, and the following bracing will retain the correction. If there is an element of dynamic varus or supination deformity, we can control it by an anterior tibialis transfer. The tendon is transferred either to the middle or lateral cuneiform, depending on the deformity.

The Shortening-Ilizarov-Ponseti Protocol

The author has the experience of using the Ilizarov fixator for more than 31 years in the treatment of clubfeet. Since 2002, we have used the Ponseti principles and the special hindfoot motors using the moment arm vector to

achieve good correction in all patients with minimum complications.

However, upon long-term review of some patients, we noticed a recurring theme. Many patients had a reduced ankle range of motion along with osteophytes seen in the lateral X-ray in the anterior tibio-talar joint area. Some of these were “kissing” osteophytes and they completely reduced dorsiflexion movement in the ankle.

It slowly became obvious that this was a reaction to the excessive pressure build-up in the ankle joint. The heaping up of the cartilage to create the osteophytes must have occurred due to excess soft tissue tension as most of them had previous soft tissue surgeries with scarring.

Hence in bilateral cases of stiff recurrent clubfeet we decided to perform shortening of the bone instead of lengthening soft tissues to reduce the “pressure” of the soft tissues. The fibula is shortened through a lateral incision and the tibia through a Z-shaped incision. No more than 2 to 2.5 cm shortening is needed to relax the fibrotic soft tissues. The two Ilizarov rings offer stable fixation for the shortening osteotomy.

The correction of the forefoot, midfoot and the hindfoot

deformities is rapid in comparison to patients who have not been lengthened. Satisfactorily, range of motion of the ankle resumes almost instantly after the apparatus is removed and is retained for a long time.

Performing shortening is acceptable only for the bilateral cases as it would create no iatrogenic limb length discrepancy (LLD). However, even in very badly scarred unilateral clubfeet, it may be a small price to pay for a mobile and pain-free ankle.

REFERENCES

1. Ponseti I. Congenital clubfoot: Fundamentals of Treatment. Oxford, UK: Oxford University Press, 1996. 140 p.
2. Ponseti I.V. Relapsing clubfoot: causes, prevention, and treatment // Iowa Orthop. J. 2002. Vol. 22. P. 55-56.
3. Ponseti I.V. Common errors in the treatment of congenital clubfoot // Int. Orthop. 1997. Vol. 21, No 2. P. 137-141. DOI: 10.1007/s002640050137.
4. Achilles tenotomy as an office procedure: safety and efficacy as part of the Ponseti serial casting protocol for clubfoot / E. Lebel, M. Karasik, M. Bernstein-Weyel, Y. Mishukov, A. Peyser // J. Pediatr. Orthop. 2012. Vol. 32, No 4. P. 412-415. DOI: 10.1097/BPO.0b013e31825611a6
5. Reliability of radiographic measures in infants with clubfoot treated with the Ponseti method / C.C. Zimmerman, B.A. Nemeth, K.J. Noonan, T.P. Vanderbilt, M.J. Winston, C.P. O'Halloran, S.A. Sund, S.J. Hetzel, M.A. Halanski // Child. Orthop. 2015. Vol. 9, No 2. P. 99-104.
6. Hudson I., Catterall A. Posterolateral release for resistant club foot // J. Bone Joint Surg. Br. 1994. Vol. 76, No 2. P. 281-284.
7. Chaudhary M. Kinesiological correction of neglected and relapsed clubfoot using Ilizarov fixator using Ponseti principles // 13th Annual Baltimore Limb Deformity Course. Baltimore, MD, 7-11 September 2003.
8. Grill F., Franke J. The Ilizarov distractor for the correction of relapsed or neglected clubfoot // J. Bone Joint Surg. Br. 1987. Vol. 69, No 4. P. 593-597. DOI: 10.1302/0301-620X.69B4.3611163
9. Ilizarov G.A. Transosseous osteosynthesis: Theoretical and Clinical Aspects of the regeneration and growth of tissue. 1st Ed. Berlin: Springer-Verlag, 1992. 800 p. DOI: 10.1007/978-3-642-84388-4

Received: 20.04.2021

Information about the authors:

1. Milind M. Chaudhary, M.D.,
Centre for Ilizarov Techniques, Chaudhary Hospital, Akola, India,
Email: milind.chaudhary@gmail.com
2. Ishani M. Chaudhary, M.D.,
Centre for Ilizarov Techniques, Chaudhary Hospital, Akola, India