

© Anastasieva E.A., Simagaev R.O., Kirilova I.A., 2020

DOI 10.18019/1028-4427-2020-26-1-117-128

Current surgical treatment of anterior cruciate ligament injury (literature review)**E.A. Anastasieva¹, R.O. Simagaev^{1,2}, I.A. Kirilova¹**¹Tsivyan Novosibirsk Research Institute of Traumatology and Orthopedics, Novosibirsk, Russian Federation²Autonomous Non-profit Organization NRITO Clinic, Novosibirsk, Russian Federation

The anterior cruciate ligament (ACL) is the key stabilizer of the knee joint, which prevents the anterior displacement of the tibia relative the femur and rotational instability of the knee joint. Proper understanding of its complex anatomy, function and biomechanics, mechanism and the type of ACL injury is of great importance in choosing a treatment strategy. Findings of clinical tests and imaging methods have a significant value in the diagnosis of anterior knee joint instability. Considering all the variety of currently existing techniques and implants for operative treatment of anterior knee instability, the clinical practitioner should make the right choice of a method or combination of methods for surgical ACL reconstruction in a specific patient, taking into account individual risks of gonarthrosis. The goal is to ensure knee joint stability with the least invasiveness to allow the patient to return to the preoperative level of physical activity as soon as possible.

Keywords: anterior knee instability, anterior cruciate ligament injury, anterior cruciate ligament reconstruction, treatment of knee instability

INTRODUCTION

The anterior cruciate ligament (PCL) was first described in 170 AD by the Roman physician and philosopher Galen. Subsequently, for more than 1,500 years, no importance was paid to its cure. Only at the beginning of the 20th century, its injuries evoke special interest. With an increase in the number of road traffic injuries and the popularization of professional sports, injuries of the anterior cruciate ligament have come to the forefront of orthopedic problems [1]. To date, the challenge of modern traumatology remains the choice of an adequate method for surgical treatment of knee joint instability.

The whole history of surgery is the desire of doctors to offer the most effective surgical treatment methods that cause minimal trauma and provide a proper esthetic effect. Arthroscopic or minimally invasive (arthroscopically controlled) operations are capable to restore the primary anatomy of a damaged joint. They combine anatomical validity and minimal trauma, pathogenetic justification and high functional efficiency [1, 2]. In the United States alone, the annual need for surgery to reconstruct ACL due to knee joint injury ranges from 100,000 to 200,000 interventions per year [3]. It is known, female athletes have a much greater chance of sustaining an ACL injury. So, one of 60 to

100 female athletes has or had damage to the anterior cruciate ligament in the past [4, 5]. There are exercise programs for athletes with proven evidence of reducing the risk of anterior cruciate ligament ruptures [4, 6].

Anatomy and biomechanics of the anterior cruciate ligament

The anterior cruciate ligament is the key stabilizer of the knee joint and prevents the anterior displacement of the tibia relative to the thigh, as well as rotational instability of the knee joint [2]. Knowledge of the complex anatomy, function, and biomechanics of the anterior cruciate ligament is critical to identification of the mechanisms of injury, understanding chronic anterior instability of the knee joint, and improving surgical technique.

The anterior cruciate ligament is a wide connective-tissue band attached with its posterior end to the internal posteromedial surface of the lateral condyle of the femur (Fig. 1) [2, 5, 7]. The attachment site of the anterior cruciate ligament on the femur has the shape of a semicircle, with a straight front edge and a convex posterior one along the edge of the femoral condyle. From the attachment site on the femoral condyle, the anterior cruciate ligament runs in the medial and distal direction to the tibial plateau.

ACL is attached with its distal end to the fossa of the intercondylar eminence of the tibia along the front and inner edges of the lateral tubercle, its front edge passes under the transverse ligament of the meniscus (part of the bundles can be connected to the anterior horn of the lateral meniscus). The length of the anterior cruciate ligament is from 22 to 41 mm, and the width is from 7 to 12 mm [7, 8].

The ACL cross-sectional area increases from the femur to the tibia, measuring 34 mm² proximally, 33 mm² in the middle of the proximal layer, 35 mm² in the center, 38 mm² in the middle of the distal part and 42 mm² distally [7, 8]. Moreover, the area of the attachment on the tibia is 120 % relative to the area of attachment on the femur [7, 8].

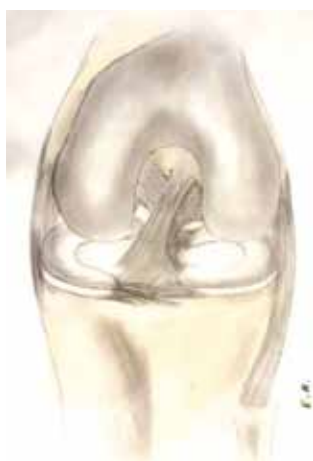

Fig. 1 Location of the anterior cruciate ligament (left knee joint), frontal projection

Girgis and co-authors suggest to distinguish two ACL parts, anteromedial and posterolateral bundles that pass spirally [8]. Other authors distinguish three ACL functional bundles (anteromedial, intermediate and posterolateral [9]. At present, the two-part ACL model is commonly accepted for better presentation and understanding of the knee joint functioning [8, 9].

The anteromedial bundle is oriented more vertically in the frontal plane (approximately 70° to the base line of the knee) while the posterolateral bundle is more horizontal (approximately 55° to the base line of the knee) [8, 9].

When the knee joint is extended, the posterolateral bundle has maximum tension while the anteromedial is relaxed. It is a reverse dynamics in knee flexion; the anteromedial bundle is tensed while posterolateral one is somewhat relaxed. One should realize that it is a simplified presentation of the knee joint kinematics [10].

In addition, Markolf and co-authors reported that the anterior cruciate ligament acts as a

secondary limitation to varus-valgus and rotational displacement [11].

Based on the analyzed literature data, the following main points can be outlined:

- the anterior cruciate ligament develops and is composed of two bundles initially, each of them not only supplements the function of the other but has an extremely important role in stabilizing the knee joint;
- the anterior cruciate ligament has a complex multilayer histological structure, which allows it to indirectly increase elasticity depending on the tensile load; the hormonal level of estrogens plays a role in the strength of the anterior cruciate ligament;
- the complex “femur - anterior cruciate ligament – tibia” plays a role in the kinematics of the knee joint. Therefore, it is necessary to take into account not only the strength of the graft, but also to carefully choose the method of its fixation to the bone;
- the balance of the quadriceps and the complex of the popliteal muscles is of great importance in the biomechanics and stability of the knee joint;
- any reconstruction of the anterior cruciate ligament only partially recovers the biomechanical and morphological component of the normal anatomy and function of the knee joint.

Mechanism, risk factors and programs for prevention of anterior cruciate ligament injury

Identification of the factors associated with an increased risk of anterior cruciate ligament injury during sports and physical activity is a central topic of numerous studies [12–15].

According to the mechanism, most authors distinguish between “contact” (associated with direct exposure to traumatic forces) and “non-contact” (not related to direct impact during motion) mechanisms of anterior cruciate ligament injuries [12, 13]. Moreover, the non-contact mechanism accounts for about 70 to 75 % of all anterior cruciate ligament lesions [13]. Most athletes and young people who lead an active lifestyle and participate in sports events that include running, turning and jumping, have a high risk of anterior cruciate ligament injuries precisely due to the indirect or non-contact mechanism of damage to the anterior cruciate ligament [12, 13]:

- internal rotation of the tibia with valgus deformity in the knee joint and the foot fixed is a typical mechanism leading to the rupture of the anterior cruciate ligament;

- instances of rapid braking, including those involving sharp foot stops to change the direction as well as jumping, turns, twisting and landing and a direct impact on the forefoot [13].

Three of the four sport events having high rates of injuries are female sports. Moreover, ACL injuries in females are 8- to 10-fold more frequent in all sports activities [14–16]. And this is not a casualty. All the studies report that females are more susceptible to injuries of the anterior cruciate ligaments than males. The reasons are not yet clear. However, the investigators revealed the following factors of this regularity:

- a relatively larger frontal angle between the femur and tibia than in males [17];
- the width of the intercondylar notch is narrower [18];
- lower strength of the femoral muscles that stabilize the knee joint by its loading [19];
- coordination in the work of muscles-antagonists of the femur – a weaker response of the muscles of the popliteal tendons in the conditions of a stronger contraction of the quadriceps [20];
- hormonal profile [21, 22].

Recently, the literature focuses on neuromuscular imbalance of the lower limb, a leading issue in assessing the risks of ruptures of the anterior cruciate ligament in athletes [23, 24]. Several predisposing factors are seen in the neuromuscular imbalance:

- 1) ligament dominance – an imbalance between the neuromuscular and ligamentous control of knee joint stability [25];

- 2) the quadriceps muscle dominance – the prevalence of the quadriceps muscle tone over the muscles of the posterior group of the thigh when performing jumps, sudden stops and acceleration in running, that lead to the anterior and rotational displacement of the lower leg relative to the thigh [25];

- 3) limb dominance – more developed muscles of the leading leg in athletes [26];

- 4) dominance of the body – inability of the athlete to control his center of gravity [27].

The combination of these factors and even the presence of one of them increases the risk of anterior cruciate ligament injury. Most programs for the prevention of injuries of the anterior cruciate ligament, used, in particular, for training of young professional athletes are aimed specifically at reducing

or preventing such neuromuscular imbalance. These programs use a multifaceted approach and include components for the preparation of proprioception, plyometric training, and the strengthening of neuromuscular associations [28].

Currently, medical professionals in sports prefer programs composed of different types of exercises aimed at reducing all four factors of neuromuscular imbalance. Sugimoto et al. (2014) showed the effectiveness of such programs, including a variety of exercises for neuromuscular training of athletes [28]. The work of Swart and co-authors is also interesting, showing not only the medical, but also the financial effectiveness of such programs [29].

In addition to the anatomical, functional, and gender factors of damage to the anterior cruciate ligament discussed above, there is a hereditary predisposition [30, 31] and such a factor as a history of anterior cruciate ligament reconstruction in the medical records [27].

The genetically determined features of collagen synthesis have an effect both on the strength of protein bonds in collagen and on the diameter of fibrils [32]. Again, it was proved that genetic characteristics are inherited and more expressed in the female line [33].

A prior history of anterior cruciate ligament reconstruction is a risk factor for both the contralateral knee joint injury and repeated trauma to the knee joint already operated [27, 34]. Patients with damage to the anterior cruciate ligament were 4.4 to 11.3 times, according to some studies up to 30–40 times [35], more susceptible to the damage of the graft or contralateral anterior cruciate ligament over the next year after surgery compared to other athletes [27, 34, 35].

There are also a number of external factors that increase the risk of anterior cruciate ligament injury: weather, athlete's footwear, condition and type of surface for sports activities [36].

To assess the risk of anterior cruciate ligament injury in each case and the associated preventive measures, it is necessary to consider all these factors separately, and a combination of these that may mutually enhance risks [36].

Diagnosis of the anterior cruciate ligament injuries

Clinical examination is an important diagnostic procedure for detection of anterior cruciate ligament injury to establish the correct diagnosis

and subsequent decision making on the choice of a particular treatment protocol. The accuracy of the examination findings is usually evaluated by comparing the positive and negative results of clinical tests, which with a certain degree of probability correspond to one or another type of damage to the anterior cruciate ligament [37–39].

Three main clinical tests are currently used worldwide to diagnose anterior cruciate ligament injuries (Fig. 2):

- 1) anterior drawer test;
- 2) Lachman's test;
- 3) pivot shift test.

The “anterior drawer” test is performed by bending the affected limb to 45 degrees in the hip joint and to 90 degrees in the knee joint. At the same time, the doctor moves the shin forward relative the thigh with two hands while the foot is fixed. In this case, not only the magnitude of the shift is important, but, mostly, the absence of a clear end point of the forward translation.

Test shortcomings that can bring false negative results [38]:

- in acute injury due to effusion, pain and muscle tension during flexion in the knee joint, flexor muscles may act as stabilizers, preventing anterior translation of the tibia;
- second, the anatomy of the knee joint is such that in knee joint flexion, the convex posterior surface of the femoral condyles corresponds to the concave surface of the tibia plateau and posterior horn of the medial meniscus, which also prevents the anterior translation of the tibia relative to the femur;
- false-positive results occur when there is damage to the posterior cruciate ligament [40].

The Lachman test is performed with the patient being supine and the knee joint slightly bent (from 0 to 15 degrees). The physician shifts the lower leg forward relative to the thigh of the injured limb, producing an oppositely directed force with the hands. The test is

considered positive when there is no clear end point with significant anteroposterior shift of the lower leg relative to the femur. Moreover, the final point of motion, described as “soft”, is important [38]. The test has high sensitivity and specificity for acute and chronic injuries of the anterior cruciate ligament, but is not sensitive to partial tear of the anterior cruciate ligament.

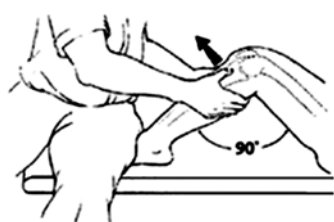The pivot shift test reproduces the lower leg displacement relative to the thigh which patients call “bucking knees”. If the anterior cruciate ligament function is not sufficient, there is anterior subluxation of the tibia even by moderate flexion and rotation what means the rotational displacement or pivot shift test. [38]. False-negative results are possible in partial ACL tear [41, 42].

The principle points of the main clinical tests are the following:

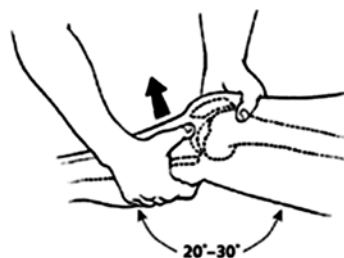
- 1) tests for anterior shift of the lower leg (anterior drawer and Lachman tests) are highly sensitive, especially with chronic anterior instability of the knee joint;
- 2) the pivot shift test has a very high specificity and may indicate the presence of anterior cruciate ligament injury;
- 3) sensitivity and specificity of the tests increase after anesthesia.

Radiological research methods are of great importance in the complex diagnosis of anterior instability of the knee joint. Thus, MRI is of particular significance in the presence of not only complete, but also partial tears of the anterior cruciate ligament [43]. However, it should be understood that any test and any radiological study cannot be considered separately. Only the combined clinical and paraclinical data of the patient may bring absolute confidence in the verification of the diagnosis of anterior cruciate ligament injury. In this regard, the “classical” radiological research methods, such as radiography of the knee joint, remain relevant in terms of differential diagnosis and diagnosis of concomitant injuries [2, 16].

Anterior Drawer Test



Lachman Test



Pivot Test

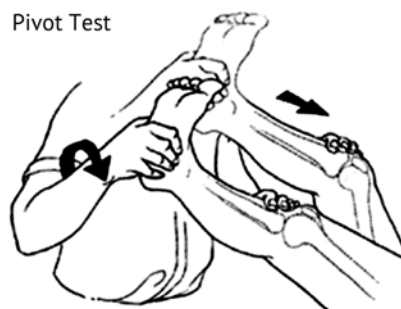


Fig. 2 Main clinical tests to assess the anterior instability of the knee joint

If we consider diagnostic arthroscopy of the knee joint as a method for diagnosing anterior cruciate ligament injuries which undoubtedly has high sensitivity and specificity [2] but one main drawback, it is invasive.

Among non-invasive examination methods, a number of devices for measuring the anterior tibia shift relative to the femur have recently become increasingly important. CT 1000®, CT 2000®, Rolimeter® and Telos® systems are mostly used in clinical practice. They are more accurate in cases of subacute and chronic injury to the anterior cruciate ligament. It should be borne in mind that these devices evaluate only the anterior shift of the lower leg without any rotational evaluation. Their use in combination with other studies is fundamental for diagnosis and therapy [39–42].

Main classifications and types of ACL injuries

Zantop et al. (2007) proposed classifying the cruciate ligament tears in regard to its two bundles (Table 1) [44].

Table 1


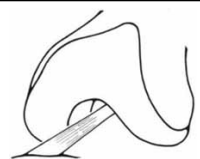




Classification of ACL ruptures in regard to its bundles (Zantop, 2007)

Types of injury	Anteromedial bundle	Posterolateral bundle
Tear off the femur	1	A
Central rupture	2	B
Tear off the tibia	3	C
Stretched, functionally insufficient	4	D
Intact	5	E

Complete or total and partial ruptures of the anterior cruciate ligament can happen [44]. Both bundles are ruptured in a complete pattern, while with the partial rupture, either the anteromedial or posterolateral bundles of the anterior cruciate ligament are torn. The pattern and the resulting condition, anterior instability of the knee joint, determine the tactics and type of surgical treatment in the future. More than 25 years ago, Gächter proposed distinguishing between the following types of total rupture of the anterior cruciate ligament (Table 2) [45].

Table 2

Gächter classification of ACL injuries

	Type I Complete ACL tear with separation of fibres always results in instability and is associated with hemarthrosis of the knee joint
	Type II Intrasyovial rupture, when the synovial membrane remains intact, may appear with one of the ACL bundles injured. MRI signs may seem normal while clinical signs may be one of the symptoms of the anterior or rotational laxity without hemarthrosis
	Type III ACL detachment from the tibia along with the periosteum (may be accompanied with the Segond fracture [44]). It is a rare condition characteristic for young people and may be cured conservatively. In knee joint radiographs, the injury is seen as an avulsion fracture of the intercondylar eminence of the tibia and possible Segond fracture. A puncture of the knee joint in the acute period contains drops of bone marrow along with blood
	Type IV ACL tear off the femoral condyles and its stump. It frequently results in blocking and subsequent flexion contracture of the knee joint. Clinical tests for anterior instability may be thus false-negative
	Type V ACL tear off the femoral condyles and its bundle scarring with the posterior cruciate ligament bundles. Arthroscopy shows none of ACL bundle is in the site of its attachment to the femoral condyle. Clinical tests may also be false-negative and there are difficulties of MRI image interpretation
	Type VI ACL bundles are resorbed completely or partially. Resorption develops within several weeks to several years after primary injury. This is the simplest injury for diagnosis but the most difficult type for the patient type and anterior knee instability. No difficulties in diagnosing with clinical tests and MRI

Later, another classification was proposed, including partial ruptures of the anterior cruciate ligament, also based on morphological features for a better understanding (Fig. 3) [44].

This classification, although it is very complete and detailed, is currently practically not used due to its complexity. For practical use, the American Association of Orthopedic Surgeons (AAOS) developed a simplified classification of injuries of the anterior cruciate ligament in 1997, which turned out to be more convenient for choosing treatment tactics for both partial and complete ruptures of the anterior cruciate ligament (Table 3) [44]:

Injuries of the anterior cruciate ligament are frequently associated with damage to other structures of the knee joint.

- In 96.5 % of cases of posterior cruciate ligament injuries, there is damage to the anterior cruciate ligament or other multi-plane instability [44, 46].

- In 95 % of cases of medial collateral ligament injuries, the anterior cruciate ligament is damaged [44, 47].

- In 26-60 %, one of the menisci is injured along with the anterior cruciate ligament [44, 46].

- Second fracture happens in 9 to 12 % of all injuries of the anterior cruciate ligament [44, 48].

Unfortunately, at present, there is no classification of injuries of the anterior cruciate ligament that is

acceptable and convenient for clinicians and considers both the specifics of its injuries and damage to other structures of the knee joint.

Review on the current methods of surgical treatment of anterior cruciate injuries

The first question any surgeon is faced with is choosing a graft for reconstruction of the anterior cruciate ligament. Currently, the most common are the operations of reconstruction of the anterior cruciate ligament with autografts from the tendon of the patellar ligament (BTB, bone-tendon-bone) or from the tendons of the semi-tendinous and thin muscles (ST-soft tissue) [2, 16, 44, 46, 47, 48, 49]. Most researchers do not find a significant difference; however, in addition to significant differences in the surgical technique, both methods still have their advantages and disadvantages.

The disadvantages of using a BTB autograft include, first, severe pain in the anterior knee part (the place where the tendon of the patellar ligament is harvested), which sometimes lasts for several years, and secondly, a fairly frequent limitation of knee joint extension [49].

The main disadvantages of the ST-autograft include a tendency to more frequent, compared to BTB, repeated ruptures and, accordingly, recurrence of anterior knee joint instability, especially in professional athletes [49].

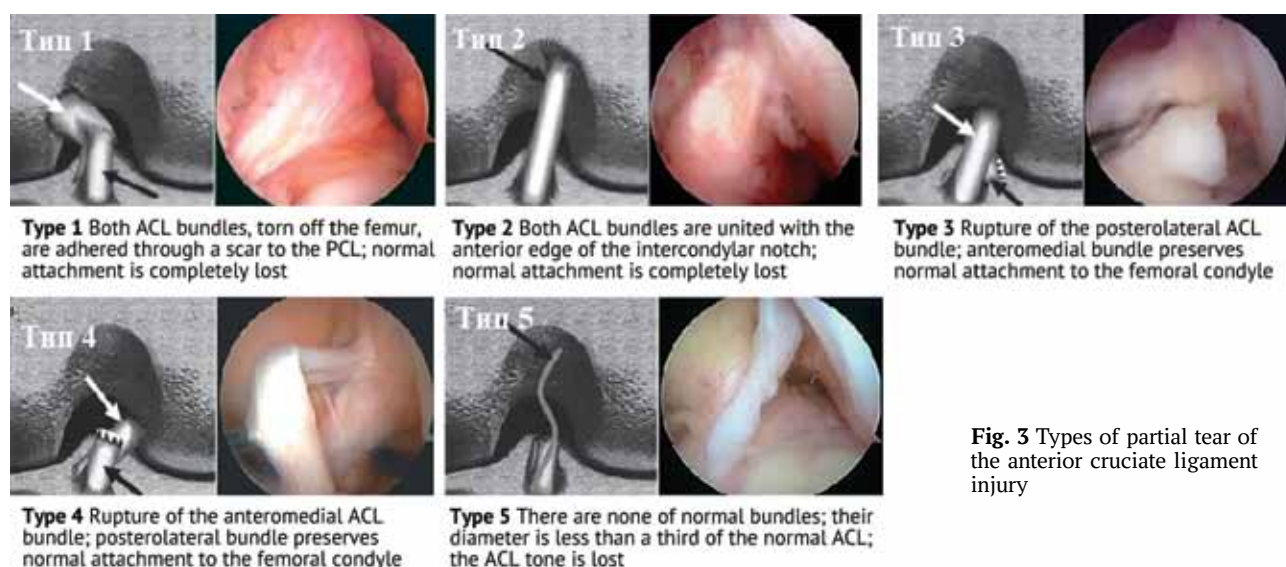


Fig. 3 Types of partial tear of the anterior cruciate ligament injury

Table 3

Classification of ACL injuries (AAOS, 1997)

Injury grade	Features
Grade 1	ACL is stretched slightly but the stability of the knee joint is not affected
Grade 2	ACL partial tear, stretched to the point that it becomes loose (injury to one bundle)
Grade 3	ACL is completely torn, the knee joint is no longer stable

Noyes et al. showed in 1984 that BTB strength reaches 168 % of the original anterior cruciate ligament, which is the best indicator. At the same time, the strength of the semi-tendinous muscle tendon reaches only 70 % of the original (with other autografts even lower) anterior cruciate ligament. However, according to the authors, the strength does not matter in achieving a good result if there is no reliable fixation and strong adhesion to the bone [50]. Another important advantage of BTB is a faster bone-in-bone ingrowth of this autograft within six weeks compared with ST (within 4–6 months). This fact may be important for the high-level athletes in choosing this method for a quick return to sport.

The next no less important point for the surgeon is the choice between reconstruction of both bundles of the anterior cruciate ligament and single-bundle reconstruction. Several biomechanical studies have been carried out, showing that the restoration of both bundles of the anterior cruciate ligament, compared with single-bundle reconstruction, significantly eliminates not only the anterior, but also rotational instability in the injured knee joint, and consequently may reduce the risk of gonarthrosis after surgery. Moreover, with regard to clinical results, there are works both confirming the benefits of restoration of both bundles of the anterior cruciate ligament [51], and suggesting that there is no difference between the results after single-bundle or double-bundle restoration of the anterior cruciate ligament [52].

Ibrahim et al. reported that, although clinically there was no difference between these methods of restoration of the anterior cruciate ligament, nevertheless, when comparing the stability of the knee joint on a CT 1000 apparatus (MEDmetric, San Diego, CA), the results after restoration of both bundles of the anterior cruciate ligament were significantly better [53]. When comparing the stability of the knee joint, Yasuda et al. came to the conclusion that the rotational stability of the knee joint was better after the restoration of both bundles of the anterior cruciate ligament, but there were no significant differences in IKDS scores [54].

Tiamklang et al. conducted an interesting study which showed that there was no difference in the short-term (up to a year) clinical results and the number of complications between double-bundle and single-bundle ACL reconstruction. Nevertheless, they found that the double-bundle method of reconstruction of

the anterior cruciate ligament, first, provided return to the preoperative level of physical activity (91 % versus 82 %); second, there were better clinical results in the long term (more than a year) on the IKDS scale after a double-bundle reconstruction, (94 % versus 90 %). There were also such differences in favor of reconstructing both bundles as a reduction in the risk of meniscus lesions (3.75 % versus 6.7 %) and repeated rupture of the anterior cruciate ligament (0.8 % versus 5.4 %) [53].

Most cases of recurrence of anterior knee joint instability after reconstruction of the anterior cruciate ligament are associated with improper positioning and the formation of the femoral canal [2, 27, 44, 54]. Currently, there are three types of methods for creating the femoral canal, each having its own merits and drawbacks: a transtibial tunnel technique, anteromedial portal, and a femoral tunnel technique "from outside-in" with retrograde drilling.

The main drawbacks of the transtibial technique, when the femoral tunnel is formed along the guide from the tibial tunnel, are difficulties in proper positioning; it is often difficult to target the place of attachment of the original anterior cruciate ligament to the femur [55].

When the femoral tunnel is formed from anteromedial or additional access from inside the knee, the surgeon is forced to bend the knee joint as much as possible, which, first, sharply worsens the visualization of the attachment point of the anterior cruciate ligament to the femur, and second, the posterior wall of the lateral condyle of the femur or even the peroneal nerve may be injured if flexion is insufficient [56].

A drawback of the technique of producing the femoral tunnel from outside inwards, when a tunnel of the required diameter is drilled through a special guide from inwards to outside, is that the retrograde drill may miss the targeted point on the femur, and often a tunnel of a larger diameter than necessary may be drilled [56].

Regardless of the method of tunnel formation, the main point is the correct positioning of the femoral tunnel, and it is also important to treat the remnants of the anterior cruciate ligament as carefully as possible, trying to preserve as many natural fibers as possible to preserve proprioception and better graft revascularization [2, 16, 55].

Another important point is the choice of the method for graft fixation on the femur and tibia. Reliable fixation of the graft to the bone ensures stability in the early postoperative period and, accordingly, enables early rehabilitation of the patient. The fixator itself should not impede autograft ingrowth. Animal studies have shown that the fixator is a weak link for six weeks after surgery using a BTB graft and for 12 weeks after surgery using a ST graft [57], what is very important to consider if biodegradable fixators are used. There are three groups of fixators currently used for the reconstruction of the anterior cruciate ligament (Fig. 4).

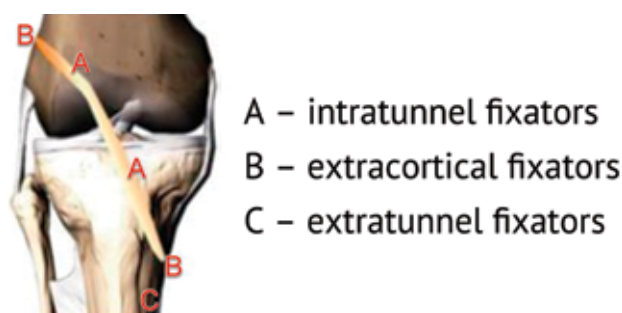


Fig. 4 Variants of fixators for reconstruction of the anterior cruciate ligament

Given the variety of techniques and implants for surgical treatment of anterior instability of the knee joint that currently exist, it is very important for the practitioner to make the right choice of the method or combination of methods for surgical reconstruction of the anterior cruciate ligament in a particular patient. The task is to ensure the stability of the knee joint with the least trauma, which will provide patient's quickest return to the preoperative level of physical activity.

Factors that influence on gonarthrosis incidence after surgical treatment of anterior knee joint instability

Gonarthrosis may develop prematurely after anterior cruciate ligament injuries. And given that there is high incidence of ACL injuries in young people and adolescents leading an active lifestyle, it can be assumed that gonarthrosis may develop at their most productive and socially significant age [2, 24, 29, 58]. Thus, reducing the risk of premature degenerative pathology of the knee joint after ACL injury associated with intraarticular cartilage, menisci, and subsequent recovery, is a clinical priority [58].

However, the following paradox is encountered; according to instrumental methods, the lateral parts of the joint are injured in acute trauma but subsequent arthritic changes primarily are observed in the medial knee.

This suggests that the main role in the development of gonarthrosis after reconstruction of the anterior cruciate ligament is not caused by the consequences of acute injury but by other factors. Changes in the kinematics of the knee joint are significant and, unfortunately, are not fully corrected with the intervention, and these disorders remain significant even if the gait is normal [58].

ACL injuries distort three parameters in the biomechanics of the knee joint. First, there is anterior instability of the knee manifested by excessive anterior shift of the lower leg relative to the thigh; second, the axis of rotation of the knee joint changes and is manifested as a "pivot-shift" symptom; third, synchronization and congruency of the articular surfaces of the medial condyles of the femur and tibia are lost.

In ACL reconstruction, the main emphasis is given to eliminating anterior instability with surgical methods. However, the main load due to the remaining rotational instability falls on the medial meniscus and medial parts of the joint [2, 16]. Subsequently, this leads to the lesions of the medial meniscus and the development of arthritic changes in the medial parts of the knee joint. That is why the preservation of the function of the medial meniscus is the last barrier to the development of gonarthrosis [29, 58] (Table 4).

Table 4

Dependence of gonarthrosis incidence on the type of surgical treatment of the injuries of the medial meniscus and anterior cruciate ligament

Injuries of the medial meniscus and anterior cruciate ligament	Incidence of gonarthrosis 10 years after surgery
Resection of the medial meniscus and rejection of ACL reconstruction	100 %
Resection of the medial meniscus and ACL reconstruction	24–45 %
ACL reconstruction and intact medial meniscus	4–11 %

Based on this, it is obvious that surgical treatment of anterior instability should be aimed at: 1) eliminating the anterior and rotational instability of the knee joint and 2) preserving and protecting menisci and preventing the development of gonarthrosis.

Approaches to rehabilitation and recovery therapy after surgical management of the anterior knee joint instability

A success in recovery of the preoperative level of physical activity after reconstruction of the anterior cruciate ligament is based on a staged individual

rehabilitation of the patient [59]. The tasks of rehabilitation treatment are to restore muscle balance and muscle strength of the limb, proprioception and reduce the risk of re-injury of the anterior cruciate ligament [2, 16, 59].

An adequate strength of the quadriceps femoris is a critical component of recovery after reconstruction of the anterior cruciate ligament. Moreover, deficient quadriceps muscle strength may be a key factor for repeated trauma to the anterior cruciate ligament and relapse of the anterior instability of the knee joint [59].

Immediate postoperative rehabilitation begins on days 2 to 7 after the intervention. The goals of the stage are to restore the range of motion, activate the quadriceps muscle, reduce swelling and pain (an inflammatory process in the knee joint), and ensure safety and efficiency of everyday-life ambulation. Moreover, the function of the quadriceps muscle is of paramount importance [59]. Isokinetic exercises and exercises aimed at restoring movements in the knee joint from 0 to 90 degrees are allowed. In the future, after restoration of the range of motion and quadriceps muscle tone and if inflammation signs in the joint are absent for 3–4 months after the operation, the treadmill and the gym are allowed. No earlier than 4–6 months after surgery, flexion in the knee joint of more than 90 degrees and jumping are allowed, while the tone of the quadriceps muscle should be fully restored, and there should be no signs of inflammation in the joint. Only at the very end of rehabilitation treatment, not earlier than after 6–8 months, exercises, including rotation in the knee joint on a fixed foot and running on rough terrain are allowed. At this stage, exercises specific to the sport that is a priority for the patient are permitted.

The criteria for returning to the preoperative level of physical activity are functional tests, the contralateral limb being a reference [60]. Four standard tests were proposed for determining the patient's readiness to

return to sport: a single hop for distance, a triple hop for distance, a triple hop on the run alternately with the right and left leg, and hops for 6 meters (Fig. 5). All hops should be made at the same distance by both lower limbs, while balance should be maintained without involving the movements of the body and arms. The patient is allowed to start training with the main group of athletes, provided that these tests have been passed.

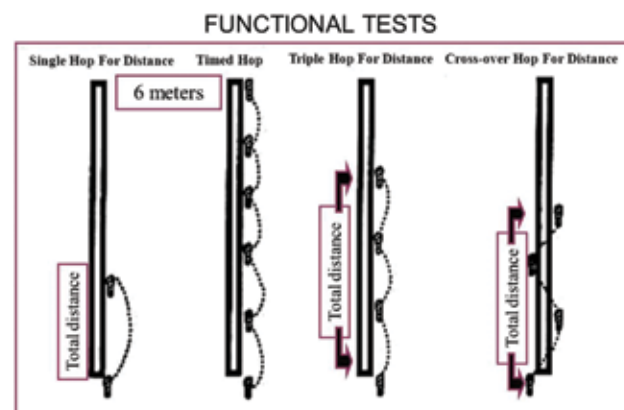


Fig. 5 Functional tests to assess knee function recovery after reconstruction of the anterior cruciate ligament

In addition to functional factors, there are also psychological factors that can distort the results of these tests and delay patients' return to an active lifestyle. Thus, an increased fear to move and a fear of repeated injury were recognized as these factors by many authors [60].

These principles of rehabilitation are the basis of recovery treatment, which allows athletes to return to the preoperative level of physical activity. Moreover, there is no definite program adopted for any specific surgical treatment technique, but only general recommendations.

No doubt, the success of the entire treatment of the anterior instability of the knee joint depends not only on the operation, but also on the efficiency of rehabilitation, including physiotherapy, kinesiotherapy, exercise therapy and psychologist's work.

CONCLUSION

The operation to reconstruct the anterior cruciate ligament is one of the most common procedures in world orthopedic practice. Over the past decades, both indications for this operation and all clinical aspects have significantly expanded and changed, from diagnostic and surgical techniques to the principles of rehabilitation treatment. Despite the relevance and high incidence of the condition, there are controversies to date in the world literature that

point to a number of unresolved problems.

Evidence-based medicine is, in particular, an option for a surgeon to use the best available literature to make a decision about treating patients. Although there is not always an ideal answer for each clinical case, we have attempted to present a relevant and unbiased information on this issue in order to assist practitioners to make the best choice of the method to use, based on current literature.

REFERENCES

- Agel J., Klossner D. Epidemiologic review of collegiate ACL injury rates across 14 sports: national collegiate athletic association injury surveillance system data 2004-05 through 2011-12. *Br. J. Sports Med.*, 2014, vol. 48, pp. 560-560. DOI: 10.1136/bjsports-2014-093494.2.
- Rikun O.V., Khominets V.V., Fedotov A.O. Sovremennye tendentsii v khirurgicheskom lechenii patsientov s razryvami perednei krestobraznoi svyazki (obzor literatury) [Modern tendencies in surgical treatment of patients with the anterior cruciate ligament tears (review of the literature)]. *Travmatologiya i Ortopediya Rossii*, 2017, vol. 23, no. 4, pp. 134-145. (in Russian) DOI 10.21823/2311-2905-2017-23-4-134-145.
- Montalvo A.M., Schneider D.K., Yut L., Webster K.E., Beynnon B., Kocher M.S., Myer G.D. "What's my risk of sustaining an ACL injury while playing sports?" A systematic review with meta-analysis. *Br. J. Sports Med.*, 2018. DOI: 10.1136/bjsports-2016-096274.
- Potach D., Myer G., Grindstaff T.L. Special Consideration: Female athlete and ACL injury prevention. In: *The Pediatric Anterior Cruciate Ligament: Evaluation and Management Strategies*. Cham, Springer International Publishing, 2018, pp. 251-283. DOI: 10.1007/978-3-319-64771-5_24.
- Sugimoto D., Myer G.D., Micheli L.J., Hewett T.E. ABCs of evidence-based anterior cruciate ligament injury prevention strategies in female athletes. *Curr. Phys. Med. Rehabil. Rep.*, 2015, vol. 3, no. 1, pp. 43-49. DOI: 10.1007/s40141-014-0076-8.
- Sanders J.O., Brown G.A., Murray J., Pezold R., Sevarino K. Anterior Cruciate Ligament Injury Prevention Programs. *J. Am. Acad. Orthop. Surg.*, 2017, vol. 25, no. 4, pp. e79-e82. DOI: 10.5435/JAAOS-D-16-00756.
- Beaulieu M.L., Carey G.E., Schlecht S.H., Wojtys E.M., Ashton-Miller J.A. Quantitative comparison of the microscopic anatomy of the human ACL femoral and tibial enthuses. *J. Orthop. Res.*, 2015, vol. 33, no. 12, pp. 1811-1817. DOI: 10.1002/jor.22966.
- Siebold R. Flat ACL anatomy: fact no fiction. *Knee Surg. Sports Traumatol. Arthrosc.*, 2015, vol. 23, no. 11, pp. 3133-3135. DOI: 10.1007/s00167-015-3818-y.
- Suzuki D., Otsubo H. The anatomical features of ACL insertion sites and their implications for multi-bundle reconstruction. In: Ochi M., Shino K., Yasuda K., Kurosaka M., editors. *ACL Injury and Its Treatment*. Tokyo, Springer, 2016, pp. 17-26. DOI: 10.1007/978-4-431-55858-3_2.
- Lord B., Amis A.A. The envelope of laxity of the pivot shift test. In: V. Musahl, J. Karlsson, R. Kuroda, S. Zaffagnini, editors. *Rotatory Knee Instability: An Evidence Based Approach*. Cham, Springer, 2017, Part IV, pp. 223-234. DOI: https://doi.org/10.1007/978-3-319-32070-0_18.
- Englander Z., Stinton S.K., Branch T.P. How to predict knee kinematics during an ACL injury. In: Musahl V., Karlsson J., Krutsch W., Mandelbaum B.R., Espregueira-Mendes J., d'Hooghe P., editors. *Return to Play in Football*. Berlin, Heidelberg, Springer, ESSKA, 2018, pp. 47-61. DOI: https://doi.org/10.1007/978-3-662-55713-6_4.
- Koga H., Muneta T. ACL Injury Mechanisms. In: Ochi M., Shino K., Yasuda K., Kurosaka M., editors. *ACL Injury and Its Treatment*. Tokyo, Springer, 2016, pp. 113-125. DOI: 10.1007/978-4-431-55858-3_10.
- Wetters N.G., Weber A., Wuerz Th.H., Schub D.L. Mechanism of Injury and Risk Factors for Anterior Cruciate Ligament Injury. *Operative Techniques in Sports Medicine*, 2016, vol. 24, no. 1. DOI: 10.1053/j.otsm.2015.09.001.
- Tuominen M., Stuart M.J., Aubry M., Kannus P., Tokola K., Parkkari J. Injuries in women's international ice hockey: an 8-year study of the World Championship tournaments and Olympic Winter Games. *Br. J. Sports Med.*, 2016, vol. 50, no. 22, pp. 1406-1412. DOI: 10.1136/bjsports-2015-094647.
- O'Kane J.W., Gray K.E., Levy M.R., Neradilek M., Tencer A.F., Polissar N.L., Schiff M.A. Shoe and field surface risk factors for acute lower extremity injuries among female youth soccer players. *Clin. J. Sports Med.*, 2016, vol. 26, no. 3, pp. 245-250. DOI: 10.1097/JSM.0000000000000236.
- LaBella C.R., Hennrikus W., Hewett T.E.; Council on Sports Medicine and Fitness, and Section on Orthopaedics. Anterior cruciate ligament injuries: diagnosis, treatment, and prevention. *Pediatrics*, 2014, vol. 133, no. 5, pp. e1437-e1450. DOI: 10.1542/peds.2014-0623.
- Sigward S.M., Cesar G.M., Havens K.L. Predictors of frontal plane knee moments during side-step cutting to 45 and 110 degrees in men and women: Implications for Anterior Cruciate Ligament injury. *Clin. J. Sport. Med.*, 2015, vol. 25, no. 6, pp. 529-534. DOI: 10.1097/JSM.0000000000000155.
- Geng B., Wang J., Ma J.L., Zhang B., Jiang J., Tan X.Y., Xia Y.Y. Narrow intercondylar notch and anterior cruciate ligament injury in female nonathletes with knee osteoarthritis aged 41-65 years in plateau region. *Chin. Med. J.*, 2016, vol. 129, no. 21, pp. 2540-2545. DOI: 10.4103/0366-6999.192771.
- Sturnick D.R., Vacek P.M., DeSarno M.J., Gardner-Morse M.G., Tourville T.W., Slauterbeck J.R., Johnson R.J., Shultz S.J., Beynnon B.D. Combined anatomic factors predicting risk of anterior cruciate ligament injury for males and females. *Am. J. Sports Med.*, 2015, vol. 43, no. 4, pp. 839-847. DOI: 10.1177/0363546514563277.
- Barber-Westin S.D., Noyes F.R. Risk factors for anterior cruciate ligament injuries in the female athlete. In: Noyes F.R., editor. *Noyes' Knee Disorders: Surgery, Rehabilitation, Clinical Outcomes*. Philadelphia, Saunders, 2009, pp. 359-378.
- Shultz S.J. The effect of sex hormones on ligament structure, joint stability and ACL injury risk. In: Hackney A.C., ed. *Sex Hormones, Exercise and Women. Scientific and Clinical Aspects*. Cham, Springer, 2017, pp. 113-138. DOI: 10.1007/978-3-319-44558-8_7.
- Wojtys E.M., Jannausch M.L., Kreinbrink J.L., Harlow S.D., Sowers M.R. Athletic activity and hormone concentrations in high school female athletes. *J. Athl. Train.*, 2015, vol. 50, no. 2, pp. 185-192. DOI: 10.4085/1062-6050-49.3.62.
- Sugimoto D., Myer G.D., Barber Foss K.D., Pepin M.J., Micheli L.J., Hewett T.E. Critical components of neuromuscular training to reduce ACL injury risk in female athletes: meta-regression analysis. *Br. J. Sports Med.*, 2016, vol. 50, no. 20, pp. 1259-1266. DOI: 10.1136/bjsports-2015-095596.
- Hewett T.E., Ford K.R., Xu Y.Y., Khoury J., Myer G.D. Utilization of ACL injury biomechanical and neuromuscular risk profile analysis to determine the effectiveness of neuromuscular training. *Am. J. Sports Med.*, 2016, vol. 44, no. 12, pp. 3146-3151. DOI: 10.1177/0363546516656373.
- Roux E.C. *Evaluation of a Sport-Specific Performance Task Associated with a Lower Extremity Injury Prevention Program*. Master's Theses. University of Connecticut, 2015. Available at: https://opencommons.uconn.edu/gs_theses/774.

26. Read P.J., Oliver J.L., De Ste Croix M.B.A., Myer G.D., Lloyd R.S. A Review of Field-based Assessments of Neuromuscular Control and Their Utility in Male Youth Soccer Players. *J. Strength Cond. Res.*, 2017. DOI: 10.1519/JSC.0000000000002069.
27. Paterno M.V., Rauh M.J., Schmitt L.C., Ford K.R., Hewett T.E. Incidence of second ACL injuries 2 years after primary ACL reconstruction and return to sport. *Am. J. Sports Med.*, 2014, vol. 42, no. 7, pp. 1567-1573. DOI: 10.1177/0363546514530088.
28. Sugimoto D., Myer G.D., Foss K.D., Hewett T.E. Specific exercise effects of preventive neuromuscular training intervention on anterior cruciate ligament injury risk reduction in young females: meta-analysis and subgroup analysis. *Br. J. Sports Med.*, 2015, vol. 49, no. 5, pp. 282-289. DOI: 10.1136/bjsports-2014-093461.
29. Swart E., Redler L., Fabricant P.D., Mandelbaum B.R., Ahmad C.S., Wang Y.C. Prevention and screening programs for anterior cruciate ligament injuries in young athletes: a cost-effectiveness analysis. *J. Bone Joint Surg. Am.*, 2014, vol. 96, no. 9, pp. 705-711. DOI: 10.2106/JBJS.M.00560.
30. Keays S.L., Keays R.C., Newcombe P.A. What predisposes siblings to anterior cruciate ligament injury? Femoral notch width size in siblings with and without ACL injury. *Physiotherapy*, 2015, vol. 101, no. Suppl. 1, pp. e736-e737. DOI: 10.1016/j.physio.2015.03.3599.
31. Westin M., Reeds-Lundqvist S., Werner S. The correlation between anterior cruciate ligament injury in elite alpine skiers and their parents. *Knee Surg. Sports Traumatol. Arthrosc.*, 2016, vol. 24, no. 3, pp. 697-701. DOI: 10.1007/s00167-014-2974-9.
32. O'Connell K., Knight H., Ficek K., Leonska-Duniec A., Maciejewska-Karlowska A., Sawczuk M., Stepień-Słodkowska M., O'Cuinneagain D., Van der Merwe W., Posthumus M., Cieszczyk P., Collins M. Interactions between collagen gene variants and risk of anterior cruciate ligament rupture. *Eur. J. Sport Sci.*, 2015, vol. 15, no. 4, pp. 341-350. DOI: 10.1080/17461391.2014.936324.
33. Johnson J.S., Morscher M.A., Jones K.C., Moen S.M., Klonk C.J., Jacquet R., Landis W.J. Gene expression differences between ruptured anterior cruciate ligaments in young male and female subjects. *J. Bone Joint Surg. Am.*, 2015, vol. 97, no. 1, pp. 71-79. DOI: 10.2106/JBJS.N.00246.
34. Kaeding C.C., Pedroza A.D., Reinke E.K., Huston L.J.; MOON Consortium, Spindler K.P. Risk factors and predictors of subsequent ACL injury in either knee after ACL reconstruction: prospective analysis of 2488 primary ACL reconstructions from the MOON cohort. *Am. J. Sports Med.*, 2015, vol. 43, no. 7, pp. 1583-1590. DOI: 10.1177/0363546515578836.
35. Wiggins A.J., Grandhi R.K., Schneider D.K., Stanfield D., Webster K.E., Myer G.D. Risk of secondary injury in younger athletes after anterior cruciate ligament reconstruction: a systematic review and meta-analysis. *Am. J. Sports Med.*, 2016, vol. 44, no. 7, pp. 1861-1876. DOI: 10.1177/0363546515621554.
36. Weber A.E., Bach B.R., Bedi A. How Do We Eliminate Risk Factors for ACL Injury? In: Musahl V., Karlsson J., Kuroda R., Zaffagnini S., editors. *Rotatory Knee Instability: An Evidence Based Approach*. Cham, Springer, 2017, pp. 465-472. DOI: 10.1007/978-3-319-32070-0_39.
37. Swain M.S., Henschke N., Kamper S.J., Downie A.S., Koes B.W., Maher C.G. Accuracy of clinical tests in the diagnosis of anterior cruciate ligament injury: a systematic review. *Chiropr. Man. Therap.*, 2014, vol. 22, pp. 25. DOI: 10.1186/s12998-014-0025-8.
38. Magnussen R.A., Reinke E.K., Huston L.J.; MOON Group, Hewett T.E., Spindler K.P. Factors associated with high-grade Lachman, pivot shift, and anterior drawer at the time of anterior cruciate ligament reconstruction. *Arthroscopy*, 2016, vol. 32, no. 6, pp. 1080-1085. DOI: 10.1016/j.arthro.2015.11.018.
39. Lange T., Freiberg A., Dröge P., Lützner J., Schmitt J., Kopkow C. The reliability of physical examination tests for the diagnosis of anterior cruciate ligament rupture – a systematic review. *Man. Ther.*, 2015, vol. 20, no. 3, pp. 402-411. DOI: 10.1016/j.math.2014.11.005.
40. Seeber G.H., Wilhelm M.P., Windisch G., Appell Coriolano H.J., Matthijs O.C., Sizer P.S. Cadaveric evaluation of the lateral-anterior drawer test for examining posterior cruciate ligament integrity. *Int. J. Sports Phys. Therapy*, 2017, vol. 12, no. 4, pp. 569-580.
41. Nagai K., Hoshino Y., Nishizawa Y., Araki D., Matsushita T., Matsumoto T., Takayama K., Nagamune K., Kurosaka M., Kuroda R. Quantitative comparison of the pivot shift test results before and after anterior cruciate ligament reconstruction by using the three-dimensional electromagnetic measurement system. *Knee Surg. Sports Traumatol. Arthrosc.*, 2015, vol. 23, no. 10, pp. 2876-2881. DOI: 10.1007/s00167-015-3776-4.
42. Nakamura K., Koga H., Sekiya I., Watanabe T., Mochizuki T., Horie M., Nakamura T., Otabe K., Muneta T. Evaluation of pivot shift phenomenon while awake and under anaesthesia by different manoeuvres using triaxial accelerometer. *Knee Surg. Sports Traumatol. Arthrosc.*, 2017, vol. 25, no. 8, pp. 2377-2383. DOI: 10.1007/s00167-015-3740-3.
43. Brady M.P., Weiss W. Clinical Diagnostic Tests Versus MRI Diagnosis of ACL Tears. *J. Sport. Rehabil.*, 2018, pp. 1-5. DOI: 10.1123/jsr.2016-0188.
44. Ochi M., Dejour D., Nakamae A., Ntigiopoulos P.G. Diagnosis of Partial ACL Rupture. In: Nakamura N., Zaffagnini S., Marx R.G., Musahl V., editors. *Controversies in the Technical Aspects of ACL Reconstruction. An Evidence-Based Medicine Approach*. Berlin, Heidelberg, Springer, 2017, pp. 301-311. DOI: 10.1007/978-3-662-52742-9_28.
45. Gächter A. The various faces of anterior cruciate ligament tears during arthroscopic examination. In: Jacob R.P., Stäubli H.-U., editors. *The knee and the Cruciate Ligaments. Anatomy Biomechanics, Clinical Aspects, Reconstruction, Complications, Rehabilitation*. Berlin, Heidelberg, Springer, 1992, pp. 190-192. DOI: 10.1007/978-3-642-84463-8_16.
46. Jackson T., Ganley Th.J. Treatment of Concomitant Pathology During ACL Reconstruction. In: Parikh S., ed. *The Pediatric Anterior Cruciate Ligament*. Cham, Springer, 2018, pp. 169-181. DOI: 10.1007/978-3-319-64771-5_17.
47. Whelan D., Chowdhry M., Hantes M., Nakamura N., Yonetani Y. Treatment of MCL Injury in Combined ACL/MCL Injury. In: Nakamura N., Zaffagnini S., Marx R.G., Musahl V. *Controversies in the Technical Aspects of ACL Reconstruction. An Evidence-Based Medicine Approach*. Berlin, Heidelberg, Springer, 2017, pp. 371-387. DOI: 10.1007/978-3-662-52742-9_34.
48. Claes S., Luyckx T., Vereecke E., Bellemans J. The Second fracture: a bony injury of the anterolateral ligament of the knee. *Arthroscopy*, 2014, vol. 30, no. 11, pp. 1475-1482. DOI: 10.1016/j.arthro.2014.05.039.
49. Xie X., Liu X., Chen Z., Yu Y., Peng S., Li Q. A meta-analysis of bone-patellar tendon-bone autograft versus four-strand hamstring tendon autograft for anterior cruciate ligament reconstruction. *Knee*, 2015, vol. 22, no. 2, pp. 100-110. DOI: 10.1016/j.knee.2014.11.014.
50. Yanke A., Bell R., Lee A., Shewman E.F., Wang V., Bach B.R. Jr. Regional mechanical properties of human patellar tendon allografts. *Knee Surg. Sports Traumatol. Arthrosc.*, 2015, vol. 23, no. 4, pp. 961-967. DOI: 10.1007/s00167-013-2768-5.

51. Zhang Z., Gu B., Zhu W., Zhu L. Double-bundle versus single-bundle anterior cruciate ligament reconstructions: a prospective, randomized study with 2-year follow-up. *Eur. J. Orthop. Surg. Traumatol.*, 2014, vol. 24, no. 4, pp. 559-565. DOI: 10.1007/s00590-013-1221-2.
52. Irrgang J.J., Tashman S., Moore Ch., Musahl V., West R.V., Oostdyk A., Galvin B., Fu F.H. Comparison of Clinical Outcomes Following Anatomic Single vs. Double-Bundle ACL Reconstruction: A Randomized Clinical Trial. *Orthop. J. Sports Med.*, 2017, vol. 5, no. 7 suppl.6. DOI: 10.1177/2325967117S00248.
53. Irrázaval S., Watson J.H., Albers M., Guenther D., Fu F.H. Double-Bundle Anterior Cruciate Ligament Reconstruction. In: Musahl V., Karlsson J., Kuroda R., Zaffagnini S., eds. *Rotatory Knee Instability: An Evidence Based Approach*. Cham, Springer, 2017, pp. 365-377. DOI: 10.1007/978-3-319-32070-0_31.
54. Yasuda K., Kondo E., Kitamura N. Anatomic Double-Bundle Reconstruction Procedure. In: Ochi M., Shino K., Yasuda K., Kurosaka M., eds. *ACL Injury and Its Treatment*. Tokyo, Springer, 2016, pp. 303-317. DOI: 10.1007/978-4-431-55858-3_25.
55. Dhawan A., Gallo R.A., Lynch S.A. Anatomic tunnel placement in anterior cruciate ligament reconstruction. *J. Am. Acad. Orthop. Surg.*, 2016, vol. 24, no. 7, pp. 443-454. DOI: 10.5435/JAAOS-D-14-00465.
56. Robin B.N., Jani S.S., Marvil S.C., Reid J.B., Schillhammer C.K., Lubowitz J.H. Advantages and disadvantages of transtibial, anteromedial portal, and outside-in femoral tunnel drilling in single-bundle anterior cruciate ligament reconstruction: a systematic review. *Arthroscopy*, 2015, vol. 31, no. 7, pp. 1412-1417. DOI: 10.1016/j.arthro.2015.01.018.
57. Herickhoff P.K., Safran M.R., Yung P., Chan K.-M. Pros and Cons of Different ACL Graft Fixation Devices In: Nakamura N., Zaffagnini S., Marx R.G., Musahl V. *Controversies in the Technical Aspects of ACL Reconstruction. An Evidence-Based Medicine Approach*. Berlin, Heidelberg, Springer, 2017, pp. 277-288. DOI: 10.1007/978-3-662-52742-9_26.
58. Barenius B., Ponzer S., Shalabi A., Bujak R., Norlén L., Eriksson K. Increased risk of osteoarthritis after anterior cruciate ligament reconstruction: a 14-year follow-up study of a randomized controlled trial. *Am. J. Sports Med.*, 2014, vol. 42, no. 5, pp. 1049-1057. DOI: 10.1177/0363546514526139.
59. Thomeé R., Waldén M., Häggglund M. Return to sports after anterior cruciate ligament injury: neither surgery nor rehabilitation alone guarantees success – it is much more complicated. *Br. J. Sports Med.*, 2015, vol. 49, no. 22, pp. 1422. DOI: 10.1136/bjsports-2015-094793.
60. DiFabio M., Slater L.V., Norte G., Goetschius J., Hart J.M., Hertel J. Relationships of Functional Tests Following ACL Reconstruction: Exploratory Factor Analyses of the Lower Extremity Assessment Protocol. *J. Sport. Rehabil.*, 2018, vol. 27, no. 2, pp. 144-150. DOI: 10.1123/jsr.2016-0126.

Received: 23.05.2018

Information about the authors:

1. Evgeniya A. Anastasieva, M.D.,
Tsivyan Novosibirsk Research Institute of Traumatology and Orthopedics, Novosibirsk, Russian Federation,
E-mail: evgeniya.anastasieva@gmail.com
2. Roman O. Simagaev, M.D.,
Autonomous Non-profit Organization NRITO Clinic, Novosibirsk, Russian Federation,
E-mail: simagaev@gmail.com
3. Irina A. Kirilova, M.D., Ph.D.,
Tsivyan Novosibirsk Research Institute of Traumatology and Orthopedics, Novosibirsk, Russian Federation