

Biomechanical aspects of spine sagittal balance in patients with coxarthrosis in total hip replacement (preliminary study)

O.G. Prudnikova, O.K. Chegurov, A.S. Triapichnikov, B.V. Kamshilov

Russian Ilizarov Scientific Centre for Restorative Traumatology and Orthopaedics, Kurgan, Russian Federation

The purpose of the study was to evaluate specific features of spine sagittal balance in patients with coxarthrosis of different etiology before and after total hip replacement (THR). **Materials and methods** Clinical and radiographic evaluation was performed for 46 patients admitted for primary THR. The patients were diagnosed with dysplastic (n = 14), degenerative (n = 26) and posttraumatic (n = 6) coxarthrosis and evaluated preoperatively, on the 7th day postsurgery and at a long-term follow-up. Spinopelvic parameters of sagittal balance, stages of osteoarthritis and cranial displacement of femoral heads according to Crowe were assessed. Clinical evaluation included physical examination, hip function with the Harris Hip Score (HHS), range of motion in the involved hip, relative limb shortening, neurological status, Oswestry questionnaire (ODI) and spinal pain syndrome using the Wong-Baker Faces Pain Rating Scale (2011). A statistical software package of Microsoft Office Excel 2016 was applied for data analysis. Statistical analysis of variance was used to calculate the arithmetic mean (M), error of the arithmetic mean ($\pm m$), the Pearson correlation coefficient r and estimate using the Chaddock scale. The Student's t-test was used to confirm significant differences in the means identifying a significance level. **Results and discussion** Comparative analysis of spinopelvic parameters showed decreased PT and SS with increased LL in patients with dysplastic coxarthrosis. No considerable changes of spinopelvic parameters were revealed in patients with degenerative coxarthrosis. Marked limitations in ROM were seen in patients with dysplastic coxarthrosis. A moderate correlation between ROM of the involved hip and spinopelvic parameters was observed in dysplastic coxarthrosis. No correlation was detected between spinopelvic balance and spinal pain syndrome. **Conclusion** No significant differences in spinopelvic parameters were noted in patients with hip-spine syndrome associated with degeneration. Dysplastic changes can be a predisposing factor for spinopelvic imbalance in THR. Correlation analysis showed that combined joint contracture was involved into the biomechanical aspect of spinopelvic imbalance in dysplastic coxarthrosis. As reported by other researchers, total hip replacement with good functional outcome was not shown to result in significant changes in spinopelvic alignment.

Keywords: spine sagittal balance, dysplastic coxarthrosis, degenerative coxarthrosis, spinopelvic parameters of sagittal balance, total hip replacement

INTRODUCTION

Offierski C.M. and MacNab I. in 1983 first used the term hip-spine syndrome to refer to people with comorbid degenerative pathology in their hip and spine [1]. Studies of sagittal balance identified spino-pelvic parameters characterizing biomechanical and clinical aspects of the hip-spine syndrome and spine-pelvis-hip relationship [2, 3]. Maintaining postural balance includes complex relationship between sensory, motor and biomechanical mechanisms [4]. Postural control can be affected by age-related changes, limited range of motion in the joints and spinal degeneration [2, 6, 7, 8]. There are controversial literature data regarding relationship between sagittal balance characteristics and severity of coxarthrosis.

The purpose of the study was to evaluate specific features of spine sagittal balance in patients with

coxarthrosis of different etiology before and after total hip replacement (THR).

Study design: multicenter prospective cohort study. Level of evidence: III.

Inclusion criteria: Patients with dysplastic, degenerative and posttraumatic arthritis of the hip joint treated with primary THR.

Exclusion criteria: patients with revision THR.

Setting: trauma and orthopaedic departments.

Length of study. The study was performed between April 2017 and December 2017.

Ethics review. The study was produced in accordance with the principles laid down in the 1964 Helsinki Declaration. Patients provided an informed consent on diagnostic procedures, medical interventions and use of the findings for research purposes.

MATERIAL AND METHODS

Clinical and radiographic evaluation was performed for 46 patients admitted for primary THR. The patients were diagnosed with dysplastic ($n = 14$), degenerative ($n = 26$) and posttraumatic ($n = 6$) coxarthrosis and evaluated preoperatively, on the 7th day postsurgery and at a long-term follow-up. The mean patients' age was 52.8 ± 9.7 years with male/female ratio of 22/24.

Total hip replacement technique

THR of the involved joint was produced for all patients. Indications to the procedure included pain being resistant to conservative treatment, limited mobility of the limb and radiological findings. The choice of cemented or uncemented THR was determined by patients' age, systemic diseases, osteoporosis and condition of the femoral bone. THR was uncemented ($n = 37$), hybrid ($n = 7$) and cemented ($n = 2$).

Radiological evaluation

Spinopelvic parameters of sagittal balance included measurements of Cobb angle, lumbar lordosis (LL1, at the level of L1–S1 vertebrae and LL2 at the level of L2–vertebrae), pelvic incidence (PI), pelvic tilt (PT) and sacral slope (SS) due to limited technical capabilities with radiological equipment. Anteroposterior and lateral views were obtained with patients standing without support. Radiological

measurements were made with Surgimap v.2.2.12.1 software. Stages of osteoarthritis was evaluated with radiographs of the hip joints using N.S.Kosinskaya method (1961) [9] and cranial displacement of femoral heads was assessed according to Crowe [10]. Spondylography of the lumbar spine showed severity of degeneration, vertebral displacement and congenital malformations [11, 12].

Clinical examination

Clinical examination included physical evaluation, evaluation of hip function with the Harris Hip Score (HHS), range of motion in the involved hip, relative limb shortening, neurological status (A.A. Skromets, T.A. Skromets, 2002), low back pain disability with Oswestry questionnaire (ODI) and spinal pain syndrome using the Wong-Baker Faces Pain Rating Scale (2011).

Statistical data analysis

A statistical software package of Microsoft Office Excel (2016) was applied for data analysis. Statistical analysis of variance was used to calculate the arithmetic mean (M), error of the arithmetic mean ($\pm m$), the Pearson correlation coefficient r and estimate using the Chaddock scale. The Student's t -test was used to confirm significant differences in the means identifying a significance level.

RESULTS

General characteristics of patients depending on etiology of the condition are presented in Table 1. No comparative analysis was performed for posttraumatic coxarthrosis due to a small patient population and the findings served to demonstrate pathological condition of the cases. Malunited acetabular fracture ($n = 3$), posttraumatic changes in the femoral head ($n = 2$) and nonunion of the femoral neck ($n = 1$) were diagnosed in the group.

Displacement of femoral head was mostly seen in patients with dysplastic coxarthrosis. Relative shortening of the lower limb at the involved side was more significant in dysplastic and posttraumatic groups. Radiographic evaluation with N.S.Kosinskaya method (1961) showed stage 3 osteoarthritis in all the cases.

Spondylography of lumbar spine demonstrated stages 2 and 3 osteochondritis in all the cases with decreased height of intervertebral discs, marginal osseous proliferation and marginal sclerosis (Zecker,

1952). Stable degenerative anterolisthesis stages 1 and 2 were diagnosed in 3 cases (H.W. Meyerding, 1932) [11, 12]. No compression and ischemic osteochondritis manifestations were seen in the study groups.

Limited amplitude of motion in the joint is a major pathogenetic and clinical manifestation of deforming arthritis. All the patients complained of limited ROM in the hip joint. Measurements of the hip ROM is presented in Table 2. Severe changes in the preoperative ROM of the hip were observed in dysplastic group. Preoperative and postoperative evaluation of the hip function with HHS showed equally good outcomes regardless of etiology of the disease (Fig. 1). Preoperative neurologic examination revealed spinal pain of different intensity in all cases. Pain in the lower limb was not measured due to the presence of arthrogenic component. Greater pain intensity was observed in posttraumatic group (Fig. 2).

Table 1

General characteristics of patients

Description	Dysplastic coxarthrosis (n = 14)	Degenerative coxarthrosis (n = 26)	Posttraumatic coxarthrosis (n = 6)
Age, years	47.1 ± 9.2 (from 29 to 68)	56.6 ± 7.6 (from 32 to 70)	49.6 ± 8.8 (from 36 to 67)
Males/females (persons)	3/11	14/12	5/1
Involved side: right/left	9/5	11/15	4/2
Relative shortening of lower limb, % patients	92.8	65.4	100
Relative shortening of lower limb, cm	2.2 ± 1.2 (from 0 to 7)	0.9 ± 0.6 (from 0 to 3)	1.9 ± 0.5 (from 1 to 3)
Spinal pain, % patients	100	100	100
Displacement of femoral head according to Crowe (% patients):			
type 1	–	–	–
type 2	7.1	–	16.6
type 3	14.2	–	–
type 4	7.1	–	–

Table 2

Range of motion in the involved joint

Type of motion	Dysplastic coxarthrosis (n = 14)	Degenerative coxarthrosis (n = 26)	Posttraumatic coxarthrosis (n = 6)	Normal values [13]
Flexion, °	101.1 ± 11.9 (from 75 to 140)	101.1 ± 9.6 (from 75 to 130), p = 0.09*	98.3 ± 7.1 (from 75 to 140)	120–140
Extension, °	2.8 ± 4.5 (from 0 to 20)	2.1 ± 3.3 (from 0 to 20), p = 0.07*	11.6 ± 1.9 (from 10 to 15)	10–15
Abduction, °	20.0 ± 8.0 (from 5 to 40)	23.3 ± 9.2 (from 10 to 35), p = 0.03*	21.6 ± 7.6 (from 10 to 40)	40–45
Adduction, °	13.2 ± 5.6 (from 0 to 30)	16.1 ± 5.8 (from 5 to 30), p = 0.02*	49.1 ± 32.1 (from 5 to 90)	20–30
External rotation, °	9.2 ± 2.4 (from 0 to 20)	9.5 ± 0.7 (from 0 to 10), p = 0.08*	10.0 ± 0	40–45
Internal rotation, °	0.4 ± 0.6 (from 0 to 5)	0.2 ± 0.3 (from 0 to 5), p = 0.06*	2.5 ± 2.8 (from 0 to 10)	40

* – significant differences in preoperative measurements in dysplastic and degenerative coxarthrosis groups identified with the Student's t-test

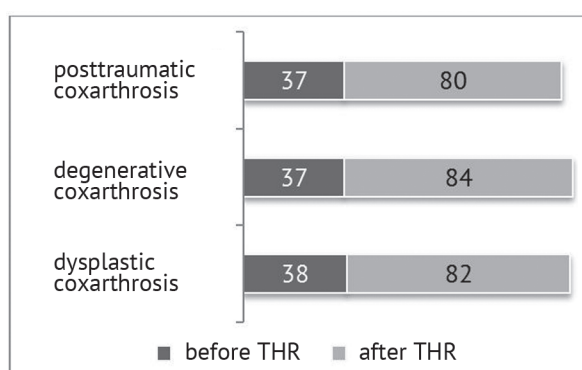


Fig. 1 Diagram of hip function with the Harris Hip Score (HHS) before and after THR

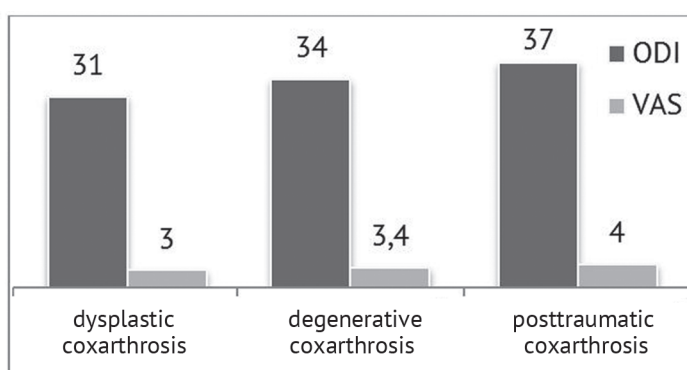


Fig. 2 Diagram of preoperative low back pain disability with Oswestry questionnaire (ODI) and spinal pain on VAS scoring system

ODI and VAS scores were difficult to interpret prior to patients' discharge due to multifactorial pain syndrome after 7–8 postoperative days. ODI score measured 33.4 ± 5.8 in dysplastic group, 33.5 ± 9.6 in degenerative patients and 35.0 ± 5.1 in posttraumatic group. Pain intensity scored 3.2 ± 0.8 in dysplastic

coxarthrosis, 2.7 ± 0.6 in degenerative group and 3.3 ± 0.5 in posttraumatic cases. Scoliosis was diagnosed preoperatively in 50 % of dysplastic and posttraumatic cases and 27 % of degenerative patients. Preoperative and postoperative radiological measurements of coronal balance and spinopelvic relationship are given in Table 3.

Table 3

Radiological measurements of coronal and sagittal balance of patients at stages of treatment

Parameters of evaluation	Dysplastic coxarthrosis		Degenerative coxarthrosis		Posttraumatic coxarthrosis	
	pre-op (n = 14)	post-op (n = 10)	pre-op (n = 24)	post-op (n = 24)	pre-op (n = 6)	post-op (n = 6)
Scoliosis , °, Cobb angle	12.5 ± 8.9 (from 0 to 46.7)	10.1 ± 8.5 (from 1.5 to 46.4), p = 0.08*	9.1 ± 5.1 (from 0 to 16.7), p = 0.06**	8.3 ± 3.7 (from 0 to 13.4), p = 0.09*	5.4 ± 2.2 (from 0 to 10.4)	2.7 ± 0.9 (from 1.2 to 4.7)
LL1 , L1-S1, °	52.2 ± 6.9 (from 38.7 to 75.1)	47.2 ± 5.9 (from 36 to 58.3), p = 0.01*	47.9 ± 8.5 (from 18.9 to 78.9), p = 0.02**	47.9 ± 9.3 (from 21.8 to 80.7), p = 0.09*	52.5 ± 5.9 (from 40.9 to 66.2)	52.1 ± 5.7 (from 42.5 to 61.8)
LL2 , L2-S1, °	49.4 ± 6.4 (from 34.8 to 67.1)	45.6 ± 5.1 (from 35.6 to 57.8), p = 0.02*	43.3 ± 8.7 (from 17.5 to 68.9), p = 0.09**	43.1 ± 8.5 (from 17.6 to 70.7), p = 0.09*	49.4 ± 5.7 (from 41.1 to 66.3)	48.9 ± 5.9 (from 36.4 to 61.2)
PI (pelvic incidence), °	42.3 ± 6.0 (from 24.7 to 53.1)	42.1 ± 5.7 (from 24.7 to 53.1), p = 0.03*	47.2 ± 7.3 (from 27.6 to 78.7), p = 0.01**	45.4 ± 8.0 (from 25.8 to 78.7), p = 0.01*	46.1 ± 7.2 (from 27.9 to 64.7)	46.1 ± 7.2 (from 27.9 to 64.7)
PT (pelvic tilt), °	6.5 ± 5.9 (from 10.8 to 17.2)	3.3 ± 5.7 (from 10.8 to 15.2), p = 0.04*	12.0 ± 4.0 (from 2.8 to 23.5), p = 0.02**	10.2 ± 5.4 (from 3.2 to 25.5), p = 0.06*	8.7 ± 4.7 (from 0 to 15.7)	7.5 ± 7.0 (from 8.6 to 20.4)
SS (sacral slope), °	35.7 ± 3.8 (from 27.9 to 52)	36.1 ± 2.9 (from 32 to 42.1), p = 0.08*	35.2 ± 5.8 (from 18.7 to 60.8), p = 0.07**	36.2 ± 7.3 (from 17.1 to 60.8), p = 0.07*	37.4 ± 6.0 (from 27.2 to 54.9)	38.6 ± 3.1 (from 32.3 to 46.8)

* – significant differences in pre-op and post-op measurements in the groups identified with the Student's t-test; ** – significant differences in preoperative measurements in dysplastic and degenerative coxarthrosis groups identified with the Student's t-test.

Pearson's correlation coefficient was used to measure preoperative relationship between sagittal balance and amount of limb shortening and amplitude of motion in the involved hip joint in dysplastic and degenerative groups. A weak correlation between the amount of limb shortening and scoliosis was detected in dysplastic patients. Comparison of the hip ROM and spinopelvic measurements showed moderate correlation ($r > 0.5$) in extension – lumbar lordosis, abduction – pelvic incidence, adduction – lumbar lordosis, adduction – pelvic incidence. Only extension in the joint was shown to have a weak correlation with lumbar lordosis ($r = 0.4$) in degenerative

group. Comparison of spinal pain and sagittal balance measurements showed a weak correlation with lumbar lordosis LL1 и LL2 and pelvic tilt PT ($r = 0.4$). Residual shortening of lower limb of 1.5 cm to 4 cm was observed in 3 dysplastic cases after THR.

Long-term outcomes

Outcomes were evaluated at 161.0 ± 16.1 days (range, 96 to 196) postsurgery in 16 patients only due to the economic reasons (a need of traveling expenses for a follow-up visit). Clinical and radiological evaluation was performed without grouping because of a small number of observations available (Table 4).

Table 4

Clinical and radiological characteristics of patients prior to THR and a long-term follow-up

Parameters of evaluation	Pre-op (n = 46)	161.0 ± 16.1 days postsurgery (n = 16)
scoliosis, °, Cobb angle	5.2 ± 6.3	2.4 ± 2.9; p = 0.1*
LL1, L1-S1, °	49.9 ± 8.2	50.6 ± 5.2; p = 0.1*
LL2, L2-S1, °	46.1 ± 8.1	46.5 ± 5.8; p = 0.3*
PT (pelvic tilt), °	9.8 ± 5.3	11.4 ± 6.7; p = 0.3*
SS (sacral slope), °	37.5 ± 5.4	37.1 ± 4.7; p = 0.2*
ODI	34 ± 9.8	28.1 ± 7.4; p = 0.09*
Spinal pain, % patients	100	100
VAS	3.3 ± 0.9	2.2 ± 0.7; p = 0.01*

* – significant differences in preoperative and postoperative measurements in the groups identified with the Student's t-test.

The comparative analysis of spinopelvic balance has low significance with no tendency to dynamics in the findings observed. Improved pain intensity

and Oswestry score indicated to improved overall functional condition of patients despite persisting spinal pain.

DISCUSSION

Biomechanical aspects of hip-spine syndrome include flexion contracture of the hip joint leading to pelvic anteversion, re-distribution of loading on lumbar spine and hyperlordosis, foraminal stenosis with resultant spinal pain [1, 14]. Measurements of spinopelvic balance are reported to be different in degenerative and secondary (secondary to dysplasia and subluxation) changes in the hip joints [15]. We found no publications on comparative analysis of sagittal balance in patients with coxarthrosis of different etiology.

Dysplastic coxarthrosis is a special type of degenerative disorder of the hip joint manifesting itself in a deformity, disarrangement and lack of conformity between all the components and structures [16]. Typical morphological characteristics include tilted acetabular roof, impaired configuration of the superior edge, shallowness and altered shape, underdeveloped anterior edge, deformity of the proximal femur and imbalance of tendons and muscles of the joint [16–21]. Flexion, adduction and rotation contractures of the hip joints, shortening of the involved limb, regular pain, severe limping and disturbed supportability of the limb are major clinical manifestations of stages III and IV dysplastic coxarthrosis [18].

Degenerative coxarthrosis is characterized by normal length of the femoral head, absence of excessive anteversion of the head and its displacement, flat and deformed head, sharp decrease in the articular space or its absence, osteophytes and proliferation of the greater trochanter. Clinical manifestations also include pain and limited mobility of the involved limb.

The pelvic incidence PI is formed during childhood and anatomically constant for each individual being independent on body position [22–24]. The SS and PT parameters are positional and dependent on position of pelvis relative to the hip joints. When the pelvis rotates posteriorly (in retroversion) the SS decreases and the PT increases, and when the pelvis rotates anteriorly (in anteversion) the SS increases and the PT decreases [2, 24, 25]. A close relationship between the anatomical positional parameters of SS and PT and constant parameter of PT was first described by Legaye et al. in 1998 [26]. The PT appears to play

the main role in the sagittal imbalance with the knees subsequently taking the role [27, 28].

The influence of the pathological state of the hip joints on the spinopelvic alignment was investigated by many authors [15, 29, 30, 31]. However, the data appear to be incomparable in most publications. Parameter values are dependent on age, stage of the disease, presence of joint dislocation and spinal pain [7, 29, 32–37]. Types of vertical postures (normal, with excessive pelvic anteversion and hyperlordosis, with pelvic retroversion and flat lordosis) [23, 38, 39] were identified in study of relationships of the lumbar spine and pelvis in patients with hip-spine syndrome based on general classifications of sagittal balance [3, 40, 41]. Evident osteoarthritis of the hip joints has been shown to result in either minimal sagittal imbalance or no changes at all [30, 34]. The sagittal balance of the spine can be compensated even in bilateral developmental dislocation of the hip [31]. No studies have been performed to compare the data with etiology of the disease and limited range of motion in the joint. Comparative analysis of preoperative measurements of spinopelvic balance and the reported findings is presented in Table 5.

Comparative analysis of the series presented has shown decrease in spinopelvic measurements of the PT and SS with increase in the LL in patients with dysplastic coxarthrosis that can be ascribed to pathomorphological and clinical manifestations of the disease. Like other authors we found no statistically significant changes in spinopelvic parameters in patients with degenerative coxarthrosis compared with those of healthy individuals of similar age and patients in other series with similar nosology reporting spinal pain. Measurements of the sagittal balance reported by Shnaider et al. (2016) and included in the Table were obtained in patients with Crowe [42] grade IV dysplastic hip joint whereas our findings showed displacement of the femoral head grades II–IV only in 28.5 % of the cases with dysplastic coxarthrosis. The hip joints appeared to play the key role in biomechanical mechanism of compensation of impaired spinopelvic balance [28, 48, 49, 50].

Table 5

Comparative analysis of preoperative measurements of spinopelvic balance

Parameters	Normal values	Dysplastic coxarthrosis grades III–IV [15, 42]	The series presented	Degenerative coxarthrosis grades III–IV [34, 43, 44]	The series presented
Age, years	41–60 [45]	56.3 ± 9.1 [15] 42.43 ± 15.01 [42]	41.1 ± 9.2	males 61.7 ± 6.4 females 60.3 ± 7.9 [43] 59.1 ± 8.5 [34] 64.7 ± 4.8 [44]	56 ± 7.8
LL , L1–S1, °	59 ± 8 [35] from 41 (males) to 46 (females) ± 11 [46] 26–76 [47]	34.7 ± 10.0 (L1 L5, °) [15] 68.86 ± 6.20 [42]	52.2 ± 6.9	49.0 (from 41.0 to 68.0) [43] 50.4 ± 11.9 [34] 52.93 ± 6.74 [44]	47.9 ± 8.5
PI (pelvic incidence), °	53 ± 8 [45]	51.57 ± 19.90 [42]	42.3 ± 6.0	50.0 (from 35.0 to 60.0) [43] 48.3 ± 12.1 [34] 49.27 ± 8.84 [44]	47.2 ± 7.3
PT (pelvic tilt), °	14 ± 6 [45]	19.86 ± 12.75 [42]	6.5 ± 5.9	11.0 (from 7.0 to 23.0) [43] 9.6 ± 9.0 [34] 8.8 ± 8.48 [44]	12.0 ± 4.0
SS (slope of sacrum), °	40 ± 7 [45]	42.3 ± 9.5 [15] 53.57 ± 11.31 [42]	35.7 ± 3.8	36.0 (from 31.0 to 42.0) [43] 39.1 ± 10.7 [34] 41.13 ± 5.59 [44]	35.2 ± 5.8

Researches on the relationship between the hip and the spine in hip-spine syndrome in different patients' positions (sitting, standing) showed the correlation between sagittal balance parameters and mobility of the femoral heads [8, 21, 51, 52]. Subjective limitations of the mobility and analysis of amplitudes in the joint in our series confirmed presence of contractures in the involved joint. Patients with dysplastic coxarthrosis demonstrated more evident limitations in the hip ROM. Comparison of the hip ROM and spinopelvic measurements showed moderate correlation ($r > 0.5$) in extension – lumbar lordosis, abduction – pelvic incidence, adduction – lumbar lordosis, adduction – pelvic incidence. Only extension in the joint was shown to have a weak correlation with lumbar lordosis ($r = 0.4$) in degenerative group. VAS, ODI and HHS scores at stages of treatment are presented in Table 6. We did not group patients by etiology of the disease due a small patient population at a long-term follow-up.

Spinal pain and low back pain disability with ODI score persisted following THR but were less evident. Spinal pain was reported to relieve after THR [43] and the factors could be viewed as independent [34]. We detected no correlation between spinopelvic balance and spinal pain syndrome. No significant differences were observed in spinopelvic parameters of patients with degenerative coxarthrosis preoperatively and at 7 days of THR. Patients with dysplastic arthritis

exhibited improved coronal balance, decrease in compensatory lordosis and the PT and increase in the SS. No significant differences in the spinopelvic measurements were noted at 161.0 ± 16.1 days with improved VAS and ODI scores.

Evaluation of sagittal balance of 28 patients with degenerative coxarthrosis revealed no statistically significant differences in the spinopelvic measurements reported by K. Eyvazov et al. (2016) [43]. The same findings could be found in other publications [30, 44]. M. Stefl et al. (2017) reported no sagittal imbalance in 90 % of THR cases. A greater correlation was found between the sagittal balance and the position of acetabular component [21]. Most severe articular changes, contractures and greater limb length discrepancy were observed in patients with dysplastic coxarthrosis [53, 54, 55]. Patients with spondylodesis were considered to be at a higher risk of sagittal imbalance due to limited spinal mobility and low compensatory capacity with balance correction. Preoperative planning must include implantation of the pelvic component in this group of patients [8, 44].

The series presented first included comparative analysis of spinopelvic parameters of the sagittal balance depending on etiology of coxarthrosis. The parameters were compared with amplitude of motion in the hip joint and pain and detected changes biomechanically substantiated.

Table 6

Clinical findings at stages of treatment

Series	ODI		VAS		Harris Hip Score (HHS)	
	pre-op	post-op	pre-op	post-op	pre-op	post-op
Ben-Galim P. et al., 2007 [30]	36.72	19.8	5.04	3.64	45.7	86
Eyvazov K. et al., 2016 [43]	54	34	6	3	–	–
Piazzolla A. et al., 2017 [44]	49.3 ± 19.3	27.8 ± 7.4	5.3 ± 1.6	1.1 ± 0.9	42.4 ± 12	80.2 ± 10.2
The series presented	34 ± 9.8	28.6 ± 7.4	3.3 ± 0.9	2.8 ± 0.7	37.5 ± 5.4	81.2 ± 6.7

CONCLUSION

No significant differences in spinopelvic parameters were noted in patients with hip-spine syndrome associated with degeneration in comparison with parameters of healthy individuals of similar age and patients in other series with similar pathology. Patients with dysplastic coxarthrosis showed decrease in the PT and SS with increased LL that could be ascribed to morphological and clinical manifestations of the disease. Correlation analysis showed that

combined joint contracture was involved into the biomechanical aspect of spinopelvic imbalance in dysplastic coxarthrosis. Dysplastic changes can be a predisposing factor for spinopelvic imbalance in THR. As reported by other researchers, total hip replacement with good functional outcome was not shown to result in significant changes in spinopelvic alignment. The work requires continuation to provide comparative analysis of results.

REFERENCES

1. Offierski C.M., MacNab I. Hip-spine syndrome. *Spine*, 1983, vol. 8, no. 3, pp. 316-321.
2. Schwab F., Lafage V., Boyce R., Skalli W., Farcy J.P. Gravity line analysis in adult volunteers: age-related correlation with spinal parameters, pelvic parameters, and foot position. *Spine*, 2006, vol. 31, no. 25, pp. E959-E967. doi:10.1097/01.brs.0000248126.96737.0f.
3. Lamartina C., Berjano P. Classification of sagittal imbalance based on spinal alignment and compensatory mechanisms. *Eur. Spine J.*, 2014, vol. 23, no. 6, pp. 1177-1189. DOI:10.1007/s00586-014-3227-9.
4. Buckland A.J., Vigdorchik J., Schwab F.J., Errico T.J., Lafage R., Ames C., Bess S., Smith J., Mundis G.M., Lafage V. Acetabular anteversion changes due to spinal deformity correction: bridging the gap between hip and spine surgeons. *J. Bone Joint Surg. Am.*, 2015, vol. 97, No 23, pp. 1913-1920. DOI:10.2106/JBJS.O.00276.
5. Barrey C., Roussouly P., Perrin G., Le Huec J.C. Sagittal balance disorders in severe degenerative spine. Can we identify the compensatory mechanisms? *Eur. Spine J.*, 2011, vol. 20, no. Suppl. 5, pp. 626-633. DOI:10.1007/s00586-011-1930-3.
6. Endo K., Suzuki H., Tanaka H., Kang Y., Yamamoto K. Sagittal spinal alignment in patients with lumbar disc herniation. *Eur. Spine J.*, 2010, vol. 19, no. 3, pp. 435-438. DOI: 10.1007/s00586-009-1240-1.
7. Yang X., Kong Q., Song Y., Liu L., Zeng J., Xing R. The characteristics of spinopelvic sagittal alignment in patients with lumbar disc degenerative diseases. *Eur. Spine J.*, 2014, vol. 23, no. 3, pp. 569-575. DOI: 10.1007/s00586-013-3067-z.
8. Furuhashi H., Togawa D., Koyama H., Hoshino H., Yasuda T., Matsuyama Y. Repeated posterior dislocation of total hip arthroplasty after spinal corrective long fusion with pelvic fixation. *Eur. Spine J.*, 2017, vol. 26, no. Suppl. 1, pp. 100-106. DOI: 10.1007/s00586-016-4880-y.
9. Kosinskaia N.S. *Degenerativno-distroficheskie porazheniia kostno-sustavnogo apparata. Klinicheskaia rentgenodiagnostika i ekspertiza trudosposobnosti* [Degenerative-dystrophic involvements of the osteoarticular system. Clinical roentgen diagnosis and working capacity examination]. L., Medgiz, 1961, 245 p. (in Russian)
10. G Rowe J.F., Mani V.J., Ranawat C.S. Total hip replacement in congenital dislocation and dysplasia of the hip. *J. Bone Joint Surg. Am.*, 1979, vol. 61, no. 1, pp. 15-23.
11. Tager I.L. *Rentgenodiagnostika zabolevanii pozvonochnika* [Roentgen diagnosing the spine diseases]. M., Meditsina, 1983, 208 p. (in Russian)
12. Iumashev G.S., Furman M.E. *Osteokhondrozy pozvonochnika. 2-e izd.* [Osteochondroses of the spine. 2nd Ed.]. M., Meditsina, 1984, 382 p. (in Russian)
13. Solomon L., Warwick D., Nayagam S. *Apley's System of Orthopaedics and Fractures*. 2010. (Russ. ed.: Solomon L., Uorik D., Niagam S. *Ortopediia i Travmatologiya po Epli*. V 3 ch. M., Izd-vo Panfilova, 2015, part 2, 368 p.).
14. Kudiasheva A.L., Shapovalov V.M., Averkiev V.A., Nadulich K.A., Teremshonok A.V., Rezvantshev M.V., Kuzovinskii P.A., Miroevskii F.V., Kapilevich B.Ia. Razvitie degenerativno-distroficheskikh izmenenii

- pozvonochnika u bolnykh s koksartrozom i narusheniem sagittalnogo pozvonочно-tazovogo balansa [Development of the spine degenerative-dystrophic changes in patients with coxarthrosis and the disorder of sagittal spinopelvic balance]. *Vestnik Rossiiskoi Voenno-meditsinskoi Akademii*, 2013, no. 3 (43), pp. 1-5. (in Russian)
15. Okuda T., Fujita T., Kaneuji A., Miaki K., Yasuda Y., Matsumoto T. Stage-specific sagittal spinopelvic alignment changes in osteoarthritis of the hip secondary to developmental hip dysplasia. *Spine*, 2007, vol. 32, no. 26, pp. E816-E819. DOI: 10.1097/BRS.0b013e31815ce695.
 16. Korzh A.A., Tikhonenkov E.S., Andrianov V.L., Miteleva Z.M., Pozdnykin Iu.I. *Displasticheskii koksartroz* [Dysplastic Coxarthrosis]. M., Meditsina, 1986, 208 p. (in Russian)
 17. Norkin I.A., Petrov A.B., Zhadenov I.I., Kovaleva I.D., Ruzanov V.I., Blinnikova V.V., Ovchinnikova N.M. Biologicheskaya model displasticheskogo koksartroza (eksperimentalnoe issledovanie) [The biological model of dysplastic coxarthrosis (An experimental study)]. *Travmatologiya i Ortopediya Rossii*, 2006, no. 4 (42), pp. 59-63. (in Russian)
 18. Lebedev V.F., Dmitrieva L.A., Arsentev L.I. Kliniko-rentgenologicheskie osobennosti displasticheskogo koksartroza III-IV stadii [Clinical-roentgenological characteristics of III-IV Stage dysplastic coxarthrosis]. *Biulleten VSNTs SO RAMN*, 2013, no. 1 (89), pp. 49-53. (in Russian)
 19. Tugizov B.E., Khamraev A.Sh., Khamraev Sh.Sh., Nurimov G.K. Totalnoe endoprotezirovanie pri displasticheskom koksartroze [Total hip replacement for dysplastic coxarthrosis]. *Genij Ortopedii*, 2013, no. 2, pp. 37-41. (in Russian)
 20. Yoshida M., Konishi N. Subchondral cysts arise in the anterior acetabulum in dysplastic osteoarthritic hips. *Clin. Orthop. Relat. Res.*, 2002, no. 404, pp. 291-301. DOI: 10.1097/00003086-200211000-00044.
 21. Stefl M., Lundergan W., Heckmann N., McKnight B., Ike H., Murgai R., Dorr L.D. Spinopelvic mobility and acetabular component position for total hip arthroplasty. *Bone Joint J.*, 2017, vol. 99-B, no. 1 Supple A, pp. 37-45. DOI: 10.1302/0301-620X.99B1.BJJ-2016-0415.R1.
 22. Prodan A.I., Radchenko V.A., Khvisiuk A.N., Kutsenko V.A. Zakonomernosti formirovaniia vertikalnoi osanki i parametry sagittalnogo pozvonочно-tazovogo balansa u patsientov s khronicheskoi liumbalgiei i liumboishalgiei [Regularities of forming vertical posture and the parameters of sagittal spinopelvic balance in patients with chronic lumbalgia and lumbischialgia]. *Khirurgiya Pozvonochnika*, 2006, no. 4, pp. 61-69. (in Russian)
 23. Averkiev V.A., Kudiashev A.L., Artiukh V.A., Nadulich K.A., Teremshonok A.V., Nagornyi E.B. Osobennosti sagittalnykh pozvonочно-tazovykh vzaimootnoshenii u patsientov s koksovertebralnym sindromom [Characteristics of sagittal spinopelvic relations in patients with the coxovertebral syndrome]. *Khirurgiya Pozvonochnika*, 2012, no. 4, pp. 49-54. (in Russian)
 24. Cil A., Yazici M., Uzumcugil A., Kandemir U., Alanay A., Alanay Y., Acaroglu R.E., Surat A. The evolution of sagittal segmental alignment of the spine during childhood. *Spine*, 2005, vol. 30, no. 1, pp. 93-100.
 25. Sudhir G., Acharya S., K L K, Chahal R. Radiographic Analysis of the Sacropelvic Parameters of the Spine and Their Correlation in Normal Asymptomatic Subjects. *Global Spine J.*, 2016, vol. 6, no. 2, pp. 169-175. DOI: 10.1055/s-0035-1558652.
 26. Legaye J., Duval-Beaupère G., Hecquet J., Marty C. Pelvic incidence: a fundamental pelvic parameter for three-dimensional regulation of spinal sagittal curves. *Eur. Spine J.*, 1998, vol. 7, no. 2, pp. 99-103. DOI: 10.1007/s005860050038.
 27. Lafage V., Schwab F., Patel A., Hawkinson N., Farcy J.P. Pelvic tilt and truncal inclination: two key radiographic parameters in the setting of adults with spinal deformity. *Spine*, 2009, vol. 34, no. 17, pp. E599-E606. DOI: 10.1097/BRS.0b013e3181a219.
 28. Lenke L., Boachie-Adjei O., Wang Y. Spinal Osteotomy. M., SPb., 2016. (Russ. ed.: Lenke L., Boshi-Adzhei O., Vang Ia. *Osteotomii Pozvonochnika*. M., SPb., BINOM, 2016, 232 p. (in Russian)).
 29. Yoshimoto H., Sato S., Masuda T., Kanno T., Shundo M., Hyakumachi T., Yanagibashi Y. Spinopelvic alignment in patients with osteoarthritis of the hip: a radiographic comparison to patients with low back pain. *Spine*, 2005, vol. 30, no. 14, pp. 1650-1657.
 30. Ben-Galim P., Ben-Galim T., Rand N., Haim A., Hipp J., Dekel S., Floman Y. Hip-spine syndrome: the effect of total hip replacement surgery on low back pain in severe osteoarthritis of the hip. *Spine*, 2007, vol. 32, no. 19, pp. 2099-2102. DOI: 10.1097/BRS.0b013e318145a3c5.
 31. Matsuyama Y., Hasegawa Y., Yoshihara H., Tsuji T., Sakai Y., Nakamura H., Kawakami N., Kanemura T., Yukawa Y., Ishiguro N. Hip-spine syndrome: total sagittal alignment of the spine and clinical symptoms in patients with bilateral congenital hip dislocation. *Spine*, 2004, vol. 29, no. 21, pp. 2432-2437.
 32. Mac-Thiong J.M., Berthodaud E., Dimar J.R. 2nd, Betz R.R., Labelle H. Sagittal alignment of the spine and pelvis during growth. *Spine*, 2004, vol. 29, no. 15, pp. 1642-1647.
 33. Sariali E., Lazennec J.Y., Khiami F., Gorin M., Catonne Y. Modification of pelvic orientation after total hip replacement in primary osteoarthritis. *Hip Int.*, 2009, vol. 19, no. 3, pp. 257-263.
 34. Weng W.J., Wang W.J., Wu M.D., Xu Z.H., Xu L.L., Qiu Y. Characteristics of sagittal spine-pelvis-leg alignment in patients with severe hip osteoarthritis. *Eur. Spine J.*, 2015, vol. 24, no. 6, pp. 1228-1236. DOI: 10.1007/

s00586-014-3700-5.

35. Jean L. Influence of age and sagittal balance of the spine on the value of the pelvic incidence. *Eur. Spine J.*, 2014, vol. 23, no. 7, pp. 1394-1399. DOI: 10.1007/s00586-014-3207-0.
36. Chaléat-Valayer E., Mac-Thiong J.M., Paquet J., Berthonnaud E., Siani F., Roussouly P. Sagittal spino-pelvic alignment in chronic low back pain. *Eur. Spine J.*, 2011, vol. 20, no. Suppl. 5, pp. 634-640. DOI: 10.1007/s00586-011-1931-2.
37. Vasilenko I.I., Klimov V.S., Evsiukov A.V., Loparev E.A., Khalepa R.V., Moiseyev G.I. Rzaev D.A. Izmenenie sagittalnogo balansa u patsientov pozhilogo i starcheskogo vozrasta s degenerativnym stenozom poiasnichnogo otdela pozvonochnika [Changing the sagittal balance in elderly and senile patients with degenerative stenosis of the lumbar spine]. *Voprosy Neurokhirurgii im. N.N. Burdenko*, 2015, no. 5, pp. 102-107. doi: 10.17116/neiro2015795102-107. (in Russian)
38. Khominets V.V., Kudiashev A.L., Shapovalov V.M., Miroevskii F.V. Sovremennye podkhody k diagnostike sochetannoi degenerativno-distroficheskoi patologii tazobedrennogo sustava i pozvonochnika [Modern approaches to diagnosing the combined degenerative pathology of the hip and spine]. *Travmatologiya i Ortopediya Rossii*, 2014, no. 4 (74), pp. 16-26. (in Russian)
39. Shapovalov V.M., Kudiashev A.L., Rezvantsev M.V., Khominets V.V. Vzaimosvyez parametrov sagittalnykh i frontalnykh pozvonочно-tazovykh vzaimootnoshenii u bolnykh s odno- i dvustoronnim koksartrozom [Correlation of the parameters of sagittal and frontal spinopelvic relations in patients with uni- and bilateral coxarthrosis]. *Rossiiskii Biomeditsinskii Zhurnal*, 2012, vol. 13, no. 2, pp. 433-445. (in Russian)
40. Laouissat F., Sebaaly A., Gehrchen M., Roussouly P. Classification of normal sagittal spine alignment: refounding the Roussouly classification. *Eur. Spine J.*, 2018, vol. 27, no. 8, pp. 2002-2011. DOI: 10.1007/s00586-017-5111-x.
41. Roussouly P., Gollogly S., Berthonnaud E., Dimnet J. Classification of the normal variation in the sagittal alignment of the human lumbar spine and pelvis in the standing position. *Spine*, 2005, vol. 30, no. 3, pp. 346-353.
42. Shnaider L.S., Pavlov V.V., Krutko A.V., Golenkov O.I. Sagittalnye pozvonочно-tazovye vzaimootnosheniia u patsientov s displaziei tazobedrennogo sustava CROWE IV st. po dannym sagittalnykh rentgenogramm [Sagittal spinopelvic relations in patients with IV Degree CROWE dysplasia of the hip by the data of sagittal X-rays]. *Sovremennye Problemy Nauki i Obrazovaniia*, 2016, no. 6. (in Russian) Available at: <https://science-education.ru/ru/article/view?id=25508> (accessed 10.04.2017).
43. Eyvazov K., Eyvazov B., Basar S., Nasto L.A., Kanatli U. Effects of total hip arthroplasty on spinal sagittal alignment and static balance: a prospective study on 28 patients. *Eur. Spine J.*, 2016, Vol. 25, No 11. P. 3615-3621. DOI: 10.1007/s00586-016-4696-9.
44. Piazzolla A., Solarino G., Bizzoca D., Montemurro V., Berjano P., Lamartina C., Martini C., Moretti B. Spinopelvic parameter changes and low back pain improvement due to femoral neck anteversion in patients with severe unilateral primary hip osteoarthritis undergoing total hip replacement. *Eur. Spine J.*, 2018, Vol. 27, No 1. P. 125-134. DOI: 10.1007/s00586-017-5033-7.
45. Schwab F., Lafage V., Patel A., Farcy J.P. Sagittal plane considerations and the pelvis in the adult patient. *Spine*, 2009, Vol. 34, No 17. P. 1828-1833. DOI: 10.1097/BRS.0b013e3181a13c08.
46. Morvan G., Mathieu P., Vuillemin V., Guerini H., Bossard P., Zeitoun F., Wybier M. Standardized way for imaging of the sagittal spinal balance. *Eur. Spine J.*, 2011, vol. 20, no. Suppl. 5, pp. 602-608. DOI: 10.1007/s00586-011-1927-y.
47. Vaz G., Roussouly P., Berthonnaud E., Dimnet J. Sagittal morphology and equilibrium of pelvis and spine. *Eur. Spine J.*, 2002, vol. 11, no. 1, pp. 80-87. DOI: 10.1007/s005860000224.
48. Nashner L.M., McCollum G. The organization of human postural movements: a formal basis and experimental synthesis. *Behav. Brain Sci.*, 1985, vol. 8, pp. 135-172. DOI: 10.1017/S0140525X00020008.
49. Bisson E.J., McEwen D., Lajoie Y., Bilodeau M. Effects of ankle and hip muscle fatigue on postural sway and attentional demands during unipedal stance. *Gait Posture*, 2011, vol. 33, no. 1, pp. 83-87. DOI: 10.1016/j.gaitpost.2010.10.001.
50. Jackson R.P., Hales C. Congruent spinopelvic alignment on standing lateral radiographs of adult volunteers. *Spine*, 2000, vol. 25, no. 21, pp. 2808-2815.
51. Jackson R.P., Peterson M.D., McManus A.C., Hales C. Compensatory spinopelvic balance over the hip axis and better reliability in measuring lordosis to the pelvic radius on standing lateral radiographs of adult volunteers and patients. *Spine*, 1998, vol. 23, no. 16, pp. 1750-1767.
52. Lazennec J.Y., Brusson A., Rousseau M.A. Hip-spine relations and sagittal balance clinical consequences. *Eur. Spine J.*, 2011, vol. 20, no. Suppl. 5, pp. 686-698. DOI: 10.1007/s00586-011-1937-9.
53. Kanziuba A.I., Klimovitskii V.G., Kanziuba M.A. Osobennosti totalnoi artroplastiki pri displasticheskom koksartroze [Characteristic features of total arthroplasty for dysplastic coxarthrosis]. *Travma*, 2015, vol. 16, no. 1, pp. 72-78. (in Russian)
54. Argenson J.N., Flecher X., Parratte S., Aubaniac J.M. Anatomy of the dysplastic hip and consequences for total hip arthroplasty. *Clin. Orthop. Relat. Res.*, 2007, vol. 465, pp. 40-45.

55. Hirose S., Otsuka H., Morishima T., Sato K. Long-term outcomes of shelf acetabuloplasty for developmental dysplasia of the hip in adults: a minimum 20-year follow-up study. *J. Orthop. Sci.*, 2011, vol. 16, no. 6, pp. 698-703. DOI: 10.1007/s00776-011-0159-7.

Received: 07.12.2018

Information about the authors:

1. Oksana G. Prudnikova, M.D., Ph.D.,
Russian Ilizarov Scientific Centre for Restorative Traumatology and Orthopaedics, Kurgan, Russian Federation,
Email: pog6070@gmail.com
2. Oleg K. Chegurov, M.D., Ph.D.,
Russian Ilizarov Scientific Centre for Restorative Traumatology and Orthopaedics, Kurgan, Russian Federation
3. Aleksandr S. Triapichnikov, M.D., Ph.D.,
Russian Ilizarov Scientific Centre for Restorative Traumatology and Orthopaedics, Kurgan, Russian Federation
4. Boris V. Kamshilov, M.D., Ph.D.,
Russian Ilizarov Scientific Centre for Restorative Traumatology and Orthopaedics, Kurgan, Russian Federation