

Применение метода Илизарова с фиксацией коленного сустава при инфицированных несращениях дистального отдела бедренной кости с потерей костной массы

Kumar Jha. Dipak¹, Kumar Mallick Sunny²

¹VIMS, Kolkata, India

²GNRC Medical, Barasat, India

The use of the knee spanning Ilizarov method as a treatment procedure in infected nonunion of the distal femur with bone loss

Kumar Jha. Dipak¹, Kumar Mallick Sunny²

¹VIMS, Kolkata, India

²GNRC Medical, Barasat, India

Введение. Инфицированное несращение дистального отдела бедренной кости является очень сложной проблемой с точки зрения лечения, ухудшает качество жизни и увеличивает экономическую нагрузку на общество. Хирургическое лечение является сложным, а единого мнения о том, какая методика приведет к наилучшему результату, нет. **Материалы и методы.** Изучены результаты у 10 пациентов с инфицированным несращением дистального отдела бедренной кости и потерей костной массы, которых лечили с января 2010 по декабрь 2015 года, применив радикальную хирургическую обработку и внешний фиксатор Илизарова. **Результаты.** Средний период наблюдения после снятия аппарата составил 18,6 месяца (от 14 до 30 месяцев). Ни один пациент не был потерян при контроле. Средняя продолжительность внешней фиксации составила 313,9 дня (от 275 до 362), что коррелировало с достигнутым окончательным удлинением. Согласно системе оценок по Пейли, восемь пациентов имели отличные клинические и рентгенологические результаты и пять – отличные и хорошие функциональные результаты. Сращение, опороспособность и купирование инфекции были достигнуты у всех пациентов. **Заключение.** Лечение переломов дистального отдела бедренной кости представляет собой сложную ортопедическую задачу, если сопровождается несращением, инфекцией, потерей костной массы, укорочением, рубцовыми изменениями мягких тканей, контрактурой, ограничением движений, остеопенией. В этих случаях метод Илизарова является окончательным вариантом лечения, поскольку он обеспечивает стабильность, позволяет осуществлять раннюю нагрузку, компрессию/дистракцию в месте перелома, помогает бороться с инфекцией и способствует сращению, а кортикотомия позволяет восстановить длину сегмента.

Ключевые слова: бедренная кость, дистальный отдел, несращение, инфекция, аппарат Илизарова, кортикотомия

Background Infected nonunion of the distal femur is a very difficult entity to treat; it grossly affects daily living and adds economic burden to the society. There is no consensus on which surgical technique of its management leads to the best outcome. **Materials and methods** We reviewed 10 patients with infected nonunion of the distal femur and bone loss who were treated by radical surgical debridement and application of the Ilizarov external fixator from January 2010 to December 2015. **Results** The mean follow-up after removal of the frame was 18.6 months (range, 14 to 30 months). No patient was lost to follow-up. The mean external fixator time was 313.9 days (range, 275 to 362 days) which correlated with the final lengthening achieved. According to Paley's grading system, eight patients had excellent clinical and radiological results and five excellent and good functional results. Bony union, ability to bear weight fully, and resolution of the infection were achieved in all the patients. **Conclusion** Distal femoral nonunion is a complicated orthopedic entity as it may be associated with nonunion, infection, bone loss, shortening, soft tissue scar, contracture, restriction of movement, disuse osteopenia. Ilizarov external fixation is a definitive treatment modality in these cases as it gives stability, allows early weight-bearing, compression/distraction at fracture site, helps to arrest infection and achieve union while corticotomy helps to regain length.

Keywords: femur, distal femur, nonunion, infection, Ilizarov apparatus, corticotomy

Open distal femoral high-energy fractures with bone loss and associated contamination, devitalisation of metaphyseal bone fragments from extensive surgical exposure [1] and the use of bulky internal fixation may result in an infected nonunion. A short distal fragment, poor bone quality and compromised soft tissues are also associated with this outcome. Union may be achieved with deformity and leg-length discrepancy leading to posttraumatic osteoarthritis and stiffness of the knee [2–5]. This may necessitate arthrodesis as a salvage procedure [6], and in some cases amputation may be required.

Although the Ilizarov external device has been described for use in the management of infected nonunion in general [7–9], to our knowledge there have been few reports [10] regarding the treatment of infected nonunion of the distal femur with bone loss. In 2006, A. Krishnan published his work on treatment of infected nonunion of the femur with the Ilizarov method and showed impressive results [11]. In this retrospective study we have analyzed the results of treatment of this condition using the Ilizarov external device in an attempt to salvage the limb and to maximize its function.

PATIENTS AND METHODS

We reviewed the records of 10 adult patients who were treated with the Ilizarov system for infected nonunion of the distal femur and bone loss between January 2010 and

December 2015. The inclusion criteria were the presence of such a problem with bone loss of 3 cm or more at a maximum distance of 9 cm from the knee [4].

There were eight men and two women at a mean age of 41.2 years (range, 22 to 75 years). Nonunion resulted from open high-energy complex fractures of the distal femur, type III B according to the classification of Gustilo and Anderson in seven, and closed fractures in three. Road-traffic accidents were the cause in 9 patients and gunshot injury in one. The left side was affected in seven patients. The mean interval from the injury to application of the Ilizarov fixator was 13.5 months (range, 9 to 23). The initial treatment of fractures consisted of open reduction and internal fixation (ORIF) in four patients, unilateral transarticular external fixation in six (Table I). A total of 43 operations had been performed before the definitive treatment, including internal and external fixation, intramedullary nailing, bone grafting, and wound debridement. The mean number of previous surgical procedures was 4.3 (range, 3 to 6).

The mean bone defect length was 6.3 cm (range, 4 to 9 cm). In three patients, infection was active but without drainage, and in the remaining seven there was active purulent drainage.

Staphylococcus aureus was the responsible organism in six patients, Pseudomonas aeruginosa in

three and Escherichia coli in one patient (Table I).

At the time of definitive treatment all patients had very severe limitation of movement of the knee; the joint was completely stiff in five. In three cases, it was impossible to be certain whether the movement clinically detected was occurring at the knee or at the adjacent nonunion or in combination. Seven patients had moderate or severe posttraumatic osteoarthritis of the knee with radiologically identified irregularity of the articular surface and a decreased joint space. Moderate to severe disuse osteopenia of the distal femoral fragment and extensive scarring were present in every patient and none was able to bear weight.

Pre-operatively, the location of sinus tracts, previous scars, and the neurovascular condition were carefully evaluated. Imaging included plain radiography and sinography which were used to identify the severity of the infection and the extent of infected and necrotic bone. Intra-operatively, sinography with methylene blue was used in seven patients with active infection to delineate the extent of the infection and bone destruction. In the metaphyseal area, the full extent of the infection could be determined only by inspection at operation [1].

Table I

Details of the patients at the time of definitive treatment

Case	Age (years)	Type of fracture [10]	Time to application of fixator (months)	Number of previous operations	Operations before application of the Ilizarov device*	Infecting organism	Bone defect (cm)
1	27	III B	15	5	TEF + WD > WD > IM nailing > BG > WD	Staph. aureus	6
2	28	III B	11	5	TEF + WD > IM nailing > ORIF with plate > WD > WD	Staph. aureus	7
3	47	III B	9	3	IM nailing > BG > WD	Pseudomonas	7
4	40	III B	14	4	TEF + WD > IM Nailing > WD > IR	E. coli	6
5	65	Close	11	4	ORIF with plate > WD > BG > WD	Staph. aureus	5
6	30	Close	9	3	ORIF with plate > WD > WD + BG	Staph. aureus	4
7	75	Close	13	4	ORIF with plate > WD > WD > BG	Pseudomonas	5
8	22	III B	18	6	TEF + WD > WD > IM nailing > ORIF with plate > IR > ST	Staph. aureus	8
9	28	III B	23	5	TEF + WD > WD > IM nailing > ORIF with plate > IR + WD	Pseudomonas	9
10	50	III B	12	4	TEF + WD > ORIF with plate > BG > WD	Staph. aureus	6

* ORIF – open reduction and internal fixation; IM – intramedullary; EF – external fixator; BG – bone grafting; WD – wound debridement; TEF – transarticular external fixator; ST – skeletal traction; IR – implant removal

Table II

Details of treatment in 10 patients

Case	Technique of osteosynthesis*	Docking site†	Additional procedure‡	Lengthening (cm)	EFT§ (days)
1	BFCC-DO	AD	NO	3	296
2	BFCC-DO	AS	NO	4	290
3	BFCC-DO	AS	Iliac grafts	4	295
4	BFCC-DO	AD	NO	3	332
5	BFCC-DO	AD	FM	2	330
6	BFCC-DO delayed corticotomy (after 20 days)	AD	Iliac grafts, RD-1	2	284
7	BFCC-DO	AD	NO	3	275
8	BFCC-DO delayed corticotomy (after 1 month)	AS	Iliac grafts, RD-1	5	331
9	BFCC-DO delayed corticotomy (after 3 months)	AS	Iliac grafts	7	344
10	BFCC-DO	AD	NO	4	362

* BFCC-DO – bifocal combined compression-distraction osteosynthesis; † AD – acute docking; AS – acute shortening; ‡ FM – frame modification; RD – repeated debridement; § EFT – external fixation time

OPERATIVE TECHNIQUE

The infected area was exposed in all 10 patients by an extensive lateral approach through the less damaged soft tissues in order to remove all loose implants and all infected and non-viable tissues. Samples thus obtained were sent for gram staining, culture and sensitivity (aerobic/anaerobic).

The bone ends were freshened, the medullary canal reconstituted and open reduction of the main fragments was performed to achieve the best possible contact between them. Impaction of the shaft of the femur into the condylar area was attempted to increase internal stability at the site of the defect in each case [9, 13].

Acute docking was possible in 6 patients, while acute shortening of the site of the defect in order to improve soft tissue cover and circulation was performed in 4 with bone loss of more than 6 cm.

After the acute shortening or acute docking, the Ilizarov external device was applied. Primary wound closure was performed in five cases followed by adequate drainage. Technique of bifocal osteosynthesis [7, 9] was used (Table II). In seven patients, bifocal combined compression-distraction osteosynthesis was undertaken from the beginning. In three of these with extensive soft-

tissue damage and aggressive purulent infection, a second-stage corticotomy was performed at twenty days, one month and three months post-operatively, and conjugative compression at nonunion site at distal femur and distraction in proximal tibial corticotomy site done. Proximal tibial corticotomy was performed in each to restore limb length by filling in the bone defect.

A standard bifocal circular frame for infected nonunion with distal femur bone loss consisted of four or five rings and one proximal femoral arch (Fig. 1). In all patients with short distal fragments and considerable instability in the interfragmentary area, three circular rings fixation on the tibia without hinges was used to enhance stability, to protect the distal femoral fixation and to lengthen the limb by proximal tibial corticotomy [3, 14]. Additional surgical procedures after the application of the Ilizarov frame were required in several patients to eradicate the infection and encourage union. These included repeated debridement in two, modification of the external fixator in one and freshening of the bone ends and iliac bone grafting in four with sclerotic avascular bone ends and no progress to union at the docking site.

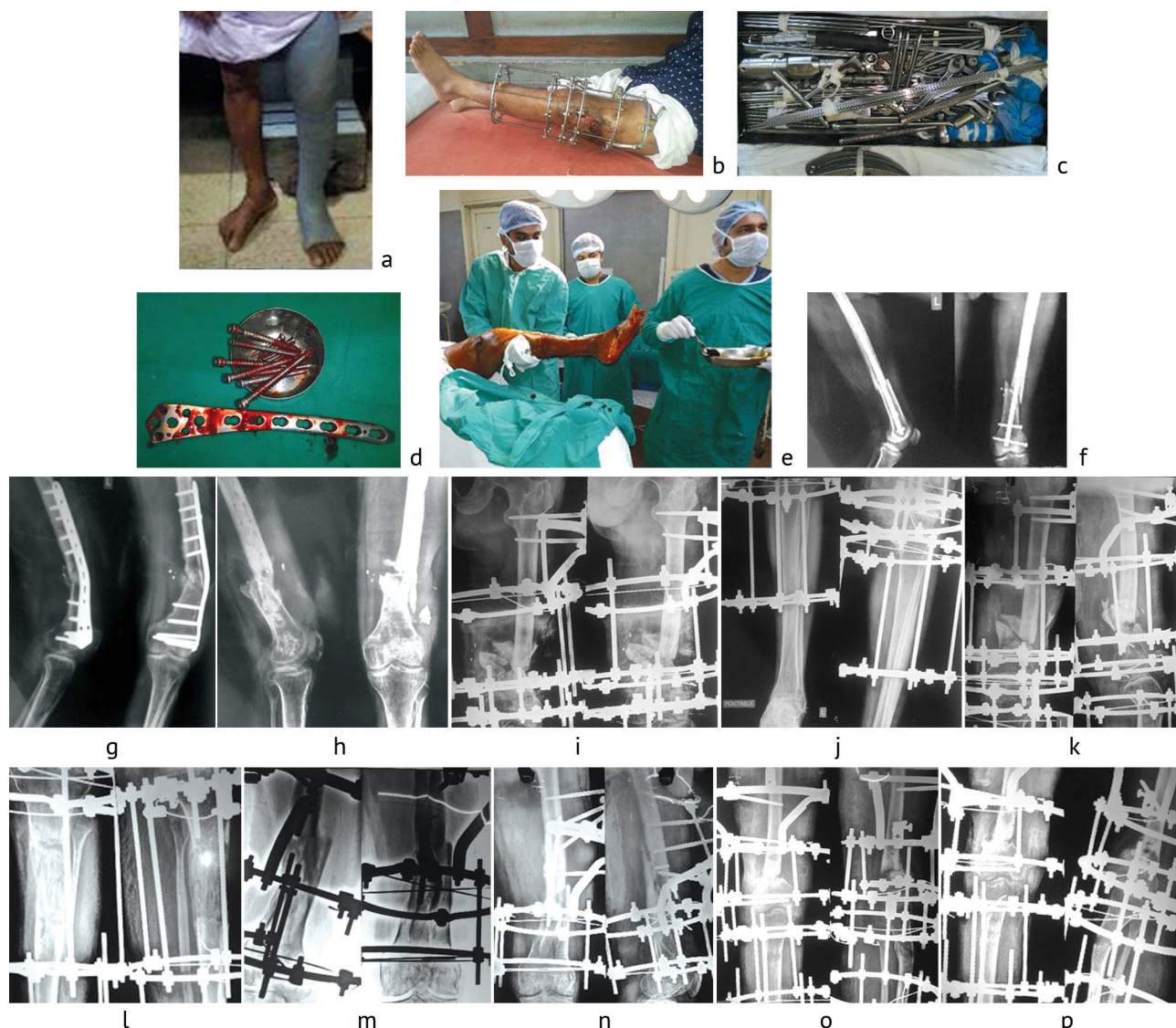


Fig. 1: *a* patient with long leg cast after removal of Ilizarov rings; *b* patient with Ilizarov frame; *c* instruments set; *d* removed infected implants; *e* surgical team; *f* x-ray of nonunion with intramedullary nail; *g* plate failure with infection; *h* preoperative x-ray; *i-j* immediate postoperative x-ray; *k* postoperative follow up x-ray; *l* corticotomy and lengthening; *m-p* postoperative x-rays of different patients

POST-OPERATIVE CARE

All patients received a course of antibiotics for four to six days post-operatively. A course of strong analgesics was required in two postoperative days. The erythrocyte sedimentation rate and the level of C-reactive protein were monitored on a regular basis. The latency period before commencing bone transportation was three to five days and the rate of distraction at the site of the corticotomy was 1mm per day. When docking was achieved, interfragmentary compression continued at the rate of 0.5 mm per day for five to seven days and once consolidation commenced at a rate 0.25 to 0.5 mm per week. Patients were encouraged to bear normal weight with crutches as soon as they could tolerate it after surgery. Quadriceps isometric exercises were started immediately after the operation to maintain or train the muscle strength.

All patients returned for routine clinical and radiological follow-up every month after surgery until the Ilizarov device was removed, and every three months in the following year. After the removal of the external fixator, the patients were restricted to partial weight-bearing for two weeks with plaster of Paris long-leg cast. Full weight-bearing was allowed with bi-valved detachable synthetic or thermoplastic long-leg guard for 6 months.

Post-operative radiographs were evaluated for residual malalignment and evidence of union. Radiological union was defined as the absence of a radiolucent line at the site of the nonunion and filling of the bone defect with new bone [15] at a minimum of three cortices on standard anteroposterior and lateral radiographs [16]. The results were assessed using the functional and radiological scoring system described by Paley and Maar [17].

RESULTS

The mean follow-up after removal of the frame was 18.6 months (range, 14 to 30). No patient was lost to follow-up.

The mean external fixator time was 313.9 days (range, 275 to 362) which correlated with the final lengthening achieved (Table II).

The number of previous operations was also of some predictive value for external fixation duration. When the patient had been subjected from one to three operations before initiation of definitive treatment, the external fixator time was 289.5 days (284 to 295) but for four and five operations it was 320 days (275 to 362), an increase of 10.34 %.

Bone

Clinical and radiological union and elimination of infection were achieved in all 10 patients. According to Paley and Maar's grading system [17], eight patients had excellent, one good, and one a fair result. Residual mean leg-length discrepancy was 2.6 cm.

Function

At the time of the latest follow-up, all 10 patients were able to bear weight fully on the affected leg without any walking aid or brace. They had only mild pain when undertaking activities of daily living. The functional

result was excellent in three patients, good in two, fair in three and poor in two cases. Although seven patients had obvious limping, they were still able to perform the normal activities of daily living. After removal of braces patients had mean knee flexion of 22 degrees (10–40 degree).

Complications

There were no neurovascular intra-operative complications and no patient developed a neurovascular deficit or a compartment syndrome. The most common complication was pin-track infection, especially in the distal segment as a result of severe osteopenia and poor soft-tissue cover. In nine patients with grade-3 infection according to Paley's classification [18], the wires had to be removed and replaced under local anesthesia. Prevention of pin-track infection was attempted by insertion of the wires through healthy skin, re-tensioning of loose wires and the use of counter-opposing olive wires, meticulous cleaning and, occasionally, administration of oral antibiotics after tests for culture and sensitivity. Continuous mild pain requiring analgesia was felt in all patients during the distraction phase. One non-displaced re-fracture at the docking site, which occurred two months after premature removal of the external fixator, was treated by re-application of the Ilizarov frame for three months.

DISCUSSION

Infected nonunion of the distal femur with associated bone loss represents one of the most difficult problems in orthopedic practice [19]. Apart from high-energy trauma, predisposing factors include the proximity to the knee and the distracting pull of the gastrocnemius, previous surgical interventions with extensive dissection and inadequate initial fixation [5]. The presence of infection in this area makes treatment even harder. Specific problems related to this condition include lost bone with poor soft-tissue cover and scarring, deformity, shortening, post-traumatic osteoarthritis and stiffness in the knee [3, 5].

In our study, the cause of all the fractures was high-energy trauma with extensive disruption of the soft-tissue envelope and blood supply in seven. Despite the fact that our series was relatively small, it is noteworthy that the external fixator time reflected the extent of bone restoration

required, delay in commencement of definitive treatment, number of previous interventions and nature of the initial stabilization of the fracture.

Unilateral temporary transarticular external fixators can be applied easily and rapidly and are popular for the initial management of high-energy fractures of the femur [20]. They protect the remaining blood supply, avoid shortening and gross malalignment, while allowing adequate access for wound care. However, because of eccentric loading there is an increased risk of angular and shear displacement at the site of the fracture [21].

A. Ebraheim in a systematic review showed that the most common definitive treatment was fixed angle plating combined with cancellous autografting, resulted in a successful union rate of 97.4% and average time to heal of 7.8 months [22]. But all our patients had undergone several

previous failed surgeries, so the Ilizarov method worked better than any other options in these patients.

The use of the Ilizarov external device for definitive fixation of fractures of the distal femur is the safest and most effective method since it provides adequate fixation and stabilization at the site of the fracture,

thus increasing osseous healing and infection arrest [14, 23, 24]. In the presence of infection, aggressive debridement has been shown to be the cornerstone of successful treatment [25, 26]. In our series, the use of the Ilizarov method offered limb salvage with no need for amputation.

ЛИТЕРАТУРА

1. Krettek C., Schandelmaier P., Tscherne H. Distal femoral fractures. Transarticular reconstruction, percutaneous plate osteosynthesis and retrograde nailing // *Unfallchirurg*. 1996. Vol. 99, No 1. P. 2-10.
2. Wu C.C., Shih C.H. Distal femoral nonunion treated with interlocking nailing // *J. Trauma*. 1991. Vol. 31, No 12. P. 1659-1662.
3. Ali F., Saleh M. Treatment of distal femoral nonunions by external fixation with simultaneous length and alignment correction // *Injury*. 2002. Vol. 33, No 2. P. 127-134.
4. Bellabarba C., Ricci W.M., Bolhofner B.R. Indirect reduction and plating of distal femoral nonunions // *J. Orthop. Trauma*. 2002. Vol. 16, No 5. P. 287-296.
5. Johnson K.D., Hicken G. Distal femoral fractures // *Orthop. Clin. North Am.* 1987. Vol. 18, No 1. P. 115-132.
6. Webb L.X. Bone defect nonunion of the lower extremity // *Tech. Orthop.* 2001. Vol. 16, No 4. P. 387-397.
7. Ilizarov G.A. *Transosseous osteosynthesis. Theoretical and clinical aspects of the regeneration and growth of tissue* / Ed. Green S.A. Berlin, Heidelberg: Springer-Verlag, 1992. 802 p. DOI: 10.1007/978-3-642-84388-4.
8. Green S.A. Skeletal defects. A comparison of bone grafting and bone transport for segmental skeletal defects // *Clin. Orthop. Relat. Res.* 1994. No 301. P. 111-117.
9. Ilizarov treatment of tibial nonunions with bone loss / D. Paley, M.A. Catagni, F. Argnani, A. Villa, G.B. Benedetti, R. Cattaneo // *Clin. Orthop. Relat. Res.* 1989. No 241. P. 146-165.
10. Lower limb salvage surgery using Ilizarov circular external frame for a landmine injury about the knee / B. Demiralp, C. Yıldırım, Y. Yurttaş, E.I. Çiçek, M. Başbozkurt // *Eklemler Hastalıkları Cerrahisi*. 2013. Vol. 24, No 1. P. 41-45. DOI: 10.5606/ehc.2013.10.
11. Krishnan A., Pamecha C., Patwa J.J. Modified Ilizarov technique for infected nonunion of the femur: the principle of distraction-compression osteogenesis // *J. Orthop. Surg. (Hong Kong)*. 2006. Vol. 14, No 3. P. 265-272.
12. Gustilo R.B., Anderson J.T. Prevention of infection in the treatment of one thousand and twenty-five open fractures of long bones: retrospective and prospective analyses // *J. Bone Joint Surg. Am.* 1976. Vol. 58, No 4. P. 453-458.
13. Tibial bone defects treated by internal bone transport using the Ilizarov method / H.R. Song, S.H. Cho, K.H. Koo, S.T. Jeong, Y.J. Park, J.H. Ko // *Int. Orthop.* 1998. Vol. 22, No 5. P. 293-297.
14. Ilizarov external fixation for severely comminuted supracondylar and intercondylar fractures of the distal femur / M. Arazi, R. Memik, T.C. Ogün, M. Yel // *J. Bone Joint Surg. Br.* 2001. Vol. 83, No 5. P. 663-667.
15. Wang J.W., Weng L.H. Treatment of distal femoral nonunion with internal fixation, cortical allograft struts, and autogenous bone-grafting // *J. Bone Joint Surg. Am.* 2003. Vol. 85-A, No 3. P. 436-440.
16. Femoral exchange nailing for aseptic non-union: not the end to all problems / P.A. Banaszkiewicz, A. Sabboubeh, I. McLeod, N. Maffulli // *Injury*. 2003. Vol. 34, No 5. P. 349-356.
17. Paley D., Maar D.C. Ilizarov bone transport treatment for tibial defects // *J. Orthop. Trauma*. 2000. Vol. 14, No 2. P. 76-85.
18. Paley D. Problems, obstacles, and complications of limb lengthening by the Ilizarov technique // *Clin. Orthop. Relat. Res.* 1990. No 250. P. 81-104.
19. Bolhofner B.R., Carmen B., Clifford P. The results of open reduction and internal fixation of distal femur fractures using a biologic (indirect) reduction technique // *J. Orthop. Trauma*. 1996. Vol. 10, No 6. P. 372-377.
20. Treatment of distal femur and proximal tibia fractures with external fixation followed by planned conversion to internal fixation / A.A. Parekh, W.R. Smith, S. Silva, J.F. Agudelo, A.E. Williams, D. Hak, S.J. Morgan // *J. Trauma*. 2008. Vol. 64, No 3. P. 736-739. DOI: 10.1097/TA.0b013e31804d492b.
21. Aronson J. Limb-lengthening, skeletal reconstruction, and bone transport with the Ilizarov method // *J. Bone Joint Surg. Am.* 1997. Vol. 79, No 8. P. 1243-1258.
22. Nonunion of distal femoral fractures: a systematic review / N.A. Ebraheim, A. Martin, K.R. Sochacki, J. Liu // *Orthop. Surg.* 2013. Vol. 5, No 1. P. 46-50. DOI: 10.1111/os.12017.
23. Hutson J.J. Jr., Zych G.A. Treatment of comminuted intraarticular distal femur fractures with limited internal and external tensioned wire fixation // *J. Orthop. Trauma*. 2000. Vol. 14, No 6. P. 405-413.
24. Ilizarov ring fixation and fibular strut grafting for C3 distal femoral fractures / L.J. Ramesh, S.A. Rajkumar, R. Rajendra, H.P. Rajagopal, M.S. Phaneesha, S. Gaurav // *J. Orthop. Surg. (Hong Kong)*. 2004. Vol. 12, No 1. P. 91-95.
25. The Ilizarov method in nonunion, malunion and infection of fractures / D.R. Marsh, S. Shah, J. Elliot, N. Kurdy // *J. Bone Joint Surg. Br.* 1997. Vol. 79, No 2. P. 273-279.
26. The use of the Ilizarov method as a salvage procedure in infected nonunion of the distal femur with bone loss / A. Saridis, E. Panagiotopoulos, M. Tyllianakis, C. Matzaroglou, N. Vondoros, E. Lambiris // *J. Bone Joint Surg. Br.* 2006. Vol. 88, No 2. P. 232-237.

REFERENCES

1. Krettek C., Schandelmaier P., Tscherne H. Distal femoral fractures. Transarticular reconstruction, percutaneous plate osteosynthesis and retrograde nailing. *Unfallchirurg*, 1996, vol. 99, no. 1, pp. 2-10.
2. Wu C.C., Shih C.H. Distal femoral nonunion treated with interlocking nailing. *J. Trauma*, 1991, vol. 31, no. 12, p. 1659-1662.
3. Ali F., Saleh M. Treatment of distal femoral nonunions by external fixation with simultaneous length and alignment correction. *Injury*, 2002, vol. 33, no. 2, pp. 127-134.
4. Bellabarba C., Ricci W.M., Bolhofner B.R. Indirect reduction and plating of distal femoral nonunions. *J. Orthop. Trauma*, 2002, vol. 16, no. 5, pp. 287-296.
5. Johnson K.D., Hicken G. Distal femoral fractures. *Orthop. Clin. North Am.*, 1987, vol. 18, no. 1, pp. 115-132.
6. Webb L.X. Bone defect nonunion of the lower extremity. *Tech. Orthop.*, 2001, vol. 16, no. 4, pp. 387-397.
7. Ilizarov G.A. *Transosseous osteosynthesis. Theoretical and clinical aspects of the regeneration and growth of tissue*. Green S.A., ed. Berlin, Heidelberg, Springer-Verlag, 1992, 802 p. DOI: 10.1007/978-3-642-84388-4.
8. Green S.A. Skeletal defects. A comparison of bone grafting and bone transport for segmental skeletal defects. *Clin. Orthop. Relat. Res.*, 1994, no. 301, pp. 111-117.
9. Paley D., Catagni M.A., Argnani F., Villa A., Benedetti G.B., Cattaneo R. Ilizarov treatment of tibial nonunions with bone loss. *Clin. Orthop. Relat. Res.*, 1989, no. 241, pp. 146-165.
10. Demiralp B., Yıldırım C., Yurttaş Y., Çiçek E.I., Başbozkurt M. Lower limb salvage surgery using Ilizarov circular external frame for a landmine injury about the knee. *Eklemler Hastalıkları Cerrahisi*, 2013, vol. 24, no. 1, pp. 41-45. DOI: 10.5606/ehc.2013.10.
11. Krishnan A., Pamecha C., Patwa J.J. Modified Ilizarov technique for infected nonunion of the femur: the principle of distraction-compression osteogenesis. *J. Orthop. Surg. (Hong Kong)*, 2006, vol. 14, no. 3, pp. 265-272.
12. Gustilo R.B., Anderson J.T. Prevention of infection in the treatment of one thousand and twenty-five open fractures of long bones: retrospective and

- prospective analyses. *J. Bone Joint Surg. Am.*, 1976, vol. 58, no. 4, pp. 453-458.
13. Song H.R., Cho S.H., Koo K.H., Jeong S.T., Park Y.J., Ko J.H. Tibial bone defects treated by internal bone transport using the Ilizarov method. *Int. Orthop.*, 1998, vol. 22, no. 5, pp. 293-297.
 14. Arazzi M., Memik R., Ogun T.C., Yel M. Ilizarov external fixation for severely comminuted supracondylar and intercondylar fractures of the distal femur. *J. Bone Joint Surg. Br.*, 2001, vol. 83, no. 5, pp. 663-667.
 15. Wang J.W., Weng L.H. Treatment of distal femoral nonunion with internal fixation, cortical allograft struts, and autogenous bone-grafting. *J. Bone Joint Surg. Am.*, 2003, vol. 85-A, no. 3, pp. 436-440.
 16. Banaszkiewicz P.A., Sabboubeh A., McLeod I., Maffulli N. Femoral exchange nailing for aseptic non-union: not the end to all problems. *Injury*, 2003, vol. 34, no. 5, pp. 349-356.
 17. Paley D., Maar D.C. Ilizarov bone transport treatment for tibial defects. *J. Orthop. Trauma*, 2000, vol. 14, no. 2, pp. 76-85.
 18. Paley D. Problems, obstacles, and complications of limb lengthening by the Ilizarov technique. *Clin. Orthop. Relat. Res.*, 1990, no. 250, pp. 81-104.
 19. Bolhofner B.R., Carmen B., Clifford P. The results of open reduction and internal fixation of distal femur fractures using a biologic (indirect) reduction technique. *J. Orthop. Trauma*, 1996, vol. 10, no. 6, pp. 372-377.
 20. Parekh A.A., Smith W.R., Silva S., Agudelo J.F., Williams A.E., Hak D., Morgan S.J. Treatment of distal femur and proximal tibia fractures with external fixation followed by planned conversion to internal fixation. *J. Trauma*, 2008, vol. 64, no. 3, pp. 736-739. DOI: 10.1097/TA.0b013e31804d492b.
 21. Aronson J. Limb-lengthening, skeletal reconstruction, and bone transport with the Ilizarov method. *J. Bone Joint Surg. Am.*, 1997, vol. 79, no. 8, pp. 1243-1258.
 22. Ebraheim N.A., Martin A., Sochacki K.R., Liu J. Nonunion of distal femoral fractures: a systematic review. *Orthop. Surg.*, 2013, vol. 5, no. 1, pp. 46-50. DOI: 10.1111/os.12017.
 23. Hutson J.J. Jr., Zych G.A. Treatment of comminuted intraarticular distal femur fractures with limited internal and external tensioned wire fixation. *J. Orthop. Trauma*, 2000, vol. 14, no. 6, pp. 405-413.
 24. Ramesh L.J., Rajkumar S.A., Rajendra R., Rajagopal H.P., Phaneesha M.S., Gaurav S. Ilizarov ring fixation and fibular strut grafting for C3 distal femoral fractures. *J. Orthop. Surg. (Hong Kong)*, 2004, vol. 12, no. 1, pp. 91-95.
 25. Marsh D.R., Shah S., Elliot J., Kurdy N. The Ilizarov method in nonunion, malunion and infection of fractures. *J. Bone Joint Surg. Br.*, 1997, vol. 79, no. 2, pp. 273-279.
 26. Saridis A., Panagiotopoulos E., Tyllianakis M., Matzaroglou C., Vondoros N., Lambiris E. The use of the Ilizarov method as a salvage procedure in infected nonunion of the distal femur with bone loss. *J. Bone Joint Surg. Br.*, 2006, vol. 88, no. 2, pp. 232-237.

Рукопись поступила 13.02.2019

Сведения об авторах / Information about the authors:

1. Kumar Jha Dipak, Dr., D-Ortho, M.S. Ortho, Professor & HOD in department of Orthopaedics, VIMS, Kolkata, India
2. Kumar Mallick Sunny, Dr., D-Ortho, DNB-Ortho, Consultant orthopedic surgeon
GNRC Medical, Barasat, India
Email: sunny.rgkmc@gmail.com