

***The use of LLIF technology in adult patients with degenerative scoliosis: retrospective cohort analysis and literature review*****V.S. Klimov<sup>1</sup>, I.I. Vasilenko<sup>1</sup>, A.V. Evsyukov<sup>1</sup>, R.V. Khalepa<sup>1</sup>, E.V. Amelina<sup>2</sup>, S.O. Ryabykh<sup>3</sup>, D.A. Rzaev<sup>1</sup>**<sup>1</sup>Federal Neurosurgical Center, Novosibirsk, Russian Federation<sup>2</sup>Novosibirsk State University, Novosibirsk, Russian Federation<sup>3</sup>Russian Ilizarov Scientific Center for Restorative Traumatology and Orthopaedics, Kurgan, Russian Federation

**Introduction** Incidence of adult degenerative scoliosis (ADS) among individuals over 50 years old reaches 68%. Surgical interventions aimed at correcting the spinal deformity in patients of the older age group are accompanied by a high risk of complications. The use of LLIF is associated with lower complications as compared with open anterior or posterior fusion.

**Materials and methods** Seventy-one patients with ADS (13 men, 58 women) were operated at the Federal Neurosurgical Center. Their average age was 60.4/60 (average/median) [55;64.5] (1: 3 quartile) years. The follow-up was from 12 to 18 months. X-ray study, SCT, MRI of the lumbar spine were used. Questionnaire surveys were conducted using the visual analog pain scale (VAS), Oswestry Disability Index (ODI) and the Short Form-36 (SF-36). Deformity correction was estimated in the frontal plane with Cobb's method. Scoliosis was classified according to SRS-Schwab classification. Parameters of sagittal balance were estimated: PI (Pelvic incidence), SS (Sacral slope), PT (Pelvic tilt), LL (Lumbar lordosis). SVA, PT and PI-LL (PI minus LL) were defined adjusted for the age.

**Results** Back pain according to VAS relieved from 6.1/6 [4;8] to 2.2/2 [2;3] points ( $p < 0.001$ ) and was statistically significant at 12 months after the surgery. Leg pain according to VAS decreased from 5.4/5 [4;8] to 2.1/2 [1;3] points ( $p < 0.001$ ) and was statistically significant at 12 months after the surgery. Functional adaptation according to ODI improved from 51.2/52.2 [38.6;64.1] to 31.8/33.3 [26.1;35.9] ( $p < 0.001$ ). According to SF36, PH before the surgery was 25.7/24.3 [21.8;28.9] on average and at 12 months after the surgery – 38.7/38.7 [35.4;41.2] ( $p < 0.001$ ). SF-36 MH before surgery was 27.1/26.3 [21.8;31.4] on average and 12 months later – 41.3/40.6 [36.5;43.7] ( $p < 0.001$ ). PT before the surgery was 23.3/22° [17.5;28], 12 months later it was 17.9/17° [15;20] ( $p < 0.001$ ). PI-LL was 11.5/10° [4; 17.5], 12 months later – 8.4/8° [5.5;11.5] ( $p = 0.11$ ). Transient paresis of femur flexors on the ipsilateral side was observed in five (7 %) cases; transient hyposthesia on the anterior thigh surface occurred in eight (11.2 %) cases. There were two cases of medial malposition (0.4 %) of pedicle screws (474 screws), pseudoarthrosis at two levels (1.2 %) (Grade 4 Bridwell) out of 166 levels performed, and seven (4.2 %) cases of damage to cortical endplates.

**Conclusion** Restoration of local sagittal balance in ADS patients by short-segment fixation using LLIF technology leads to a statistically significant improvement in the quality of life and increases functional adaptation. Few early and late postoperative complications, less intraoperative blood loss and shorter hospital stay make LLIF in combination with MIS transpedicular fixation a method of choice in determining the surgical tactics for ADS in elderly and old age patients.

**Keywords:** lateral lumbar interbody fusion, sagittal balance, adult degenerative scoliosis, quality of life

## RELEVANCE

Incidence of adult degenerative scoliosis (ADS) among individuals over 50 years old reaches 68 % and grows as the age advances. The main morphological ADS substrate is intervertebral disc degeneration in the lumbar spine [3]. It induces spinal column deformity and imbalance. These two components are the leading ones in the ADS vertebral syndrome. Thus, the most common ADS variant with a positive sagittal imbalance is a predictor of pain and quality of life worsening both in natural history of the disease and after spondylodesis performed without spine profile reconstruction [4, 5, 6, 7], what determines the main goal of surgical management in ADS [8].

Operative interventions aimed at correcting

the spinal deformity in patients of the old age are accompanied by a high risk of complications [9]. They develop both due to highly traumatic surgical intervention and to concomitant somatic pathologies. In this regard, the use of minimally invasive technologies to correct the sagittal balance is preferred in this group of patients.

Lumbar lateral interbody fusion (LLIF) was developed as a technique to correct the deformity in the frontal and sagittal planes, as well as to perform indirect decompression of spinal cord roots [10, 11, 12] The use of LLIF is associated with fewer complications when compared with an open spinal fusion from any approach [13, 14].

Климов В.С., Василенко И.И., Евсюков А.В., Халепа Р.В., Амельна Е.В., Рыбых С.О., Рзаев Д.А. The use of LLIF technology in adult patients with degenerative scoliosis: retrospective cohort analysis and literature review. Genij Ortopedii. 2018. T. 24. No 3. pp. 393-403. DOI 10.18019/1028-4427-2018-24-3-393-403. (In Russian)

Despite this circumstance, surgical correction of ADS using LLIF technology has been not so widely used. Thus, a limited number of information sources are available.

To a certain extent, this fact has objective explanations:

- First, ideological, educational or technological problems in assessing the sagittal balance;
- Second, prevalence of neglected deformity with polysegmentary stenosis and instability;
- Third, the cost of applying the technology for a fairly common nosological group.

These circumstances are particularly relevant in the Russian Federation. However, there is no consensus on the evaluation of clinical and radiological outcomes of ADS treatment in the available literature. This circumstance based on the accumulated experience of using the LLIF technique for ADS motivated the authors to conduct this study.

The aim of the study was to analyze the results of using the LLIF technology for treatment of patients with sagittal imbalance due to degenerative scoliosis of the lumbar spine.

## MATERIAL AND METHODS

The work is based on the principle of retrospective monocenter continuous study.

The material of the study was treatment outcomes of 104 patients with degenerative scoliosis of the lumbar spine. Seventy one patients were monitored for follow-up studies (13 men and 58 women, 18 % and 82 %, respectively). There were 71 operations. Recruitment period was between 2014 and 2016. The study was conducted at the spinal unit of the Federal Center for Neurosurgery (Novosibirsk).

*Criteria for inclusion* into the study:

- Degenerative scoliosis of the lumbar spine with an angle  $\geq 10^\circ$  (Cobb) in the frontal plane;
- Clinical manifestations such as pain syndrome, radiculopathy and / or their combination;
- Lack of a positive effect of complex conservative therapy administered for two months prior to inclusion.

Patients with idiopathic scoliosis, as well as patients with a previous operation on the spine, were *excluded*.

The protocol of pre- and postoperative study included medical history, general clinical, orthopedic and neurological examination with an assessment of the leading syndrome, neurophysiological monitoring and interviewing. Evaluation of the results was carried out 12 months after surgery.

Imaging techniques were X-rays of the spine with the capture of femoral heads in two projections, spiral computed tomography (SCT) and magnetic resonance imaging (MRI) of the lumbar spine. To assess the severity of pain in the back and lower extremities, the Visual Analogue Scale (VAS) was used. The evaluation of functional adaptation was carried out using the Oswestry Disability Index (ODI, 1976)

[15]. The quality of life was assessed with the Short Form-36 (SF-36), which focused on the physical health component (PH) and mental health (MH) [16].

During the surgery, patients underwent neurophysiological monitoring of spontaneous electromyographic activity in the m. rectus femoris vastus lateralis (L2–L4), m. tibialis anterior and m. gastrocnemius (L5–S1) from the side of the surgical access and direct electrical stimulation of spinal roots and lumbar plexus branches innervating the leg muscles within the area of surgical intervention. It enabled both visualization of anatomically important neural structures in the field of surgical intervention and prevention of their damage.

Measurements of the sagittal balance parameters were carried out using the Sagittal Balance Academy software ([www.sagittal-balance.com](http://www.sagittal-balance.com)).

*Criteria for evaluation*

The deformity in the frontal plane was estimated by X-ray findings according to Cobb [17].

Deformity of the spine was classified according to SRS-Schwab using classification modifiers to assess the parameters of the sagittal and frontal balance [18]: the type of curve in the frontal plane (T, TL, L, N); sagittal modifiers PI (Pelvic incidence), SS (Sacral slope), PT (Pelvic tilt), LL (lumbar lordosis). The target value of integrated SVA (Sagittal vertical axis) and PI-LL (PI minus LL) was determined adjusted to age [18]. To determine the target LL, we used the formula:  $LL = PI \times 0.5 + 28^\circ$  [19].

Criteria proposed by A.A. White and M.M. Panjabi in 1978 were used for diagnosing instability [20].

Duration time of the surgical intervention, blood loss, and inpatient stay were recorded.

In the long-term period after the operation,

bone fusion quality was estimated on the basis of the K.H. Bridwell (1997) [21] and malposition of transpedicular screws according to the classification of G. Rao (2003) [22].

Hypertrophy of facet joints, marginal bony outgrowth, ossification of the posterior and anterior longitudinal ligaments was assessed with SCT, [23].

**Surgical protocol** All patients underwent correction of degenerative scoliotic deformity and restoration of impaired spino-pelvic relationship with the LLIF technique followed by transcutaneous transpedicular

fixation of spinal units using minimally invasive surgery (MIS).

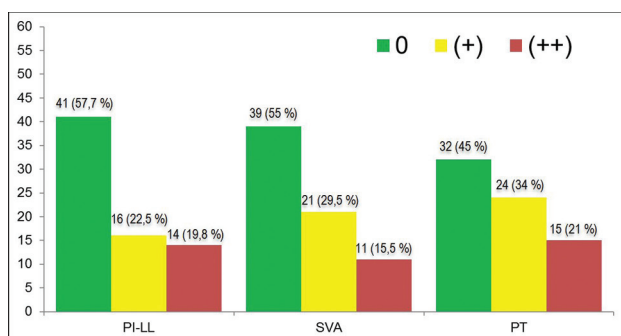
**Statistical analysis of the data obtained** Numerical data are presented as average/ median [lower; upper quartile]. Two-sided Wilcoxon test was used to compare the dependent samples. Correction for multiple comparisons was carried out with the Holm method. The level of statistical significance in the study was assumed to be 0.05. Calculations were carried out using software R version 3.4.3 [24].

Level of evidence: III.

## RESULTS

Patients' age was between 37 and 82 years (60.4/60 [55;64.5] years). In all patients, the dominant clinical manifestation was vertebrogenic pain syndrome. Sixty five (91 %) patients had a combination of vertebrogenic pain and radiculopathy. Thus, 89.6 % of cases (58 patients) had L4 radiculopathy, 10.4 % of cases (7 patients) manifested signs of L3 root compression. Radical pain syndrome in the lower extremity was caused by compression of the nerve roots in the foraminal opening on the concave side of the deformity and was confirmed by neuroimaging data.

When assessing the deformity type according to SRS-Schwab classification, the frontal modifier corresponded to type N (less than 30°) in 67 (94 %) cases; in four (6 %) patients, the frontal modifier corresponded to type L. The data of the sagittal balance before the operation were: PI-LL = 11.5/10 [4;17.5] (-13° to 45°), SVA-49/38 [22.2;63.5] (from -2 mm to 187 mm), PT = 23.3/22 [17.5;28] (from 3° to 48°). Parameters of the sagittal balance are shown in **Figure 1**.



**Fig. 1** Parameters of the sagittal balance before surgery (n = 71)

Patients with a PI-LL value of less than 10° are classified by the PI-LL modifier "0", with a value between 10 and 20° of the PI-LL modifier "+", and with a PI-LL modifier value greater than 20° "++".

Patients with SVA less than 40 mm are classified by SVA modifier "0", from 40 to 95 mm by SVA modifier "+", more than 95 mm by SVA modifier "++". Patients with PT less than 20° are classified by the PT modifier "0", between 20 and 30° "+", more than 30° by the PT modifier "++".

The sagittal modifier PI-LL "0" was detected in 41 (57.7 %) patients, the PI-LL "+" modifier was found in 16 (22.5 %) patients, the PI-LL "++" modifier was detected in 14 (19.8 %) patients.

The sagittal modifier SVA "0" was defined in 39 (55 %) patients, SVA "+" – in 21 (29.5 %) patients, SVA "++" – in 11 (15.5 %) patients.

The sagittal modifier PT "0" was determined in 32 (45 %) patients, PT "+" – in 24 (34 %) patients, PT "++" – in 15 (21 %) patients.

Functional radiography before the operation did not show instability of spinal units, which was based on the value 2.7 / 3 [2;3] points (less than 5 points by A.A. White – M.M. Panjabi).

Implants were installed according to the LLIF method at 2 levels in 47 (66 %) patients and at 3 levels in 24 (34 %) patients.

Blood loss was 247.9/200 [140;350] ml. The time of intervention was 223.5/210 [180;272.5] minutes. The number of inpatient days was 9.5 / 9 [8;11].

**Dynamics of the sagittal balance** In cases treated with two interbody cages by the method of LLIF, PI before surgery was 55.3/56° [51.5;64], LL was 43.9/46° [37.5;53]. In the postoperative period, LL was 47.6/50° [42.5;54.5] (p = 0.18). In three-level interbody fusion cases, the average PI before surgery was 56.6/55° [52.8;60.5], the average LL was 44.3/49° [38.5;51.5]. In the postoperative period, LL reached 47.2/ 48.5° [41;53.5] (p = 0.31).

The mean value of the Cobb's angle of scoliotic deformity before surgery was 19.5/18° [14;23], it decreased to 7.5 / 7° [5;11], ( $p < 0.001$ ) at follow-up.

At 12-month follow-up, no cases of correction loss in the frontal and sagittal planes were revealed. PT before surgery was 23.3/22° [17.5;28] and at a follow-up inspection it was 17.9/17° [15;20] ( $p < 0.001$ ). PI-LL was 11.5/10° [4;17.5], 12 months later it was 8.4/8° [5.5;11.5] ( $p = 0.11$ ). Analysis of the questionnaire data showed a statistically significant reduction in pain in the back (VAS) at 12 months after surgery from 6.1/6 [4;8] to 2.2/2 [2;3] points ( $p < 0.001$ ). Also in this period, there was a decrease in pain in the leg according to VAS from 5.4/5 [4;8] to 2.1/2 [1;3] points ( $p < 0.001$ ) and an improvement in functional adaptation from 51.2/52.2 [38.6;64.1] to 31.8 / 33.3 [26.1;35.9] ( $p < 0.001$ ) according to ODI. According to the SF-36 quality of life questionnaire, PH before surgery was on average 25.7/24.3 [21.8;28.9] points, and 12 months after the operation it improved to 38.7/38.7 [35.4;41.2] ( $p < 0.001$ ). Quality of life measures for SF-36: MH before surgery were 27.1/26.3 [21.8;31.4] points, 12 months after the surgery it also improved to 41.3 / 40.6 [36.5;43.7] ( $p < 0.001$ ).

Integral results of treatment are given in Table 1.

In 44 (62 %) out of 71 patients, the local sagittal balance was disturbed according to the modifiers PT and PI-LL, while SVA did not exceed 50 mm and was 21.7/25 [0;35.2]. In 38 % of patients (27 cases), we detected disorders of both local and global sagittal balance with SVA deviation up to 187 mm (SVA value was 93.7/88 [61.2, 111.8] mm). As a result of the surgical treatment aimed at correcting spino-pelvic alignment, an improvement in the index of the local sagittal balance such as PT ( $p < 0.001$ ) was noted. In patients with a disturbed global sagittal balance,

there was a statistically significant decrease in SVA to 24.2/25 [14;37] mm ( $p < 0.001$ ).

**Complications** We divided all the complications into neurological, related to instrumentation, and general. In the early postoperative period, five (7 %) patients experienced transient weakness of femur flexors on the ipsilateral side, which was caused by direct traumatization of the major psoas muscle. In 8 (11.2 %) patients, there was a decrease in pain and temperature sensitivity along the frontal surface of the thigh on the ipsilateral side of the surgery, which was caused by the irritated nervus genitofemoralis and nervus cutaneus femoris lateralis. In 7 (9.8 %) cases, these symptoms regressed within 6 months after the operation. Hypoesthesia had a persistent character in one (1.4 %) patient.

Of 474 implanted transpedicular screws, two (0.4 %) cases of medial malposition (grade 1 according to Rao) were detected in the early postoperative period according to the SCT. Lack of clinical symptoms in these cases did not require additional surgical interventions. In 7 (4.2 %) cases, according to SCT, damage to cortical endplates was revealed. At follow-up, pseudoarthrosis was verified at 2 (1.2 %) levels of interbody fusion with LLIF from 166 performed (Grade 4, Bridwell), which required a revision intervention.

General complications were two hematomas (2.8 %) of the surgical area which did not require re-intervention. Two patients developed paresis of the muscles of the anterior abdominal wall from the access side, which was 2.8 %, due to traction damage to the nervus iliohypogastricus during the access procedure. These patients wore a bandage and had dynamic observation in the postoperative period. Thus, the total number of complications was 29.6 %, of which 5.4 % were persistent or required repeated operations.

Table 1

Dynamics of parameters before surgery and after 12 months with levels of statistical significance obtained after using the test ( $p$ ) and corrected with Holm ( $p_{corr}$ )

Parameter	Before surgery	After surgery	p	$P_{corr}$
VAS back	6.1/6 [4;8]	2.2/2 [2;3]	< 0.001	< 0.001
VAS leg	5.4/5 [4;8]	2.1/2 [1;3]	< 0.001	< 0.001
PT	23.3/22 [17.5;28]°	17.9/17 [15;20]°	< 0.001	< 0.001
PI-LL	11.5/10 [4;17.5]°	8.4/8 [5.5;11.5]°	0.1057	0.1057
Cobb's angle	19.5/18 [14;23]°	7.5/7 [5;11]°	< 0.001	< 0.001
ODI	51.2/52.2 [38.6;64.1]	31.8/33.3 [26.1;35.9]	< 0.001	< 0.001
SF-36, PH	25.7/24.3 [21.8;28.9]	38.7/38.7 [35.4;41.2]	< 0.001	< 0.001
SF-36, MH	27.1/26.3 [21.8;31.4]	41.3/40.6 [36.5;43.7]	< 0.001	< 0.001



## DISCUSSION

The main goal of surgical treatment in ADS is to restore the disturbed balance of the spine in the sagittal and frontal planes to improve the quality of life, increase functional adaptation and reduce pain [25, 26]. The use of standard open methods of surgical correction of degenerative deformities in adults is associated with osteotomy, extended fixation of spinal segments, high blood loss, long inpatient stay, infectious complications, failure of fixation, PJK (proximal junctional kyphosis), DJK (distal junctional kyphosis) that may result in poor outcomes [27, 28]. Recently, a minimally invasive surgery has been used in combination with a short-segment fixation of the spine in a number of cases in such patients. Clinical and radiological outcomes of minimally invasive and open surgery have similar results, but the analysis of the works shows the non-systematic nature of their assessment.

*Clinical outcomes depending on balance parameters* According to some authors, the target parameters of spino-pelvic alignment, which should be sought in the treatment of patients with ADS are SVA, PT, PI-LL and Cobb's angle in the frontal plane [29, 30, 31]. The team of authors, led by Frank Schwab, determined that by deformity correction in the sagittal plane, it is necessary to be oriented by  $SVA < 50$  mm,  $PT < 20^\circ$  adjusted for age. To improve the quality of life in the postoperative period,  $PI-LL \leq 10^\circ$  was recommended to achieve in these patients, which significantly improves the quality of life [32].

However, the works of European scientists, such as J.C. Le Huec, C. Lamartina and P. Roussouly, found that the key to improving the quality of life in patients with ADS is the recovery of segmental lumbar lordosis. To assess the global sagittal balance, in their opinion, SSA (Spino sacral angle) is preferable to SVA [33]. This is due to the fact that compensation mechanisms, pelvic incidence, pelvic tilt flexion in the hip and knee joints are not taken into account. In order to ensure a normal SSA of  $134 \pm 8^\circ$ , they recommend the restoration of the local sagittal balance of the lumbar spine and, first of all, of the lower lumbar spinal segments L4-S1, which together make up almost 70 %. The calculation of LL should be based on PI and calculated by the formula:  $LL = PI \times 0.5 + 28^\circ$ .

The study of Lafage et al. analyzed the treatment results of 125 patients with degenerative scoliosis,

operated by minimally invasive procedures. All patients were divided into 4 groups: group 1 – low PT ( $< 25^\circ$ ), low SVA ( $< 50$  mm); group 2 – high PT ( $> 25^\circ$ ), low SVA ( $< 50$  mm); group 3 – low PT ( $< 25^\circ$ ), high SVA ( $> 50$  mm); group 4 – high PT ( $> 25^\circ$ ), high SVA ( $> 50$  mm). They found that in the group of patients with high SVA ( $> 50$  mm) and low PT ( $< 25^\circ$ ), the worst ODI values were observed [34], which correlates with the data of F. Schwab.

According to Takemoto et al, loss of mobility occurs at the operated levels in the postoperative period due to the development of spondylodesis, which can lead to a global sagittal imbalance due to limited compensatory ability to maintain a balanced posture while standing. The authors analyzed the treatment results of 204 patients operated on for degenerative scoliosis and found that there was a significant decrease in the quality of life in patients with sagittal imbalance and low PT ( $< 20^\circ$ ) in the postoperative period. Thus, the absence of pelvic compensatory mechanisms, underestimation of the parameters of both local and global sagittal balance can lead to impairment in the quality of life and functional adaptation after ADS surgery [35].

Zhang et al. retrospectively analyzed treatment results of 44 patients with adult degenerative scoliosis. All operations were performed with a standard posterior open method with instrumentation and correction of scoliotic deformity. The recovery of the sagittal PI-LL modifier led to an improvement in the quality of life according to the ODI score [36].

In 2017, Sun et al. published a retrospective analysis of the treatment results of 74 patients with ADS operated on with standard posterior open access. All patients were divided into three groups. Group A – with  $PI-LL < 10^\circ$ , group B -  $10^\circ \leq PI-LL \leq 20^\circ$ , group C –  $PI-LL > 20^\circ$ . In group A, after the operation, ODI was  $26.6 \pm 4.1$  at follow-up, in group B ODI was  $18.4 \pm 5.8$ , in group C in the postoperative period the ODI was  $33.0 \pm 5.0$  ( $P < 0.001$ ) [37]. It shows that when the sagittal modifier PI-LL was restored within the range of  $10^\circ$ – $20^\circ$ ; the quality of life improved significantly.

Kotwal et al. retrospectively analyzed the treatment results of 118 patients with spinal deformities operated with the LLIF method. According to this study, pain estimated by VAS decreased from  $8.7 \pm 1.3$  to

$4.1 \pm 2.8$  in the postoperative period; the quality of life according to ODI improved from  $30 \pm 10.1$  to  $17.1 \pm 12.8$ ; estimation of functional adaptation by SF-12: PH also improved from  $27.0 \pm 1.3$  to  $38.1 \pm 15.0$ , MH from  $43.0 \pm 11.4$  to  $42.4 \pm 11.9$  ( $P < 0, 01$ ) [38].

Lee et al. retrospectively analyzed treatment results of 168 patients who had short-segment fixation of the lumbar spine. Fifty-six patients with abnormal sagittal balance were operated according to the LLIF technique while 56 patients with normal sagittal balance (SB) and 56 patients with imbalance (SI) in the sagittal plane were operated with standard posterior approach. In the postoperative period, the ODI quality of life and the pain score by VAS were improved statistically significant in the LLIF group when compared to the SI group ( $p = 0.003, 0.016$ ) [39].

Studies of Anand et al. [40] and Diaz et al. [41] reported comparable treatment results in patients who underwent minimally invasive surgery using LLIF technology and concluded that segmental lordosis correction with LLIF method significantly improves quality of life and relieves pain in patients with ADS.

Konovalov et al. in their study reported a statistically significant reduction in pain by VAS score in patients operated according to the LLIF method in the lumbar spine from  $8.06 \pm 1.87$  to  $1.4 \pm 1.51$  and in the legs from  $6.14 \pm 2, 32$  to  $0.66 \pm 0.41$  [42].

Our study showed that positive dynamics was also statistically significant for pain relief in the lumbar spine ( $p < 0.001$ ) and legs ( $p < 0.001$ ) as well as for improvement in the quality of life and functional adaptation.

*Clinical outcomes depending on the correction of deformity* Since the ADS surgery involves correction in the sagittal and frontal planes, it makes sense to evaluate correction obtained with various surgical approaches.

Simon et al. retrospectively analyzed the treatment results of 47 patients with degenerative scoliosis of the thoracic and lumbar spine. All patients were operated with standard posterior open procedures. Before surgery, the average lumbar arch was  $27.3^\circ$  and the thoracic arch was  $40.2^\circ$ . In the postoperative period, the mean value of the lumbar arch was  $14.3^\circ$ , and the thoracic arch was  $24.3^\circ$  [43].

In his study, J.S. Smith et al. reported that before the operation the magnitude of scoliotic deformity was from  $43^\circ$  to  $54^\circ$  ( $p = 0.002$ ), SVA

was  $12\text{ cm}$  to  $1.7\text{ cm}$  ( $p < 0.001$ ), PI-LL was  $26^\circ$  to  $20^\circ$  ( $p = 0.013$ ). at a follow-up after a year, SVA was from  $-1.1\text{ cm}$  to  $+4.8\text{ cm}$  ( $p \leq 0.009$ ), PI-LL from  $6^\circ$  to  $5^\circ$  ( $p < 0.001$ ) [44].

Zhang et al. in their study reported a statistically significant decrease in the Cobb's angle from  $20.6 \pm 3.4^\circ$  to  $4.4 \pm 1.4^\circ$  ( $p < 0.004$ ) and PI-LL from  $36.6 \pm 4.6^\circ$  to  $18.4 \pm 2.9^\circ$  ( $P < 0.001$ ) in the postoperative period [36]. Sun et al. in their study reported that the PI-LL index decreased significantly in all groups from  $36.0 \pm 4.4^\circ$  to  $16.6 \pm 8.7^\circ$  ( $p < 0.05$ ). The Cobb's angle also decreased after surgery from  $20.3 \pm 2.8^\circ$  to  $4.2 \pm 1.8^\circ$  [37].

Thus, Barone et al. retrospectively analyzed treatment results of 65 patients operated according to the LLIF method with the installation of lordized interbody implants to  $10^\circ$  and  $20^\circ$ . Studying the dynamics of the segmental angle parameters Cobb's angle, LL, SVA < PT, PI-LL, the authors demonstrated that the use of lordized interbody implants results in an increase in segmental and local lordosis of the lumbar spine and, as a consequence, on restoration of the global sagittal balance of the body [45].

In their study, Tormenti et al. also proved that the use of the LLIF technique leads to correction of the spinal deformity in both the frontal and sagittal planes with a decrease in the Cobb angle from  $38.5^\circ$  ( $18^\circ$  to  $80^\circ$ ) to  $10^\circ$  ( $p < 0.0001$ ) and significant increase in LL by  $11.5\%$  ( $p = 0.01$ ) [46].

Kotwal et al. reported that scoliotic deformity according to Cobb decreased from  $24.8 \pm 9.8^\circ$  to  $13.6 \pm 10.3^\circ$  ( $p < 0.01$ ) in the postoperative period [38].

In the work mentioned above, Lee and colleagues analyzed the parameters of SVA and PI-LL in three groups of patients (SB, SI, LLIF) one year after the operation, showing a statistically significant decrease in SVA only in the LLIF-treated group to  $31.7 \pm 17.2$  ( $p = 0.000$ ). Also in the LLIF group, the PI-LL index decreased from  $29.6 \pm 19.3^\circ$  to  $15.9 \pm 14.8^\circ$  ( $p = 0.012$ ) [39].

According to our data, PT before surgery was  $23.3/22^\circ$  [17.5;28]; at follow-up, PT decreased significantly to  $17.9/17^\circ$  [15;20] ( $p < 0.001$ ). We also achieved a decrease in such a parameter as PI-LL and an increase in the local lumbar lordosis. The lack of statistical significance of the differences obtained by LL and PI-LL is related, in our opinion, to large heterogeneity of the group with regard to PI since LL

and its dependent value PI-LL are determined by PI. The angle of scoliotic deformity by Cobb in the postoperative period decreased significantly ( $p < 0.001$ ). At follow-up study after 12 months, no correction loss was found.

Thus, the analysis of available literature data and of the results of our study suggests that deformity correction by standard open posterior approach and LLIF correction in combination with MIS TPF provides similar results for LL, PT, PI-LL and Cobb's angle.

*Clinical outcomes depending on surgical tactics*

The choice of surgical tactics in ADS patients, especially in the older age group, should constitute a reasonable compromise between the scope of surgical intervention and the associated operational risks. This is due to high rates of comorbidity, osteoporosis, and excessive body weight. Consequently, the use of minimally invasive surgical techniques in these patients will reduce the amount of blood loss, the number of complications and inpatient stay.

It was shown in a large number of clinical trials that it is recommended to use various variants of osteotomy with standard surgical techniques for correcting degenerative scoliotic deformities of the spine that are associated with large surgical aggression, high blood loss, a significant number of complications, both during surgery and in the postoperative period, long stay in the hospital, a long recovery and rehabilitation periods [44, 47]. Thus, Simon et al. reported that the average operation time was  $284.5 \pm 30.2$  minutes, blood loss of  $1040.5 \pm 1207.6$  ml, stay in the hospital was  $14.5 \pm 1.9$  days [43]. Sun et al. in their study reported that the average operation time was  $237.8 \pm 39.7$  minutes, blood loss was  $1017.2 \pm 813.3$  ml, inpatient stay was  $14.5 \pm 1.3$  days [37]. Kim et al., after analyzing a group of patients operated with standard open posterior access, showed that the mean operation time was  $268 \pm 82$  min, the average blood loss was  $4392 \pm 3576$  ml [47].

The use of LLIF technology in the surgical treatment of ADS is accompanied by a much smaller amount of intraoperative blood loss. Anand et al. reported that the volume of hemorrhage by lateral approach was 241 ml [40]. In her thesis, M.A. Martynova determined that the average volume of blood loss in patients operated with LLIF was  $163.9 \pm 50$  ml [48]. Kotwal et al. in their study showed that in 16

patients who had interbody fusion only with LLIF, the average operation time was 184 minutes (88-256 minutes) and blood loss was 200 ml. In 112 cases, when interbody fusion was combined with posterior fixation, the average operation time was 324 minutes (75-690 minutes), the average blood loss was 537 ml, the average stay in the hospital was 7.7 days (2-22 days) [38].

In our study, the average volume of blood loss was 247.9/200 [140;350] ml. The time of operative intervention was 223.5 / 210 [180;272.5] minutes. The inpatient stay was 9.5 / 9 [8;11] days.

*Clinical outcomes depending on the detected complications* In 2011, Charosky et al. retrospectively analyzed the medical records of 306 patients with ADS. All operations were performed by standard open posterior approach. The overall incidence of complications was 13.7 %. Early infection was detected in 4 % (12) patients and late infection in 1.2 % of cases; neurologic complications accounted for 7 %. Risk factors for the development of complications were: the number of instrumented segments ( $p \leq 0.01$ ), osteotomy PSO ( $p = 0.01$ ) and PT more than  $26^\circ$  before surgery ( $p \leq 0.05$ ) [49].

The group of authors (Smith et al.) analyzed treatment results of 578 patients in who 402 osteotomies were performed. PSO (Pedicicle subtraction osteotomy) was used in 215 cases. SPO (Smith-Petersen osteotomy) was performed in 135 cases, VCR (vertebral column resection) in 18 cases. The total number of complications was 29.4 % (130 patients). The most common complication was damage to dura mater (5.9 %). Infectious complications were 3.8 %; neurological deficit was detected in 3.8 % [44]. Similar data in the analysis of three-column osteotomies made from dorsal access were presented by Kim et al. Thus, seven (8.6 %) patients were diagnosed with dura mater lesions; deep infection happened in four (4.9 %) patients, and permanent neurologic deficiency was detected in one (1.2 %) patient [47].

A group of authors led by Daubs revealed an incidence of general complications which was 37 %. Of these, 20 % were major complications, such as neurological deficit in four cases; deep wound infection in two, pulmonary embolism in one case, pneumonia in one case, myocardial infarction in one case. Intraoperative complications occurred in 11 patients: damage to dura mater in four cases, iliac

vein rupture in five cases, one case of symptomatic medial malposition, and one case of nerve root damage [50].

The concept of minimally invasive surgery is as follows by using the LLIF technique for adult deformity: less skin and soft tissue trauma, less bone defect, no contact with dura mater, reduction of soft tissue retractor lesions significantly reduces infectious wound complications, blood loss and inpatient stays. The interbody implant has a large contact area in comparison with other implants and rests on the marginal dense part of the endplate, thereby creating a greater support for the anterior support column while maintaining the middle and posterior supporting complex of the spine. Lateral interbody fusion does not require resection of bone structures, while indirect decompression is performed without opening the spinal canal, the height of the interbody gap and the size of the intervertebral openings are restored. With LLIF technology, the anterior and posterior longitudinal ligaments remain preserved, which prevents the migration of the interbody implant and increases the dynamic stability due to ligamentotaxis. However, the application of this technique has its specific complications: weakness of the muscles of the femur flexors and a decrease in sensitivity, paresthesia along the anterolateral surface of the thigh in the postoperative period on the ipsilateral side.

Tohmeh et al. analyzed the treatment results of 102 patients operated on for degenerative diseases of the lumbar spine according to the LLIF technique. In the postoperative period, the weakness of the muscles of the femur flexors was observed in 28 patients (27.5 %). Eighteen (17.6 %) patients had a decrease in sensitivity on the anterior surface of the thigh due to irritation of the nervus genitofemoralis and nervus cutaneus femoris lateralis. However, sensory and

motor complications completely regressed within 6 months after surgery [51].

Pumberger et al. retrospectively analyzed the treatment results of 235 patients operated according to the LLIF method. The authors reported that the sensory deficit was 28.7 % (n = 70) at six weeks after the operation, after 12 weeks 13.1 % (n = 32), after 6 months 5.7 % (n = 14) and 1.6 % (n = 4) 12 months after the operation. Pain on the anterior surface of the thigh was observed in 41 % (n = 101) patients at 6 weeks after the operation; after 12 weeks in 16 % (n = 39) of patients, after 6 months in 3.7 % (n = 9) and in 0.8 % (n = 2) after 12 months. The weakness of the muscles of the femur flexors six weeks after the operation was 13.1 % (n = 32), after 12 weeks 3.7 % (n = 9), after 6 months 2.9 % (n = 7) and 12 months after the residual muscle weakness of flexor muscles was 1.6 % (n = 4) [14]. Similar data were obtained by Kotwal et al. In the postoperative period, 43 (36 %) patients had pain on the anterior surface of the thigh, weakness of the femur flexors was noted in 20 cases, numbness in the anterior thigh was revealed in 13 patients [38]. According to the authors, the weakness of the muscles of the femur flexors is due to the direct trauma to the psoas muscle during access to the lateral spine and traction during operation, rather than trauma to the lumbar plexus.

According to our data, five (7 %) patients developed transient weakness of femur flexors. Eight (11.2 %) showed a decrease in the sensitivity to pain and temperature on the anterior surface of the thigh. The total number of complications was 29.6 %, of which 5.4 % were persistent or requiring repeated operations. The standard use of LLIF technology enables to completely exclude contact with dura mater so its damage during the surgery is not possible.

## CONCLUSIONS

1. The use of LLIF in patients with ADS with an curve type N ( $\leq 30^\circ$ ) according to Schwab provides adequate surgical correction of the deformity of the spine both in the sagittal and frontal planes.

2. Restoration of the disturbed local sagittal balance in these patients by short-segmental fixation using LLIF technology results in a statistically

significant improvement in the quality of life and in functional adaptation of patients.

3. A significantly lower number of early and late postoperative complications, less intraoperative bleeding and shorter hospital stay make LLIF in combination with MIS TPF a method of choice in surgical treatment tactics in elderly and old patients with ADS.



## REFERENCES

- Schwab F., Dubey A., Gamez L., El Fegoun A.B., Hwang K., Pagala M., Farcy J.P. Adult scoliosis: prevalence, SF-36, and nutritional parameters in an elderly volunteer population. *Spine*, 2005, vol. 30, no. 9, pp. 1082-1085.
- Kobayashi T., Atsuta Y., Takemitsu M., Matsuno T., Takeda N. A prospective study of de novo scoliosis in a community based cohort. *Spine*, 2006, vol. 31, no. 2, pp. 178-182.
- Aebi M. The adult scoliosis. *Eur. Spine J.*, 2005, vol. 14, no. 10, pp. 925-948. DOI: 10.1007/s00586-005-1053-9.
- Glassman S.D., Bridwell K., Dimar J.R., Horton W., Berven S., Schwab F. The impact of positive sagittal balance in adult spinal deformity. *Spine*, 2005, vol. 30, no. 18, pp. 2024-2029.
- Liu S., Schwab F., Smith J.S., Klineberg E., Ames C.P., Mundis G., Hostin R., Kebaish K., Deviren V., Gupta M., Boachie-Adjei O., Hart R.A., Bess S., Lafage V. Likelihood of reaching minimal clinically important difference in adult spinal deformity: a comparison of operative and nonoperative treatment. *Ochsner. J.*, 2014, vol. 14, no. 1, pp. 67-77.
- Zheng X., Chaudhari R., Wu C., Mehbod A.A., Transfeldt E.E., Winter R.B. Repeatability test of C7 plumb line and gravity line on asymptomatic volunteers using an optical measurement technique. *Spine*, 2010, vol. 35, no. 18, pp. E889-E894.
- Mac-Thiong J.M., Rousouly P., Berthonnaud E., Guigui P. Sagittal parameters of global spinal balance: normative values from a prospective cohort of seven hundred nine Caucasian asymptomatic adults. *Spine*, 2010, vol. 35, no. 22, pp. E1193-E1198. DOI: 10.1097/BRS.0b013e3181e50808.
- Berjano P., Lamartina C. Far lateral approaches (XLIF) in adult scoliosis. *Eur. Spine J.*, 2013, vol. 22, no. Suppl. 2, pp. S242-S253. DOI: 10.1007/s00586-012-2426-5.
- DeWald C.J., Stanley T. Instrumentation-related complications of multilevel fusions for adult spinal deformity patients over age 65: surgical considerations and treatment options in patients with poor bone quality. *Spine*, 2006, vol. 31, no. 19 Suppl., pp. S144-S151. DOI: 10.1097/01.brs.0000236893.65878.39.
- Ozgur B.M., Aryan H.E., Pimenta L., Taylor W.R. Extreme Lateral Interbody Fusion (XLIF): a novel surgical technique for anterior lumbar interbody fusion. *Spine J.*, 2006, vol. 6, no. 4, pp. 435-443. DOI:10.1016/j.spinee.2005.08.012.
- Pimenta L., Vigna F., Bellera F., Schaffa T., Malcolm J., McAfee P. A new minimally invasive surgical technique for adult lumbar degenerative scoliosis. Proc. 11th Intern. Meeting on Advanced Spine Techniques (IMAST). Southampton, Bermuda, 2004.
- Acosta F.L., Liu J., Slimack N., Moller D., Fessler R., Koski T. Changes in coronal and sagittal plane alignment following minimally invasive direct lateral interbody fusion for the treatment of degenerative lumbar disease in adults: a radiographic study. *J. Neurosurg. Spine*, 2011, vol. 15, no. 1, pp. 92-96. DOI: 10.3171/2011.3.SPINE10425.
- Tormenti M.J., Maserati M.B., Bonfield C.M., Okonkwo D.O., Kanter A.S. Complications and radiographic correction in adult scoliosis following combined transpoas extreme lateral interbody fusion and posterior pedicle screw instrumentation. *Neurosurg. Focus*, 2010, vol. 28, no. 3, pp. E7. DOI: 10.3171/2010.1.FOCUS09263.
- Pumberger M., Hughes A.P., Huang R.R., Sama A.A., Cammisa F.P., Girardi F.P. Neurologic deficit following lateral lumbar interbody fusion. *Eur. Spine J.*, 2012, vol. 21, no. 6, pp. 1192-1199. DOI: 10.1007/s00586-011-2087-9.
- Fairbank J.C., Pynsent P.B. The Oswestry Disability Index. *Spine*, 2000, vol. 25, no. 22, pp. 2940-2952.
- Ware J.E., Kosinski M., Keller S.D. *SF-36 Physical and Mental Health Summary Scales: A User's Manual*. Boston, Mass., the Health Institute, New England Medical Center, 1994.
- Cobb J.R. *Outline for the study of scoliosis. The American Academy of Orthopedic Surgeons Instructional Course Lectures*. Vol. 5. Ann Arbor, MI, Edwards, 1948.
- Schwab F., Lafage R., Liabaud B., Diebo B., Smith J., Hostin R., Shaffrey C., Boachie-Adjei O., Ames C., Scheer J., Burton D., Bess S., Munish C. Does One Size Fit All? Defining Spinopelvic Alignment Thresholds Based on Age. *Spine J.*, 2014, vol. 14, pp. S120-S121.
- Le Huec J.C., Hasegawa K. Normative values for the spine shape parameters using 3D standing analysis from a database of 268 asymptomatic Caucasian and Japanese subjects. *Eur. Spine J.*, 2016, vol. 25, no. 11, pp. 3630-3637. DOI: 10.1007/s00586-016-4485-5.
- White A.A., Panjabi M.M. *Clinical Biomechanics of the Spine*. J.B. Lippincott Company, 1978.
- Bridwell K.H., Lenke L.G., McEnery K.W., Baldus C., Blanke K. Anterior fresh frozen structural allografts in the thoracic and lumbar spine. Do they work if combined with posterior fusion and instrumentation in adult patients with kyphosis or anterior column defects? *Spine*, 1995, vol. 20, no. 12, pp. 1410-1418.
- Rao G., Brodke D.S., Rondina M., Bacchus K., Dailey A.T. Inter- and intraobserver reliability of computed tomography in assessment of thoracic pedicle screw placement. *Spine*, 2003, vol. 28, no. 22, pp. 2527-2530. DOI: 10.1097/01.BRS.0000092341.56793.F1.
- Steurer J., Roner S., Gnannt R., Hodler J.; LumbSten Research Collaboration. Quantitative radiologic criteria for the diagnosis of lumbar spinal stenosis: a systematic literature review. *BMC Musculoskelet. Disord.*, 2011, vol. 12, pp. 175. DOI:10.1186/1471-2474-12-175.
- R Development Core Team, *R: A Language and Environment for Statistical Computing*. Vienna, Austria: the R Foundation for Statistical Computing, 2011. Available at: <https://www.R-project.org/>.

25. Charosky S., Guigui P., Blamoutier A., Roussouly P., Chopin D.; Study Group on Scoliosis. Complications and risk factors of primary adult scoliosis surgery: a multicenter study of 306 patients. *Spine*, 2012, vol. 37, no. 8, pp. 693-700. DOI: 10.1097/BRS.0b013e31822ff5c1.
26. Lafage V., Schwab F., Patel A., Hawkinson N., Farcy J.P. Pelvic tilt and truncal inclination: two key radiographic parameters in the setting of adults with spinal deformity. *Spine*, 2009, vol. 34, no. 17, pp. E599-E606. DOI: 10.1097/BRS.0b013e3181aad219.
27. Smith J.S., Shaffrey C.I., Klineberg E., Lafage V., Schwab F., Lafage R., Kim H.J., Hostin R., Mundis G.M. Jr., Gupta M., Liabaud B., Scheer J.K., Diebo B.G., Protosaltis T.S., Kelly M.P., Deviren V., Hart R., Burton D., Bess S., Ames C.P.; on behalf of the International Spine Study Group. Complication rates associated with 3-column osteotomy in 82 adult spinal deformity patients: retrospective review of a prospectively collected multicenter consecutive series with 2-year follow-up. *J. Neurosurg. Spine*, 2017, vol. 27, no. 4, pp. 444-457. DOI: 10.3171/2016.10.SPINE16849.
28. Hyun S.J., Lee B.H., Park J.H., Kim K.J., Jahng T.A., Kim H.J. Proximal Junctional Kyphosis and Proximal Junctional Failure Following Adult Spinal Deformity Surgery. *Korean J. Spine*, 2017, vol. 14, no. 4, pp. 126-132. DOI: 10.14245/kjs.2017.14.4.126.
29. Schwab F., Farcy J.P., Bridwell K., Berven S., Glassman S., Harrast J., Horton W. A clinical impact classification of scoliosis in the adult. *Spine*, 2006, vol. 31, no. 18, pp. 2109-2114. DOI: 10.1097/01.brs.0000231725.38943.ab.
30. Schwab F., Lafage V., Farcy J.P., Bridwell K.H., Glassman S., Shainline M.R. Predicting outcome and complications in the surgical treatment of adult scoliosis. *Spine*, 2008, vol. 33, no. 20, pp. 2243-2247. DOI: 10.1097/BRS.0b013e31817d1d4e.
31. Schwab F., Lafage V., Farcy J.P., Bridwell K., Glassman S., Ondra S., Lowe T., Shainline M. Surgical rates and operative outcome analysis in thoracolumbar and lumbar major adult scoliosis: application of the new adult deformity classification. *Spine*, 2007, vol. 32, no. 24, pp. 2723-2730. DOI: 10.1097/BRS.0b013e31815a58f2.
32. Schwab F.J., Smith V.A., Biserni M., Gamez L., Farcy J.P., Pagala M. Adult scoliosis: a quantitative radiographic and clinical analysis. *Spine*, 2002, vol. 27, no. 4, pp. 387-392.
33. Schwab F., Bess S., Blondel B., Lafage V. Combined assessment of pelvic tilt, pelvic incidence/lumbar lordosis mismatch and sagittal vertical axis predicts disability in adult spinal deformity: a prospective analysis. *Spine J.*, 2011, vol. 11, pp. S158-S159.
34. Roussouly P., Gollogly S., Nosedá O., Berthonnaud E., Dimnet J. The vertical projection of the sum of the ground reactive forces of a standing patient is not the same as the C7 plumb line: a radiographic study of the sagittal alignment of 153 asymptomatic volunteers. *Spine*, 2006, vol. 31, no. 11, pp. E320-E325. DOI: 10.1097/01.brs.0000218263.58642.ff.
35. Lafage V., Schwab F., Patel A., Hawkinson N., Farcy J.-P. Pelvic tilt and truncal inclination: two key radiographic parameters in the setting of adults with spinal deformity. *Spine*, 2009, vol. 34, no. 17, pp. E599-E606. DOI: 10.1097/BRS.0b013e3181aad219.
36. Takemoto M., Boissière L., Vital J.M., Pellisé F., Perez-Grueso F.J.S., Kleinstück F., Acaroglu E.R., Alanay A., Obeid I. Are sagittal spinopelvic radiographic parameters significantly associated with quality of life of adult spinal deformity patients? Multivariate linear regression analyses for pre-operative and short-term post-operative health-related quality of life. *Eur. Spine J.*, 2017, vol. 26, no. 8, pp. 2176-2186. DOI: 10.1007/s00586-016-4872-y.
37. Zhang H.C., Zhang Z.F., Wang Z.H., Cheng J.Y., Wu Y.C., Fan Y.M., Wang T.H., Wang Z. Optimal Pelvic Incidence Minus Lumbar Lordosis Mismatch after Long Posterior Instrumentation and Fusion for Adult Degenerative Scoliosis. *Orthop. Surg.*, 2017, vol. 9, no. 3, pp. 304-310. DOI: 10.1111/os.12343.
38. Sun X.Y., Zhang X.N., Hai Y. Optimum pelvic incidence minus lumbar lordosis value after operation for patients with adult degenerative scoliosis. *Spine J.*, 2017, vol. 17, no. 7, pp. 983-989. DOI: 10.1016/j.spinee.2017.03.008.
39. Kotwal S., Kawaguchi S., Lebl D., Hughes A., Huang R., Sama A., Cammisa F., Girardi F. Minimally Invasive Lateral Lumbar Interbody Fusion: Clinical and Radiographic Outcome at a Minimum 2-year Follow-up. *J. Spinal Disord. Tech.*, 2015, vol. 28, no. 4, pp. 119-125. DOI: 10.1097/BSD.0b013e3182706ce7.
40. Lee B.H., Yang J.H., Kim H.S., Suk K.S., Lee H.M., Park J.O., Moon S.H. Effect of Sagittal Balance on Risk of Falling after Lateral Lumbar Interbody Fusion Surgery Combined with Posterior Surgery. *Yonsei Med. J.*, 2017, vol. 58, no. 6, pp. 1177-1185. DOI: 10.3349/ymj.2017.58.6.1177.
41. Anand N., Rosemann R., Khalsa B., Baron E.M. Mid-term to long-term clinical and functional outcomes of minimally invasive correction and fusion for adults with scoliosis. *Neurosurg. Focus*, 2010, vol. 28, no. 3, pp. E6. DOI: 10.3171/2010.1.FOCUS09278.
42. Diaz R., Phillips F., Pimenta L., Guerrero L. XLIF for lumbar degenerative scoliosis: outcomes of minimally invasive surgical treatment out to 3 years postoperatively. *Spine J.*, 2006, vol. 6, no. 5 Suppl., pp. 75S-75S.
43. Konovalov N.A., Nazarenko A.G., Krut'ko A.V., Glukhikh D.L., Durni P., Duris M., Korol' O., Asyutin D., Solenkova A.V., Martynova M.A. Results of surgical treatment for lumbar spine segmental instability. *Zh. Vopr. Neurokhir. Im. N.N. Burdenko*, 2017, vol. 81, no. 6, pp. 69-80. DOI: 10.17116/neiro201781669-80. (in Russian)
44. Simon J., Longis P.M., Passuti N. Correlation between radiographic parameters and functional scores in degenerative lumbar and thoracolumbar scoliosis. *Orthop. Traumatol. Surg. Res.*, 2017, vol. 103, no. 2, pp. 285-290. DOI: 10.1016/j.otsr.2016.10.021.

45. Smith J.S., Singh M., Klineberg E., Shaffrey C.I., Lafage V., Schwab F.J., Protopsaltis T., Ibrahim D., Scheer J.K., Mundis G. Jr., Gupta M.C., Hostin R., Deviren V., Kebaish K., Hart R., Burton D.C., Bess S., Ames C.P.; International Spine Study Group. Surgical treatment of pathological loss of lumbar lordosis (flatback) in patients with normal sagittal vertical axis achieves similar clinical improvement as surgical treatment of elevated sagittal vertical axis: clinical article. *J. Neurosurg. Spine*, 2014, vol. 21, no. 2, pp. 160-170. DOI: 10.3171/2014.3.SPINE13580.
46. Barone G., Scaramuzzo L., Zagra A., Giudici F., Perna A., Proietti L. Adult spinal deformity: effectiveness of interbody lordotic cages to restore disc angle and spino-pelvic parameters through completely mini-invasive trans-psoas and hybrid approach. *Eur. Spine J.*, 2017, vol. 26, no. Suppl. 4, pp. 457-463. DOI: 10.1007/s00586-017-5136-1.
47. Tormenti M.J., Maserati M.B., Bonfield C.M., Okonkwo D.O., Kanter A.S. Complications and radiographic correction in adult scoliosis following combined transpsoas extreme lateral interbody fusion and posterior pedicle screw instrumentation. *Neurosurg. Focus*, 2010, vol. 28, no. 3, pp. E7. DOI: 10.3171/2010.1.FOCUS09263.
48. Kim S.S., Cho B.C., Kim J.H., Lim D.J., Park J.Y., Lee B.J., Suk S.I. Complications of posterior vertebral resection for spinal deformity. *Asian Spine J.*, 2012, vol. 6, no. 4, pp. 257-265. DOI: 10.4184/asj.2012.6.4.257.
49. Martynova M.A. *Sravnitelnyi analiz iskhodov khirurgicheskogo lecheniia patsientov s nestabilnostiu pozvonochno-dvigatel'nogo segmenta poiasnichnogo otdela pozvonochnika s primeneniem tekhnologii transforaminal'nogo mezhtelovogo (TLIF) i priamogo bokovogo spondilodeza (DLIF)*. Diss. kand. med. nauk [A comparative analysis of the outcomes of surgical treatment of patients with the lumbar spinal-motor segment instability using the technologies of transforaminal interbody (TLIF) and direct lateral spondylodesis (DLIF). Cand. med. sci. diss.]. Moscow, 2016. (in Russian)
50. Charosky S., Guigui P., Blamoutier A., Roussouly P., Chopin D.; Study Group on Scoliosis. Complications and risk factors of primary adult scoliosis surgery: a multicenter study of 306 patients. *Spine*, 2012, vol. 37, no. 8, pp. 693-700. DOI: 10.1097/BRS.0b013e31822ff5c1.
51. Daubs M.D., Lenke L.G., Cheh G., Stobbs G., Bridwell K.H. Adult spinal deformity surgery: complications and outcomes in patients over age 60. *Spine*, 2007, vol. 32, no. 20, pp. 2238-2244.
52. Tohmeh A.G., Rodgers W.B., Peterson M.D. Dynamically evoked, discrete-threshold electromyography in the extreme lateral interbody fusion approach. *J. Neurosurg. Spine*, 2011, vol. 14, no. 1, pp. 31-37. DOI: 10.3171/2010.9.SPINE09871.

Received: 12.04.2018

#### Information about the authors:

1. Vladimir S. Klimov, M.D., Ph.D.,  
Federal Neurosurgical Center, Novosibirsk, Russian Federation;  
Email: v\_klimov@neuronsk.ru
2. Ivan I. Vasilenko, M.D.,  
Federal Neurosurgical Center, Novosibirsk, Russian Federation;  
Email: i\_vasilenko@neuronsk.ru
3. Alexey V. Evsyukov, M.D., Ph.D.,  
Federal Neurosurgical Center, Novosibirsk, Russian Federation;  
Email: a\_evsyukov@neuronsk.ru
4. Roman V. Khalepa, M.D.,  
Federal Neurosurgical Center, Novosibirsk, Russian Federation;  
Email: r\_halepa@neuronsk.ru
5. Evgeniya V. Amelina, Ph.D. of Physico-mathematical Sciences,  
Novosibirsk State University, Novosibirsk, Russian Federation;  
Email: amelina.evgenia@gmail.com
6. Sergey O. Ryabykh, M.D., Ph.D.,  
Russian Ilizarov Scientific Center for Restorative Traumatology and Orthopaedics, Kurgan, Russian Federation;  
Email: rso\_@mail.ru
7. Jamil Afet ogly Rzaev, M.D., Ph.D.,  
Federal Neurosurgical Center, Novosibirsk, Russian Federation;  
Email: d\_rzaev@neuronsk.ru