

Management of forearm bone gap non-unions by Ilizarov technique

M.M. Bari, Shahidul Islam, N.H. Shetu, Mahfuzer Rahman

Bari-Ilizarov Orthopaedic Centre, Dhaka, Bangladesh

Purpose Proper treatment of forearm bone gap non-union should achieve both biological stimulation of the bone and elastic mechanical stability. The use of Ilizarov technique enhances the healing of a non-union providing osteogenic, osteoconductive and an optimal stability with the Ilizarov fixation. We retrospectively reviewed 26 patients affected by forearm bone non-union and treated with the Ilizarov fixation. **Materials and Methods** Twenty six patients were treated for gap non-unions of forearm bones with the Ilizarov compression distraction device from 2000 to 2015 in BARI-ILIZAROV ORTHOPAEDIC CENTRE. **Results** All the difficult non-unions healed in a mean of 7 months, ranging from 5 to 12 months. At the latest follow-up, forearm functions were satisfactory. **Conclusion** The Ilizarov compression distraction device is a fantastic tool in promoting the healing of forearm non-unions, even if the bones are very atrophic.

Keywords: Forearm bone non-union, Distraction osteogenesis, Ilizarov technique

Different factors like fracture location and complexity, patient characteristics and surgical intervention are involved in the development of forearm bone non-union [1, 2].

Radius and ulna non-unions are usually associated with complex injury, inadequate initial reduction, and unstable fixation. Anatomical and functional relationship between the radius and ulna is so peculiar that it represents a sophisticated functional unit. That is why fractures of the radius and ulna should be considered like articular fractures [3].

The function of the forearm is to assist the hand in space positioning and to support the hand movements. Pronation and supination of the forearm occurs at the radiohumeral, proximal radioulnar, and distal radioulnar joints. Failure of the relationship between the radius and ulna due to the changes in the length impairs the forearm function and the ability to position the hand in space. When non-union occurs in the forearm bones it impairs forearm, elbow and wrist motion. In these cases fracture healing is a necessary condition to recover the physiological function of the upper limb.

Based on the characteristics of the bone ends, an

aseptic non-union can be distinguished into atrophic and hypertrophic [4]. Adequate treatment of forearm bone non-union must be considered, providing with biological stimulation and elastic mechanical stability by the Ilizarov technique. Ilizarov fixator promotes osteogenesis, osteoconduction, osteoinduction, mechanical properties and vascularity [5].

Autologous bone grafting is the transplantation of the bone of the same individual from an anatomical donor site to the recipient site. Compared to autograft, allografts are easier to use, require less surgical time and are potentially unlimited in amount. However, allograft presents disadvantages such as a higher risk of infection, viral disease transmission and the need of a bone bank available to the hospital [6, 7].

The aim of this study was to show the treatment of gap non-unions of the forearm bones by the Ilizarov technique through distraction osteogenesis without bone grafting. We retrospectively reviewed 26 patients and assessed the use of the Ilizarov method in terms of:

- 1) Rate of healing of non-union without grafting;
- 2) Time of healing,
- 3) and functional results.

MATERIALS AND METHODS

From 2000 to 2015, a total of 26 patients with non-unions of the forearm bones were treated with the Ilizarov compression-distraction device. We consider a non-union as an “arrest of bony fracture repair process with the formation of fibrous or cartilaginous tissue between the main fragments when fracture remains un-united for 6 to 9 months due to mechanical or biological failure

judged by clinical and radiological evidence”.

Exclusion criteria were:

- 1) Presence of other fractures in the same limb at the time of the primary forearm injury and
- 2) Septic non-union.

The initial treatment of the fracture which evolved into non-union consisted of open reduction and internal

fixation with plate and screws, intramedullary rods, external fixation or cast immobilization.

The X-ray parameters used were:

- 1) New regenerate bone formation;
2. Bridging of the fracture seen at three cortices;

3) Obliteration of the fractures line or cortical continuity.

Non-union evolved in the radius in 5 patients, in the ulna in 6 patients, and non-union of both radius and ulna evolved in 15 patients (**Table 1**).

Non-union characteristics is given in **Table 2**.

Table 1

Fracture and treatment	
Initial fracture	
Radius	05
Ulna	06
Radius and ulna	15
Initial treatment	
Plate and screw fixation	10
Intramedullary rod	05
External fixation	02
Cast immobilization	09

Table 2

Non-union characteristics		
Type of non-union	Atrophic gap non-union	Hypertrophic non-union
Radius	4	1
Ulna	5	1
Radius & Ulna	13	2

RESULTS

No per-operative complications occurred. There was no early or late infection. All the non-unions healed. Average time of healing of non-union was 7 months,

ranging from 5-12 months.

Patients resumed ADLs (activity of daily living) 12 days after surgery with the Ilizarov apparatus.



Fig. 1 **a** 6-year old atrophic non-union of both radius and ulna (left side); **b** distraction with two rings for release of soft tissue contractures; **c** clinical appearance of the patient with the Ilizarov fixator on the left forearm; **d** distraction osteogenesis by the Ilizarov technique; **e** regular follow-up of the patient; **f** clinical appearance of the patient after 9 months with good hand function; **g** final radiograph of both radius and ulna with full consolidation after 9 months

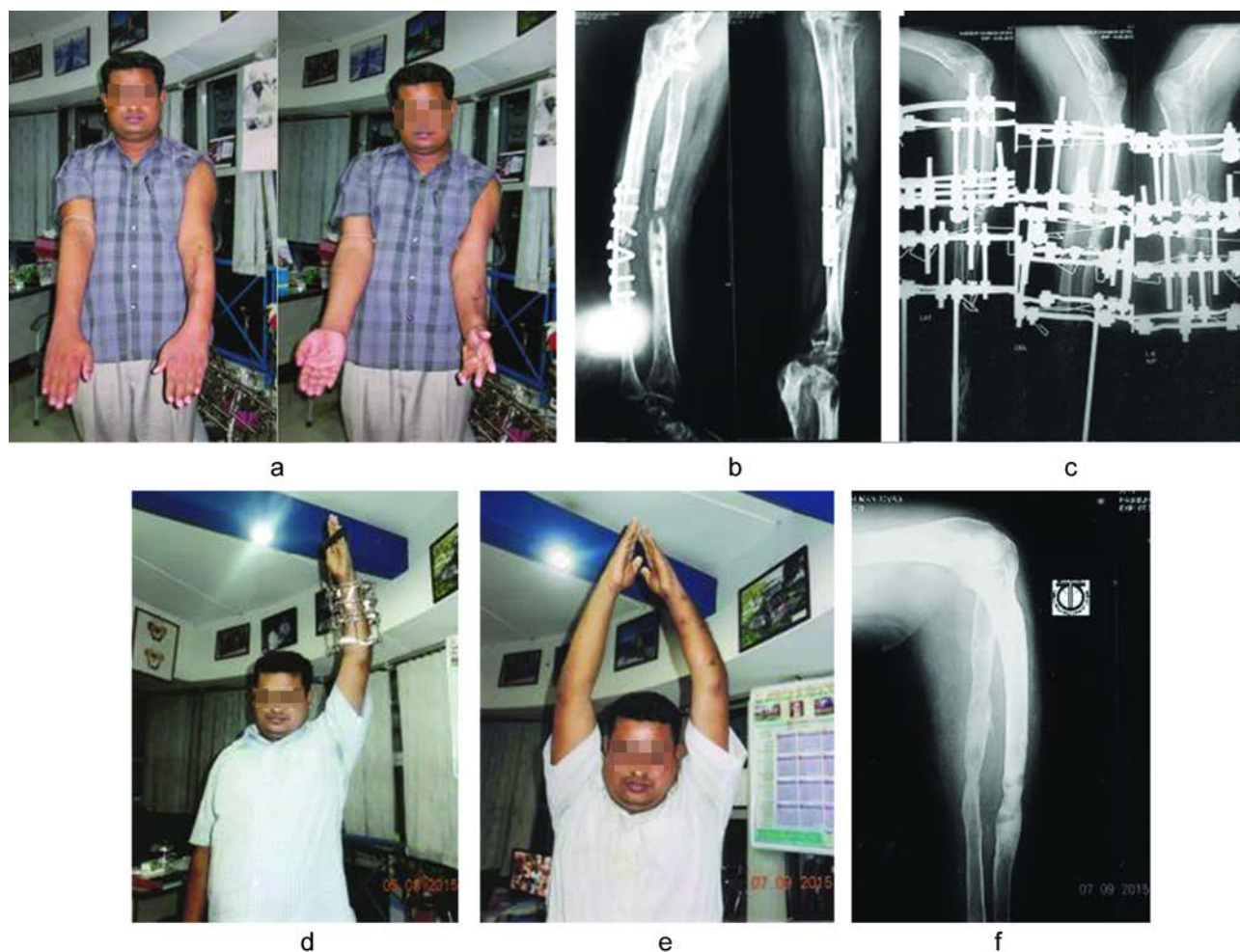


Fig. 2 a Deformed left forearm before surgery; b non-union of the left ulna with implant failure, atrophic gap non-union, left radius; c during treatment with the Ilizarov apparatus; d the Ilizarov apparatus on the left forearm; e full function with straight left forearm; f - final radiograph after 7 months, excellent union

DISCUSSION

Non-union of forearm bones is difficult to treat. The Ilizarov fixation technique for forearm bone non-union has shown to be secure to achieve new regenerate bone in the big gap non-union of the radius and ulna by distraction osteogenesis. In atrophic non-union, our goal must be the restoration of a good biological environment. Han et al. [8] and Jupiter [9] reported high success rates using vascularised bone grafts which require longer surgical time and specialized equipment. But the

Ilizarov compression-distraction technique [10] requires a demanding post-operative care.

High success rate was achieved in forearm alignment and function with the Ilizarov technique. Atrophic non-unions of the forearm bones with the gaps of 5 cm and more are difficult to treat without the Ilizarov technique. We found the excellent rate of gap healing and no rate of infection in our series with the use of distraction osteogenesis.

REFERENCES

1. Bari M.M. A color atlas of limb lengthening, surgical reconstruction and deformity correction by Ilizarov technique. 2013, pp. 127-134.
2. Kloen P., Buijze G.A., Ring D. Management of forearm nonunions: current concepts. *Strategies Trauma Limb Reconstr.*, 2012, vol. 7, no. 1, pp. 1-11. doi: 10.1007/s11751-011-0125-0
3. Richard M.J., Ruch D.S., Aldridge J.M. 3rd. Malunions and nonunions of the forearm. *Hand Clin.*, 2007, vol. 23, no. 2, pp. 235-243. doi: 10.1016/j.hcl.2007.02.005
4. Giannoudis P.V., Einhorn T.A., Marsh D. Fracture healing: the diamond concept. *Injury*, 2007, vol. 38, suppl. 4, pp. S3-S6.
5. Khan S.N., Cammisa F.P. Jr, Sandhu H.S., Diwan A.D., Girardi F.P., Lane J.M. The biology of bone grafting. *J. Am. Acad. Orthop. Surg.*, 2005, vol. 13, no. 1, pp. 77-86.
6. Stevenson S. Enhancement of fracture healing with autogenous and allogeneic bone grafts. *Clin. Orthop. Relat. Res.*, 1998, no. 355 Suppl., pp. S239-246.
7. Faldini C., Miscione M.T., Aciri F., Chehrassan M., Bonomo M., Giannini S. Use of homologous bone graft in the treatment of

- aseptic forearm nonunion. *Musculoskelet. Surg.*, 2011, vol. 95, no. 1, pp. 31-35. doi: 10.1007/s12306-011-0117-8
8. Han C.S., Wood M.B., Bishop A.T., Cooney W.P. 3rd. Vascularized bone transfer. *J. Bone Joint Surg. Am.*, 1992, vol. 74, no. 10, pp. 1441-1449.
 9. Jupiter J.B. Complex non-union of the humeral diaphysis. Treatment with a medial approach, an anterior plate, and a vascularized fibular graft. *J. Bone Joint Surg. Am.*, 1990, vol. 72, no. 5, pp. 701-707.
 10. Ilizarov G.A., Kaplunov A.G., Degtiarev V.E., Lediaev V.I. Treatment of pseudarthroses and ununited fractures, complicated by purulent infection, by the method of compression-distraction osteosynthesis. *Ortop. Travmatol. Protez.*, 1972, vol. 33, no. 11, pp. 10-14. (In Russian)

Received: 21.10.2016

Information about the authors:

1. Mofakhkharul Bari, M.D., Ph.D., Professor, Chief Consultant, Bari-Ilizarov Orthopaedic Centre; Visiting and Honored Professor, Russian Ilizarov Scientific Centre, Kurgan; e-mail: bari.ilizarov31@gmail.com
2. Shahidul Islam, M.D., Professor; FCPS, Bari-Ilizarov Orthopaedic Centre
3. Nazmul Huda Shetu, M.D., M.S. (Ortho), Consultant, Bari-Ilizarov Orthopaedic Centre
4. Mahfuzer Rahman, M.D., D. Ortho- Consultant, Bari-Ilizarov Orthopaedic Centre