

## **Роль кольцевого фиксатора Илизарова в лечении многооскольчатых надмыщелковых и межмыщелковых переломов дистального отдела бедра**

**S.V. Yadkikar<sup>1</sup>, V.S. Yadkikar<sup>2</sup>, Somnath Das<sup>3</sup>**

<sup>1</sup>Ортопедическое отделение сельского медицинского колледжа, Лони PIMS(DU), Махараштра, Индия

<sup>2</sup>Ортопедическое отделение, Мемориальный госпиталь Raynolds, Вашим, Махараштра, Индия

<sup>3</sup>Федеральное государственное бюджетное учреждение

«Российский научный центр «Восстановительная травматология и ортопедия» имени академика Г.А. Илизарова»,

Министерства здравоохранения Российской Федерации, г. Курган

## **Role of the Ilizarov ring fixator in management of severely comminuted supracondylar & intercondylar fractures of the distal femur**

**S.V. Yadkikar<sup>1</sup>, V.S. Yadkikar<sup>2</sup>, Somnath Das<sup>3</sup>**

<sup>1</sup>Department of Orthopaedics Rural Medical Collage, Loni PIMS(DU), Maharashtra, India

<sup>2</sup>Department of Orthopaedics, Raynolds Memorial Hospital, Washim, Maharashtra, India

<sup>3</sup>FSBI Russian Ilizarov Scientific Center "Restorative Traumatology and Orthopaedics" of the RF Ministry of Health, Kurgan

**Введение.** Часто причиной надмыщелковых и межмыщелковых переломов дистального отдела бедренной кости является высокоэнергетическая травма. Лечение многооскольчатых переломов является проблематичным. Повреждение покровных мягких тканей, потеря костного вещества, наличие многооскольчатости и увеличение межмыщелкового пространства затрудняют выбор имплантата. Применение односторонних наружных и гибридных фиксаторов может приводить к тугоподвижности суставов, а замещать костные дефекты ими представляет трудности. Кольцевой аппарат Илизарова применяется для лечения многооскольчатых переломов и травм, в том числе и при дефиците покровных тканей. Он обеспечивает эффективное возмещение потери костного вещества и восстановление длины и опороспособности конечности и раннюю мобилизацию пациента. **Цель.** Проанализировать роль кольцевого фиксатора Илизарова в лечении многооскольчатых надмыщелковых и межмыщелковых переломов дистального отдела бедренной кости. **Материалы и методы.** В общей сложности за период с декабря 2013 года по март 2016 года было пролечено 13 (все пациенты мужского пола) последовательных пациентов с многооскольчатыми надмыщелковыми и межмыщелковыми переломами дистального отдела бедренной кости. В одном случае был перелом типа A3, ещё в одном – типа C1, пять случаев – C2 и шесть – типа C3 по классификации AO/ASIF. В случае наличия открытых переломов использовалась классификация Густило-Андерсона (Gustilo-Anderson). В четырёх случаях при переломах типа C3 потребовалась ограниченная открытая репозиция. **Результаты.** У всех пациентов проведён контроль через один год. Среднее время консолидации перелома составило 20 недель. Часто имело место осложнение – инфицирование путей проведения спиц (n = 7). У пациентов с переломами типа C3 сгибание в коленном суставе было более ограниченным (n = 5). Разница в длине конечностей, составлявшая более 2,5 см, не отмечалась ни в одном из случаев. В данной серии не было случаев несращения или преждевременного снятия аппарата по причине инфицирования. **Заключение.** При многооскольчатых переломах дистального отдела бедра с внутрисуставным расхождением отломков кольцевой аппарат Илизарова можно рассматривать как один из надёжных вариантов лечения.

**Ключевые слова:** кольцевой фиксатор Илизарова, компрессия, лигаментотаксис, дистракция, бедренная кость, надмыщелковый перелом

**Introduction** Supracondylar and intercondylar fractures of the distal femur are often attributed to high energy trauma. Treatment of such severely comminuted fractures is challenging. Poor overlying soft tissue, bone loss in the presence of severe comminution and intercondylar extension makes implant selection difficult. Unilateral knee spanning external fixators and hybrid fixators can lead to knee joint stiffness and the issue of bone loss is difficult to deal with them. Ilizarov ring fixator is reserved for severely comminuted fractures and injuries with poor overlying soft tissue. It can effectively manage the bone loss and facilitates limb length restoration, promotes early weight bearing and mobilization. **Aim** To study the role of the Ilizarov ring fixator in management of severely comminuted supracondylar and intercondylar fractures of the distal femur. **Material and Method** A total of 13 (all male patients) consecutive patients with severely comminuted supracondylar and intercondylar fractures of the distal femur were treated from December 2013 to March 2016. There was one case with A3 type, one with C1, five cases with C2 and six cases with C3 type as per AO/ASIF Classification. Gustilo-Anderson classification was used for compound fractures. Four cases of C3 type required limited open reduction. **Results** All patients completed one-year follow-up. Average fracture union time was 20 weeks. Pin tract infection (n = 7) was a frequent complication. Patients with C3 Type of fracture had more restriction in knee flexion (n = 5). No case had limb length discrepancy more than 2.5 cm. No case of nonunion or premature fixator removal due to infection was noted in the series. **Conclusion** Ilizarov ring fixator can be considered as one of the reliable treatment options for severely comminuted distal femoral fractures with intra-articular extension.

**Keywords:** Ilizarov ring fixator, ligamentotaxis compression, distraction, femur, supracondylar fracture

### INTRODUCTION

Supracondylar and intercondylar fractures of the distal femur are often attributed to high energy trauma. Strong deforming muscle forces, proximity to the knee joint and vicinity of vascular structures are some of the important factors to consider during their management [1].

Complications like angular deformity, malunion and

joint incongruity make the conservative line of management obsolete [1].

Varieties of treatment modalities are available like a dynamic condylar screw, fixed angle blade plate, locking plates and even intramedullary nails [2]. Satisfactory outcomes can be obtained with these fixation devices,

especially in extra-articular type A or Type B supracondylar fractures as per AO/ASIF classification [2, 3]. But treatment of severely comminuted supracondylar fractures with intercondylar extension is challenging [1, 2, 4, 5]. In the presence of severe comminution and intercondylar extension, fracture reduction and fixation with conventional methods becomes difficult [1]. Intramedullary devices are also not suitable in such situation [2].

Factors like poor overlying soft tissues as in compound fractures, bone loss in the presence of severe comminution and intercondylar extension makes even implant selection difficult [2].

Conventional unilateral knee spanning external fixators

and hybrid fixators can be useful in such situations [3, 6] but they may cause problems of knee joint stiffness and the issue of bone loss is difficult to deal with them [2, 3].

This stimulated us to perform a study on the role of the Ilizarov ring fixator in the management of severely comminuted supracondylar and intercondylar fractures of the distal femur (C2 and C3 Type according to AO/ASIF Classification).

The Ilizarov ring fixator is reserved for severe comminuted fractures and also injuries with poor overlying soft tissues [1, 2, 3, 5, 7] but it can also effectively manage the issues like bone loss, facilitates limb length restoration, early weight bearing and mobilization [2, 3, 5, 7].

## MATERIAL AND METHODS

In this prospective study, a total of 13 cases of severely comminuted and intercondylar distal femur fractures were treated with the Ilizarov ring fixator at the department of orthopaedics of the Rural medical college in Loni, India, from December 2013 to March 2016.

Approval from the institutional ethical committee was obtained for this study. Prior to it, a valid informed consent was taken from all patients.

All were male patients in the 4th – 6th decade of life (average age was 50 years). Eleven patients had injury due to road traffic accidents while two had assaults. Four patients had associated long bone injuries which were

treated with open reduction and internal fixation during the same operation.

Fractures were classified by AO/ASIF classification (Table 1) and Gustilo-Anderson classification was used for compound fractures (Fig. 1, 2). Patients with associated vascular injuries IIC Type of Gustilo-Anderson classification and patients not willing to participate in the study were excluded.

All the patients had a preoperative skeletal traction. Average duration between the admission and operation was 8 days. Among 13 patients, two had bone loss of 4 cm and 2 cm respectively.

Table 1

| Number | Age in Years | Fracture type by AO/ASIF CLASSIFICATION | Compound by Gustilo-Anderson classification | Reduction (Open/ Closed) | Fracture union time (weeks) | Pin-tract infection | Limb length discrepancy (cm) | Range of knee motion in degrees |
|--------|--------------|---|---|--------------------------|-----------------------------|---------------------|------------------------------|---------------------------------|
| 1      | 42           | C2                                      | Grade II                                    | Closed                   | 20                          | Nil                 | 1 cm                         | 0 – 90                          |
| 2      | 55           | C2                                      | Grade I                                     | Closed                   | 16                          | +                   | Nil                          | 0 – 90                          |
| 3      | 47           | C3                                      | Grade IIIB                                  | Open                     | 20                          | +                   | 1cm                          | 0 – 35                          |
| 4      | 60           | C3                                      | Grade II                                    | Closed                   | 16                          | Nil                 | 1.5 cm                       | 0 – 20                          |
| 5      | 49           | C2                                      | Grade I                                     | Closed                   | 16                          | +                   | Nil                          | 0 – 100                         |
| 6      | 47           | A3                                      | Grade I                                     | Closed                   | 12                          | Nil                 | Nil                          | 0 – 110                         |
| 7      | 51           | C3                                      | Grade II                                    | Closed                   | 16                          | Nil                 | Nil                          | 0 – 20                          |
| 8      | 47           | C3                                      | Grade IIIA                                  | Open                     | 20                          | +                   | 2.5 cm                       | 0 – 40                          |
| 9      | 53           | C2                                      | Grade II                                    | Closed                   | 20                          | +                   | Nil                          | 0 – 75                          |
| 10     | 50           | C1                                      | Grade I                                     | Closed                   | 12                          | Nil                 | Nil                          | 0 – 100                         |
| 11     | 63           | C3                                      | Grade IIIB                                  | Open                     | 20                          | Nil                 | 2 cm                         | 0 – 45                          |
| 12     | 59           | C3                                      | Grade IIIB                                  | Open                     | 20                          | +                   | 1cm                          | 0 – 30                          |
| 13     | 60           | C2                                      | Grade II                                    | Closed                   | 16                          | +                   | Nil                          | 0 – 100                         |

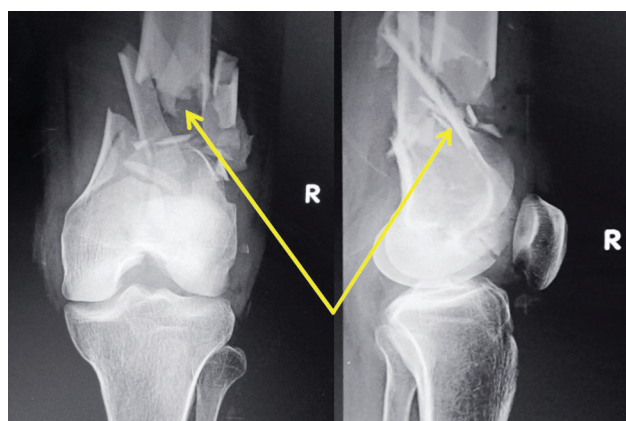


Fig. 1. Severely comminuted C 3 type supracondylar fracture. Arrows pointing towards comminution and intra- articular extension in the lateral view

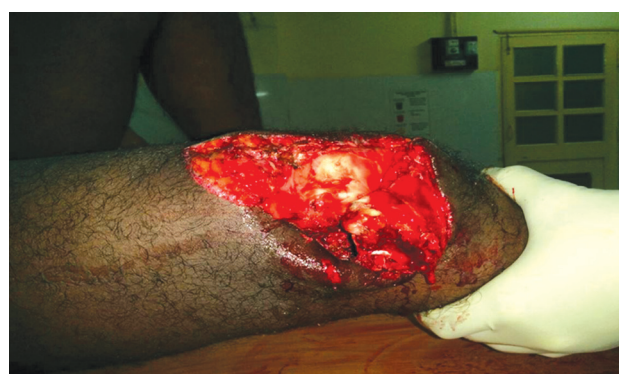

Fig. 2. Compound distal femur fracture

All the patients were operated in the supine position on a traction table. Closed reduction was obtained by traction and counter traction under image intensifier control. The knee joint was kept in moderate flexion. Closed reduction was obtained in 9 cases while 4 cases with C3 Type required limited open reduction. In compound fractures, the wound was thoroughly irrigated with normal saline.

**Assembly of construct** Intercondylar compression was obtained with the help of two divergent olive wires that passed through the condyles from the anterolateral to posteromedial and from the anteromedial to posterolateral directions parallel to the knee joint (Fig. 3). A half-ring was attached to the wires and tensioning of the wires was done with a dynamometer. Distal to proximal progressive construct was made. In the proximal fragment near the trochanter, Schanz screws were used and they were connected to the Italian arch. Distal and proximal parts of the construct were connected with threaded rods. Depending upon the stability of the construct, additional rings were mounted near the fracture site.

In two patients with bone loss, corticotomy just below the lesser trochanter was performed with the help of low energy hammering and osteoclasts (Fig. 4, 5). Pin tract dressing was applied. Intravenous antibiotics were given for 5 days postoperatively and changed later to oral

antibiotics. Active quadriceps strengthening and knee bending exercises were started as per pain tolerance from postoperative day 3 or 4. Compression distraction cycles at the fracture site and also distraction at the corticotomy site at the rate of 1 mm/day divided by four times a day were initiated by a treating surgeon/nurse ) on post-op day 7 as per fracture geometry.

Approximate time required for distraction at the corticotomy site was 45 days. Non-weight bearing mobilization was initiated after 4 to 5 days postoperatively (Fig. 6, a). It was continued for the next 4 weeks. Fracture healing was assessed clinically by absence of pain at the fracture site and radiographically by demonstration of the callus in both AP and lateral views (Fig. 6, b). As per evidence of callus formation, partial and full weight-bearing was permitted. Frame was removed only after complete fracture union (Fig. 7, a, b).

Average hospital stay was two months. The patients were reviewed at monthly intervals till frame was removed and then every three months till one year. Knee brace was used in 3 patients with severe comminution. Range of knee motion was measured with a goniometer. Leg-length discrepancy was assessed by measuring the distance between the anterior iliac spine and medial malleolus on both sides.




Fig. 3. Immediate post operative X-ray showing axial alignment following ligamentotaxis

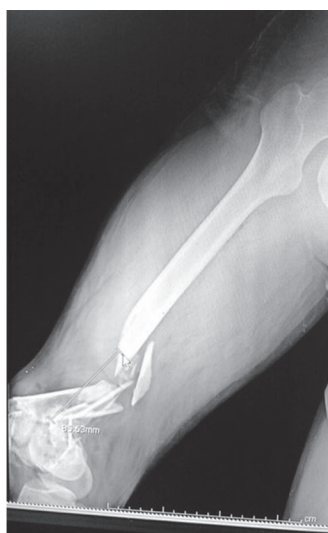

Fig. 4. Intercondylar distal fracture with bone loss

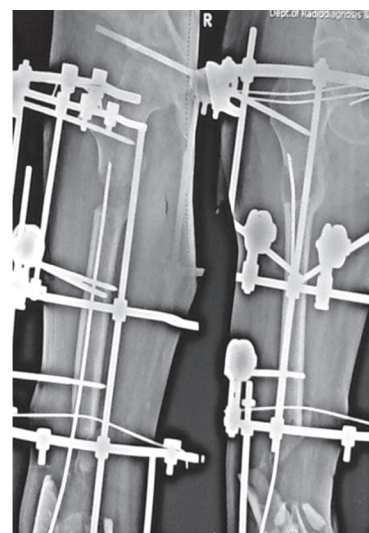
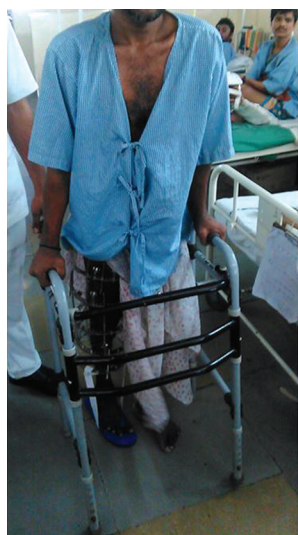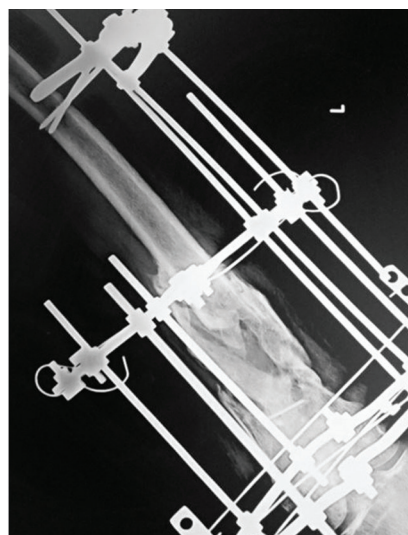


Fig. 5. Corticotomy and bone transport in a comminuted intercondylar fracture with bone loss



a



b

Fig. 6.: a – early mobilization; b – callus formation across fracture site



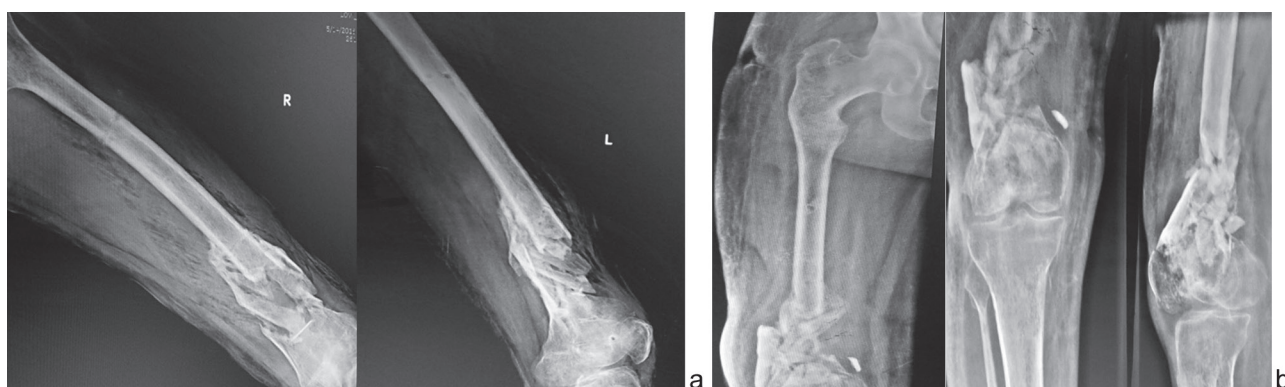

Fig. 7.: a – fracture union; b – fracture as well as corticotomy union

## RESULTS

All patients were followed up for one year (Table 1). Average time for fracture union was 20 weeks. Fracture united in all the cases. Restricted knee flexion was frequently encountered in patients, especially with C3 Type of fractures (Fig. 8). In all the patients, knee extension was complete. Pin tract infection was noted in 7 patients. It was treated with daily pin tract dressing using betadine solution and intravenous antibiotics for 7 days. None of the patients required premature

fixator removal due to infection. There were no cases of limb length discrepancy of more than 2.5 cm.

Bone grafting was performed in none of the cases. One case showed valgus of the distal femur of 6 degrees while two cases showed varus deformity of 8 degrees. No patient required a secondary procedure due to loosening of the frame with loss of reduction. There were no cases with nonunion in our series.

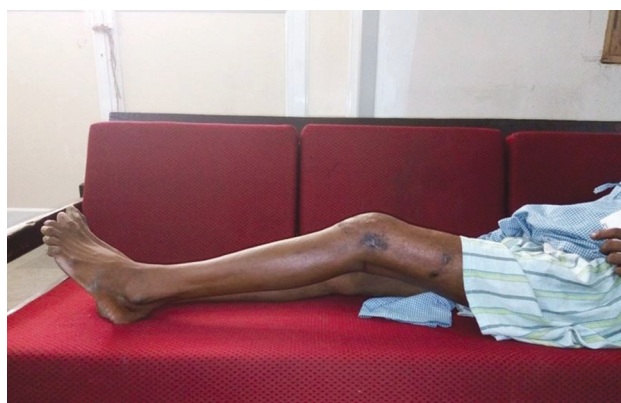

Fig. 8. Limited knee flexion

## DISCUSSION

Treatment of severely comminuted distal femur fractures, especially C2 and C3 fracture type by AO/ASIF classification, is challenging [2]. Extensive comminution along with intercondylar extension makes fracture fixation with conventional implants like plates or intramedullary nails difficult [2].

Fixation with plates or dynamic condylar screws requires considerable amount of soft tissue exposure and periosteal stripping which can further devitalize bone fragments [2, 4, 8]. Though it can be done by a minimally invasive technique with intramedullary nails, intercondylar area comminution makes insertion of a nail difficult [2, 9, 10]. Poor soft tissue condition along with fracture comminution makes treatment even more complicated [1, 5].

Monolateral external fixators can be applied for such fractures but a knee spanning fixator needs to be applied sometimes in the presence of comminution and intercondylar extension that can lead to knee stiffness [2, 6].

Ilizarov ring fixator application for such fractures has certain advantages like a minimally invasive technique, versatile frame assembly which can be tailored as per fracture geometry [1, 2, 3] and facilitates bone transport,

deformity correction, and correction of malalignment during the entire process of fracture healing. It provides better mechanical stability by three dimensional construct [2, 3, 5, 7]. Diverging olive wires provide stable fixation and compression of condyles [1, 2, 3]. Tensioned wires of small diameter for a better stability can be used even in the presence of osteoporotic bone [1]. In our series, we have used Schanz screws in the proximal femoral construct that are better tolerated by patients and are comparatively easy for fixation [2, 3, 12]. In the majority of cases (n=9), closed reduction with the help of ligamentotaxis was obtained but in several cases of C3 type a limited open reduction was required due to severe comminution.

Frequent complications noted in our series were pin-tract infection and limited knee flexion.

Pin tract infection was controlled by local dressing and antibiotics. Limited knee flexion was seen more in C3 type fractures [2, 3, 5, 11]. It is postulated that wires and pins in the femur pass through the quadriceps muscle, thereby acting as a checkrein to the movement of the knee while the fixator is applied [2, 3, 7]. To reduce this complication, we operated all the cases with moderate flexion of the knee

which can stretch quadriceps mechanism [3]. The severity of soft tissue injury will also add to knee stiffness as well as the fracture pattern rather than technique [5].

Thus, from our observations and results it can be suggested that the Ilizarov ring fixator is versatile and can be tailored as per fracture geometry. Minimally invasive definitive treatment for severely comminuted

distal femur fractures can provide early weight bearing, deformity correction by means of compression or distraction that is possible throughout treatment period. However, it is technically demanding, has a long learning curve and also has some disadvantages like a lengthy treatment span, heavy frame, and possible pin-tract infection [2, 3, 5].

## CONCLUSION

The Ilizarov ring fixator can be considered as one of the reliable treatment options in severely comminuted distal femoral fractures with intra-articular extension.

## ЛИТЕРАТУРА

1. Fractures of the distal femur / P.J. O'Brien, R.N. Meek, P.A. Blackhut, H.M. Broekhuyse. In: Rockwood and Green's Fractures in Adults / R.W. Bucholz, J.D. Heckman Eds. 5th ed. Philadelphia: Lippincott Williams and Wilkins, 2001. Chapter 42. P. 1732-1773.
2. Ilizarov external fixation for severely comminuted supracondylar and intercondylar fractures of the distal femur / M. Arazi, R. Memik, T.C. Ogün, M. Yel // *J. Bone Joint Surg. Br.* 2001. Vol. 83, no. 5. P. 663-667.
3. Treatment of Gustilo grade III B supracondylar fractures of the femur with Ilizarov external fixation / P. Kumar, G.K. Singh, M. Singh, S. Bajraacharya S. // *Acta Orthop. Belg.* 2006. Vol. 72, no. 3. P. 332-336.
4. Siliski J.M., Mahring M., Hofer H.P. Supracondylar-intercondylar fractures of the femur. Treatment by internal fixation // *J. Bone Joint Surg. Am.* 1989. Vol. 71, no. 1. P. 95-104.
5. Canale S.T., Beaty J.H. Fractures of lower extremity. In: Campbell's Operative Orthopaedics / T.Canale Ed. 11th ed. Elsevier, 2008. Chapter 51. P. 3146-3161.
6. Ali F., Saleh M. Treatment of isolated complex distal femoral fractures by external fixation // *Injury*. 2000. Vol. 31, no. 3. P. 139-146.
7. Ilizarov G.A. Transosseous Osteosynthesis. Theoretical and Clinical Aspects of the Regeneration and Growth of Tissue / S.A. Green Ed. Berlin: Springer-Verlag, 1992.
8. Shewring D.J., Meggitt B.F. Fractures of the distal femur treated with the AO dynamic condylar screw // *J. Bone Joint Surg. Br.* 1992. Vol. 74, no. 1. P. 122-125.
9. Manual of internal fixation: Techniques recommended by the AO-ASIF Group / M.E. Müller, M. Allgöwer, R. Schneider, H. Willenegger. 3rd Ed. Berlin: Springer, 1991. 752 pp.
10. The retrograde intramedullary nail: prospective experience in patients older than sixty-five years / H.M. Janzing, B. Stockman, G. van Damme, P. Rommens, P.L. Broos // *J. Orthop. Trauma*. 1998. Vol. 12, no. 5. P. 330-333.
11. Supracondylar fractures of the femur treated by external fixation / J.L. Marsh, H. Jansen, H.K. Yoong, E.M. Found Jr. // *J. Orthop Trauma*. 1997. Vol. 11, no. 6. P. 405-410.
12. High-velocity gunshot wounds of the tibial plafond managed with Ilizarov external fixation: a report of 13 cases / C. Yildiz, A.S. Ateşalp, B. Demiralp, E. Gür // *J. Orthop. Trauma*. 2003. Vol. 17, no. 6. P. 421-429.
13. Chapman M.W., Finkemeier C.G. Treatment of supracondylar nonunions of the femur with plate fixation and bone graft // *J. Bone Joint Surg. Am.* 1999. Vol. 81, no. 9. P. 1217-1228.
14. Hutson J.J. Jr. Reconstruction of distal intercondylar femoral fractures with limited internal fixation and Ilizarov tensioned-wire external fixation // *Tech. Orthop.* 1996. Vol. 11, no. 2. P. 182-195.
15. Fractures of the femoral shaft with management of external fixation to experience some problems / A. Kutlu, M. Yel, M. Mutlu, M.I.S. Kapicioglu. In: External fixation / M. Çakmak, M. Kocaoğlu eds. Istanbul: Damla Matbaasi, 1995. P. 166-169.
16. Acute shortening: modular treatment modality for severe combined bone and soft tissue loss of the extremities // A. Lerner, L. Fodor, M. Soudry, I.J. Peled, D. Herer, Y. Ullmann // *J. Trauma*. 2004. Vol. 57, no. 3. P. 603-608.
17. Catagni M.A., Mendlick R.M. Femoral fractures // *Tech. Orthop.* 1996. Vol. 11. P. 160-173.
18. Aktuğlu K., Öncü H., Kara S. Ilizarov treatment of supracondylar and intercondylar fractures of the distal femur. In: External fixation / M. Çakmak, M. Kocaoğlu eds. Istanbul: Damla Matbaasi, 1995. P. 175-182.
19. Ilizarov principles of deformity correction / B. Spiegelberg, T. Parratt, S.K. Dheerendra, W.S. Khan, R. Jennings, D.R. Marsh // *Ann. R. Coll. Surg. Engl.* 2010. Vol. 92, no. 2. P. 101-105. doi: 10.1308/003588410X12518836439326.
20. Outcomes of Ilizarov ring fixation in recalcitrant infected tibial non-unions – a prospective study / T.R. Madhusudhan, B. Ramesh, K. Manjunath, H.M. Shah, D.C. Sundaresh, N. Krishnappa // *J. Trauma Manag. Outcomes*. 2008. Vol. 2, no. 1. P. 6. doi: 10.1186/1752-2897-2-6.

## REFERENCES

1. O'Brien P.J., Meek R.N., Blackhut P.A., Broekhuyse H.M. Fractures of the distal femur. In: Bucholz R.W., Heckman J.D. eds. Rockwood and Green's Fractures in Adults. 5th Ed. Philadelphia, Lippincott Williams and Wilkins, 2001, chapter 42, pp. 1732-1773.
2. Arazi M., Memik R., Ogün T.C., Yel M. Ilizarov external fixation for severely comminuted supracondylar and intercondylar fractures of the distal femur. *J. Bone Joint Surg. Br.*, 2001, vol. 83, no. 5, pp. 663-667.
3. Kumar P., Singh G.K., Singh M., Bajraacharya S. Treatment of Gustilo grade III B supracondylar fractures of the femur with Ilizarov external fixation. *Acta Orthop. Belg.*, 2006, vol. 72, no. 3, pp. 332-336.
4. Siliski J.M., Mahring M., Hofer H.P. Supracondylar-intercondylar fractures of the distal femur. Treatment by internal fixation. *J. Bone Joint Surg. Am.*, 1989, vol. 71, no. 1, pp. 95-104.
5. Canale S.T., Beaty J.H. Fractures of lower extremity. In: Canale T. ed. Campbell's Operative Orthopaedics. 11th Ed. Elsevier, 2008, chapter 51, pp. 3146-3161.
6. Ali F., Saleh M. Treatment of isolated complex distal femoral fractures by external fixation. *Injury*, 2000, vol. 31, no. 3, pp. 139-146.
7. Ilizarov G.A. Transosseous Osteosynthesis. Theoretical and Clinical Aspects of the Regeneration and Growth of Tissue. Green S.A. ed. Berlin, Springer-Verlag, 1992.
8. Shewring D.J., Meggitt B.F. Fractures of the distal femur treated with the AO dynamic condylar screw. *J. Bone Joint Surg. Br.*, 1992, vol. 74, no. 1, pp. 122-125.
9. Müller M.E., Allgöwer M., Schneider R., Willenegger H. Manual of internal fixation: Techniques recommended by the AO-ASIF Group. 3rd Ed. Berlin, Springer, 1991, 752 p.
10. Janzing H.M., Stockman B., Van Damme G., Rommens P., Broos P.L. The retrograde intramedullary nail: prospective experience in patients older than sixty-five years. *J. Orthop. Trauma*, 1998, vol. 12, no. 5, pp. 330-333.
11. Marsh J.L., Jansen H., Yoong H.K., Found E.M. Jr. Supracondylar fractures of the femur treated by external fixation. *J. Orthop Trauma*, 1997, vol. 11, no. 6, pp. 405-410.

12. Yildiz C., Ateşalp A.S., Demiralp B., Gür E. High-velocity gunshot wounds of the tibial plafond managed with Ilizarov external fixation: a report of 13 cases. *J. Orthop. Trauma*, 2003, vol. 17, no. 6, pp. 421-429.
13. Chapman M.W., Finkemeier C.G. Treatment of supracondylar nonunions of the femur with plate fixation and bone graft. *J. Bone Joint Surg. Am.*, 1999, vol. 81, no. 9, pp. 1217-1228.
14. Hutson J.J. Jr. Reconstruction of distal intercondylar femoral fractures with limited internal fixation and Ilizarov tensioned-wire external fixation. *Tech. Orthop.*, 1996, vol. 11, no. 2, pp. 182-195.
15. Kutlu A., Yel M., Mutlu M., Kapıcıoğlu M.I.S. Fractures of the femoral shaft with management of external fixation to experience some problems. In: Çakmak M., Kocaoglu M. eds. External fixation. Istanbul, Damla Matbaasi, 1995, pp. 166-169.
16. Lerner A., Fodor L., Soudry M., Peled I.J., Herer D., Ullmann Y. Acute shortening: modular treatment modality for severe combined bone and soft tissue loss of the extremities. *J. Trauma*, 2004, vol. 57, no. 3, pp. 603-608.
17. Catagni M.A., Mendlick R.M. Femoral fractures. *Tech. Orthop.*, 1996, vol. 11, pp. 160-173.
18. Aktuğlu K., Öncag H., Kara S. Ilizarov treatment of supracondylar and intercondylar fractures of the distal femur. In: Çakmak M., Kocaoglu M. eds. External fixation. Istanbul, Damla Matbaasi, 1995, pp. 175-182.
19. Spiegelberg B., Parratt T., Dheerendra S.K., Khan W.S., Jennings R., Marsh D.R. Ilizarov principles of deformity correction. *Ann. R. Coll. Surg. Engl.*, 2010, vol. 92, no. 2, pp. 101-105. doi: 10.1308/003588410X12518836439326.
20. Madhusudhan T.R., Ramesh B., Manjunath K., Shah H.M., Sundaresh D.C., Krishnappa N. Outcomes of Ilizarov ring fixation in recalcitrant infected tibial non-unions – a prospective study. *J. Trauma Manag. Outcomes*, 2008, vol. 2, no. 1, pp. 6. doi: 10.1186/1752-2897-2-6.

Рукопись поступила 18.11.2016

#### Сведения об авторах:

1. Yadkikar S.V., M.D., MS(Ortho) – Сельский медицинский колледж, Лони PIMS(DU), Махараштра, Индия, ортопедическое отделение, доцент; e-mail: yadkikarpushkar@yahoo.co.in
2. Yadkikar V.S., M.D., MS(Ortho) – Мемориальный госпиталь Raynolds, Вашим, Махараштра, Индия, ортопедическое отделение, главный хирург-ортопед
3. Das Somnath, M.D. of Orthopaedics – ФГБУ «РНЦ «ВТО» им. акад. Г.А. Илизарова» Минздрава России, г. Курган, аспирант

#### Information about the authors:

1. S.V. Yadkikar, M.D., MS(Ortho), Associate Professor, RISC RTO, Kurgan, Fellowship, Loni PIMS(DU), Maharashtra, India, Department of Orthopaedics Rural Medical College; e-mail: yadkikarpushkar@yahoo.co.in
2. V.S. Yadkikar, M.D., MS (Ortho), Chief Orthopedic surgeon, MS (Gen.Surg.), Raynolds Memorial Hospital, Washim, Maharashtra, India, Department of Orthopaedics
3. Somnath Das, M.D. of Orthopaedics, James Long clinic, Kolkata, India, Russian Ilizarov Scientific Centre of Restorative Orthopaedics & Traumatology, Kurgan, Russia, Clinical research fellow