

Management of congenital radial club hand by gradual correction**Gamal A. Hosny, Abdel-Salam A. Ahmed**

Benha University, Faculty of Medicine, Egypt

Introduction Severe congenital radial club hand is aesthetically unacceptable. This paper represents our experience in treating early and late diagnosed cases using gradual distraction by Ilizarov external fixator. **Methods** We treated 34 cases of congenital radial club hand with an age ranged from 1 to 15 years. There were 20 girls and eight bilateral cases. Three had been treated on both sides. So, we have treated 37 limbs. Nine cases had been operated before. Centralization alone was done in 12 cases and followed by lengthening in eight cases. Ulnar lengthening and gradual correction of wrist deformities were done for the rest of cases. The patients were followed clinically and radiographically with the following parameters: hand forearm angle, range of motion, daily functional activities, extent of lengthening achieved, and cosmetic improvement. **Results** The follow up ranged from 1 to 10 years. The magnitude of lengthening achieved ranged from 5 to 11 cm. The average healing index was 52.02 days/cm with cosmetic appearance satisfaction in all cases. Complications included; pin tract infection in 24 cases, flexion contractures of the elbow and fingers in 26 cases [which mostly disappeared during follow up], and spontaneous ulnocarpal fusion in 2 cases. Two cases suffered fracture in the regenerate zone. **Conclusions** The use of the Ilizarov method with gradual distraction of bone and soft tissues in treatment of radial club hand was effective in forearm lengthening with functional and cosmetic improvement.

Keywords Distraction osteogenesis, Ilizarov, radial club hand, ulnar lengthening

INTRODUCTION

Radial longitudinal deficiency (RLD) is a congenital deformity of the upper extremity with a spectrum of hand and forearm anomalies ranging from mild radial hypoplasia to complete absence of the radius. Severe RDL is clinically characterized by shortening of the forearm and radial deviation of the wrist, and has also been referred to as “the radial club hand” [1, 2]. It is a relatively rare deformity with an incidence of 0.5 per 10,000 live births [3]. Most cases of RDL are sporadic and commonly associated with a number of congenital syndromes [4]. The pathogenesis is unknown. It has been postulated that injury to the apical ectodermal

ridge during upper limb development is the cause [5].

LG Bayne and MS Klug [6] classified RLD into four types. Types III and IV are the most common forms with different surgical procedures described for their management. Centralization procedures with soft tissue release have become the most commonly performed methods [2, 7-9]. In severe cases, centralization can be difficult due to tight soft tissue contractures [6, 8, 9].

This paper represents our experience in treating early and late diagnosed cases using gradual distraction by Ilizarov external fixator.

MATERIALS AND METHODS

This retrospective study was approved by the Institutional Ethical Committee, and was conducted in accordance with the ethical standards laid down in the Declaration of Helsinki. Inclusion criteria for this study were children and adolescents with Bayne’s type III and Bayne’s type IV deformity treated by Ilizarov fixator. Exclusion criteria included patients with severe associated anomalies that were incompatible with a long life. The study included 34 patients with RLD between March 2001 and December 2014. The mean age of patients was 5.54 years (SD 3.45; range: 1-15). There were 20 girls and 14 boys. Eight patients had bilateral deformity. Three had been treated on both sides. So, we have treated 37 radial club hands. Nine cases had been operated before. Sixteen hands were Bayne’s type III and 21 were Bayne’s type IV. Combined radial deviation and wrist flexion

deformity was present in all cases with variable thumb abnormalities: hypoplastic in eight hands, rudimentary in ten hands, and absent in the rest of cases. Eleven patients showed associated anomalies; spina bifida (four cases), torticollis (two cases), ear lobe anomaly (three cases), and palate anomaly (two cases). All wrists were stiff, with only minimal range of motion (ROM) from a resting position of slight flexion and with limited forearm rotation. The hand-forearm angle was measured as described by PR Manske et al. [8] between the longitudinal axis of third metacarpal bone and longitudinal axis of the ulna.

Before surgery, we discussed the procedure in details with the patients and their families. Informed consent was obtained from the parents or guardians of all patients included in the study.

Operative technique:

In 12 young patients [less than three years] we performed centralization through an ulnar approach and the Ilizarov frame was applied for gradual post-operative deformity correction. We used a constrained two-ring frame. A forearm ring was fixed to the ulna by two 1.5 mm K-wires and a 3 mm half pin. The hand ring was fixed by two 1 mm K-wires; one inserted into the second and third metacarpals and one passed into the fourth and fifth metacarpals at the diaphyseal level. The distractor was applied in the radial-palmar side with two hinges on the opposite side. Distraction for deformity correction was started after 3 days at a rate of 1 mm per day. Centralization was done in 12 cases followed by lengthening in eight out of these 12 cases (Fig. 1).

Ulnar lengthening and gradual correction of wrist deformities were done for the rest of cases (25 cases) (Fig. 2). We used one or one and half rings for the proximal ulna fixed by two K-wires and one half pin, one ring for the ulna distal to the planned osteotomy site fixed by two K-wires and one half pin, and half ring fixed to the metacarpals by two K-wires. The osteotomy was then performed in the ulna through 1 cm incision using an osteotome and multiple drilling by 1.6 mm K-wire. After 10 days, lengthening started at a rate of 1 mm per day. Then the rate was modified according to radiographic findings of callus formation and the degree of developing stiffness in the elbow or the fingers joints or as needed to accommodate pain.

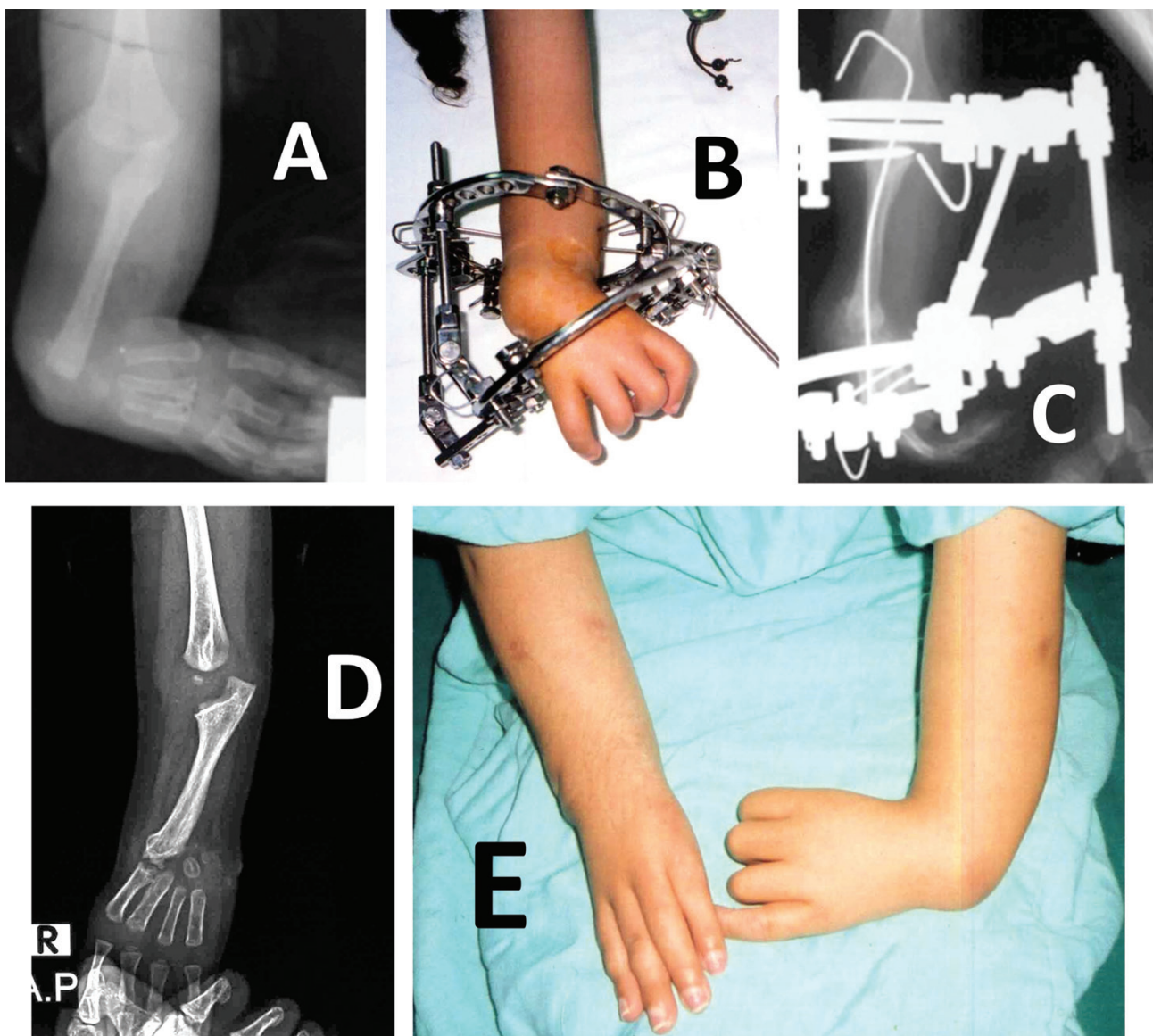


Fig. 1 A case treated by centralization: Preoperative radiograph (A). Clinical photograph during correction (B). Radiograph during correction by Ilizarov frame (C). Follow-up radiograph at one year (D). Clinical follow-up of the right side at one year (E)

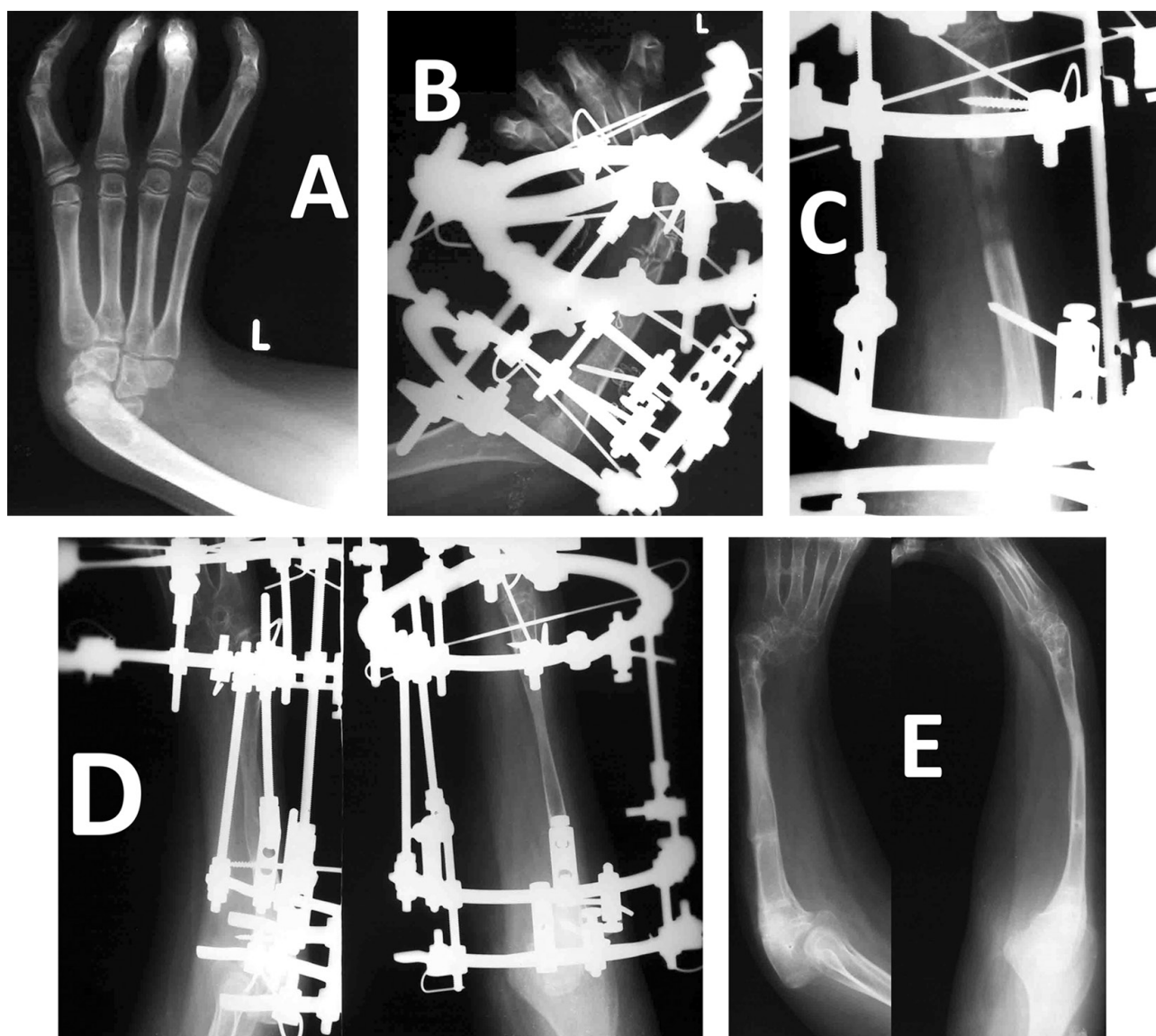


Fig. 2 Radiographs of a case treated by ulnar lengthening and gradual correction of wrist deformity: Preoperative radiograph (A). Immediate postoperative radiograph (B). During distraction with regenerate formation (C). After consolidation (D). At one year of follow-up (E)

Patients were followed up weekly during lengthening and monthly during consolidation. All patients were given instructions for pin care and elbow and fingers motion. Distraction was continued until a satisfactory length and deformity correction had been achieved. The fixator was removed after sound consolidation, and a long arm cast was applied for 4 weeks. The patients were followed up clinically and radiographically with assessment of hand

forearm angle, ROM, daily functional activities, extent of lengthening achieved and cosmetic improvement.

Statistical analysis was done to compare the mean preoperative and postoperative lengths and deformities using Paired-Samples T Test. Level of significance set at $p < 0.05$. The descriptive analysis and statistical analysis were performed with IBM SPSS Statistics for Windows, Version 22.0 (IBM Corp., Armonk, NY, USA).

RESULTS

Patients were followed for a mean of 3.76 years (SD 2.21; range 1-10). The external fixation period ranged from 74 to 90 days in four cases satisfied by centralization alone and averaged 335.45 days (SD 53.90; range 240-520) in the rest of cases. The mean healing index was 52.02 days per cm (SD 2.75; range 47.27-59). Preoperatively the mean length of the ulna

was 8.11 cm (SD 1.63; range 5.5-12) and at the final follow up it was 14.58 cm (SD 2.42; range 10.5-21) with statistically significant improvement from the mean preoperative length ($p < 0.001$). The mean gain in the length of the ulna was therefore 6.47 cm (SD 1.16; range 5-11) which was 81.40 % of the original length (SD 12.84; range 41.67-110).

Preoperatively, the mean deformity of radial deviation was 75.51° (SD 20.92; range $45-120^\circ$) in the anteroposterior and the average flexion deformity was 42.11° (SD 6.02; range $35-60^\circ$) in the lateral view. At final follow-up, the mean residual radial deviation deformity was 5.83° (SD 2.62; range 2-10) and 2.33° of flexion deformity (SD 2.02; range 0-5) in the younger age group with statistically significant improvement from the mean preoperative deformity ($p < 0.001$). In the older patients, we partially corrected the wrist deformity during progressive ulnar lengthening. At the last follow-up evaluation, all patients reported that they were satisfied with their deformity correction and additional forearm length.

DISCUSSION

Variable treatment methods have been described for the treatment of RLD including centralization[9], radialization [10], and microvascular metatarsophalangeal joint transfer in younger children [7], and distraction osteogenesis of the ulna in the older child, particularly with recurrent or neglected cases [11, 12]. While one-stage procedures are privileged, they may be complicated by the need for ulnar shortening or carpal resections, sacrifice of the distal ulnar growth plate, neurovascular stretch injury, severe hand swelling, and wound complications [13]. In addition, inadequate soft tissue release may result in distal ulnar bowing, intercarpal fusions, carpometacarpal angulations, and recurrence of deformity [6].

Deformity correction by percutaneous techniques is becoming more popular. Unilateral external fixators have been used for pre-centralization soft tissue stretching, but they cannot correct both the radial deviation and flexion deformities [14]. The Ilizarov device is advantageous over unilateral external fixators with a more comprehensive and physiologically sound distraction in addition to ulnar lengthening. For patients with unilateral RLD, the deformity is very noticeable. In bilateral cases, short forearms may impair performance of daily living activities. Both problems can be managed by the Ilizarov fixator [12, 15].

The current series is a large series compared to most. Careful preoperative evaluation was important to assess the presence and severity of any associated anomalies. That was present in 11 of our patients without a syndromic pattern.

In the younger age group of our patients, the deformity was corrected with only average residual of about 5.8° at the final follow up. Recurrence is the most common source of failure after centralization. PR Manske et al. [8] reported on 21 radial club hands with hand-forearm angle at an average of 58° preoperatively and 26° at an average 34 month postoperatively. HK Watson et al. [9] monitored

Complications included pin tract infection in 24 cases, flexion contractures of the elbow and fingers in 26 cases [which mostly disappeared with physiotherapy during follow up], and spontaneous ulnocarpal fusion in two cases. Most of the pin tract infections were managed with oral antibiotics. One patient needed change of an infected loose wire. Two cases suffered fracture in the regenerate zone. One was in the dynamization period after loosening the nuts. This was treated by tightening the nuts again till consolidation was complete. The other occurred two weeks after frame and cast removal. Above elbow cast was applied for 6 weeks. There were no cases of neurovascular compromise, wound infection, recurrence of deformity, osteomyelitis, or nonunion. There was no need for bone grafting.

12 centralizations for 10 years and reported a recurrence to an average of 30° .

Older children, especially those over 12 years, have already developed functional patterns of use of the radially deviated hand. So, an older, well-adjusted patient is not a candidate for centralization [6]. Therefore, in older children of our series, we partially corrected the wrist deformity during progressive ulnar lengthening. The magnitude of lengthening achieved in our cases ranged from 5 to 11 cm which was up to 110 % of the original length. That mean distraction distance far exceeded results of several studies. H Kawabata et al. [11] achieved a length gain of 4.7 cm or 51 % in their series of 7 patients. BM Peterson et al. [16] reported an average lengthening of 4.4 cm. MA Pickford and LR Scheker [12] reported a mean lengthening of 46 % of original ulna length. Our results were comparable to those reported by S Farr et al. [17] with a mean ulna lengthening of 7.0 cm. The lengthening achieved in the current study was a one stage lengthening and no one showed nonunion or needed bone grafting or internal fixation. Several authors recommended that lengthening be performed in two stages [11, 16, 18]. S. Farr et al. [17] performed internal rodding of the ulna in one case and preventive plating in five in a series of six patients. MA Pickford and LR Scheker [12] reported delayed union in four of eight cases. BM Peterson et al. [16] reported delayed union in three of 13 lengthenings treated by internal fixation and bone grafting. S Farr et al. [17] reported one case of nonunion in a patient with a total lengthening of 8.2 cm which was addressed by interposition of a fibula graft and plate fixation.

The mean healing index in this study was 52.02 days per cm. MA Pickford and LR Scheker [12] reported a mean lengthening index of 3.8 weeks (26.6 days) per cm. This reflects the longer external fixation period of our patients.

Shorter external fixation period looks attractive but the reduced time allowed for consolidation may be responsible for the higher callus fracture and delayed union rate in their study (four of eight cases). BM Peterson et al. [16] reported lengthening index of 8.6 weeks per cm. T Takagi et al. [19] reported a mean healing index of 176.8 day/cm.

S Farr et al. [17] reported a fracture of the ulna after removal of the Ilizarov device in one patient, which was treated by plate fixation. In the current study, two

cases had fracture in the regenerate zone. None of them reported a clear history of trauma. The first was during the dynamization period. This might be due to overestimation of the regenerate by soft follow-up radiographs. Good quality radiographs and visible four cortices in the regenerate are essential before frame removal.

Because of the rare nature of this deformity, most reports in literature are limited to small case series [11, 12, 16, 17]. So, this is a large series compared to most.

CONCLUSIONS

The use of the Ilizarov method in gradual correction of RDL and forearm lengthening was effective in functional and cosmetic improvement and without skeletal resection or endangering the neurovascular structures. Ulnar

lengthening up to 110 % of the original length could be achieved without the need for bone grafting. However, familiarity with the technical details and patient compliance are essential.

REFERENCES

1. James M.A., Green H.D., McCarroll Jr. H.R., Manske P.R. The association of radial deficiency with thumb hypoplasia. *J. Bone Joint Surg. Am.* 2004. Vol. 86-A, N 10. pp. 2196-2205
2. Maschke S.D., Seitz W., Lawton J. Radial longitudinal deficiency. *J. Am. Acad. Orthop. Surg.* 2007. Vol. 15, N 1. pp. 41-52
3. Ekblom A.G., Laurell T., Arner M. Epidemiology of congenital upper limb anomalies in 562 children born in 1997 to 2007: a total population study from Stockholm, Sweden. *J. Hand Surg. Am.* 2010. Vol. 35, N 11. pp. 1742-1754
4. Goldfarb C.A., Wall L., Manske P.R. Radial longitudinal deficiency: the incidence of associated medical and musculoskeletal conditions. *J. Hand Surg. Am.* 2006. Vol. 31, N 7. pp. 1176-1182
5. Bae D.S., Waters P.M. The upper limb. In: *Lovell and Winter's Pediatric Orthopaedics*. 7th. Weinstein S.L., Flynn J.M. (Eds). Lippincott Williams & Wilkins, Philadelphia, 2014. pp. 895-982
6. Bayne L.G., Klug M.S. Long-term review of the surgical treatment of radial deficiencies. *J. Hand Surg. Am.* 1987. Vol. 12, N 2. pp. 169-179
7. Vilkkii S.K. Vascularized metatarsophalangeal joint transfer for radial hypoplasia. *Semin. Plast. Surg.* 2008. Vol. 22, N 3. pp. 195-212
8. Manske P.R., McCarroll H.R. Jr, Swanson K. Centralization of the radial club hand: an ulnar surgical approach. *J. Hand Surg. Am.* 1981. Vol. 6, N 5. pp. 423-433
9. Watson H.K., Beebe R.D., Cruz N.I. A centralization procedure for radial clubhand. *J. Hand Surg. Am.* 1984. Vol. 9, N 4. pp. 541-547
10. Buck-Gramcko D. Radialization as a new treatment for radial club hand. *J. Hand Surg. Am.* 1985. Vol. 10, N 6, Pt. 2. pp. 964-968
11. Kawabata H., Shibata T., Masatomi T., Yasui N. Residual deformity in congenital radial club hands after previous centralisation of the wrist. Ulnar lengthening and correction by the Ilizarov method. *J. Bone Joint Surg. Br.* 1998. Vol. 80, N 5. pp. 762-765
12. Pickford M.A., Schecker L.R. Distraction lengthening of the ulna in radial club hand using the Ilizarov technique. *J. Hand Surg. Br.* 1998. Vol. 23, N 2. pp. 186-191
13. Sabharwal S., Finuoli A.L., Ghobadi F. Pre-centralization soft tissue distraction for Bayne type IV congenital radial deficiency in children. *J. Pediatr. Orthop.* 2005. Vol. 25, N 3. pp. 377-381
14. Kanojia R.K., Sharma N., Kapoor S.K. Preliminary soft tissue distraction using external fixator in radial club hand. *J. Hand Surg. Eur.* 2008. Vol. 33, N 5. pp. 622-627. doi: 10.1177/1753193408093809
15. Cattaneo R., Catagni M.A., Guerreschi F. Treatment of radial agenesis with the Ilizarov method. *Rev. Chir. Orthop. Reparatrice Appar. Mot.* 2001. Vol. 87, N 5. pp. 443-450
16. Peterson B.M., McCarroll H.R. Jr, James M.A. Distraction lengthening of the ulna in children with radial longitudinal deficiency. *J. Hand Surg. Am.* 2007. Vol. 32, N 9. pp. 1402-1407
17. Radiographic early to midterm results of distraction osteogenesis in radial longitudinal deficiency. *J. Hand Surg. Am.* 2012. Vol. 37, N 11. pp. 2313-2319. doi: 10.1016/j.jhsa.2012.08.029
18. Abzug J.M., Kozin S.H. Radial longitudinal deficiency. *J. Hand Surg. Am.* 2014. Vol. 39, N 6. pp. 1180-1182. doi: 10.1016/j.jhsa.2014.03.036
19. Takagi T., Seki A., Mochida J., Takayama S. Bone lengthening of the radius with temporary external fixation of the wrist for mild radial club hand. *J. Plast. Reconstr. Aesthet. Surg.* 2014. Vol. 67, N 12. pp. 1688-1693. doi: 10.1016/j.bjps.2014.08.048

Received: 31.08.2016

Information about the authors:

1. Gamal Ahmed Hosny, M.D., Benha University, Faculty of Medicine, Egypt, Head of Orthopaedic Surgery Department, Professor of Orthopaedic Surgery; e-mail: gamalahosny@yahoo.com
2. Abdel-Salam Abdelaleem Ahmed, M.D., Benha University, Faculty of Medicine, Egypt, Assistant Professor of Orthopaedic Surgery; e-mail: salam_ilizarov@yahoo.com, ABDELSALAM.YOUSSEF@fmed.bu.edu.eg